

Visceral leishmaniasis in pregnancy: a case series and a systematic review of the literature

Pasquale Pagliano^{1*}, Novella Carannante², Marco Rossi¹, Marina Gramiccia³, Luigi Gradoni³,
Francesco Saverio Faella¹ and Giovanni Battista Gaeta²

¹I Division of Infectious Diseases, D. Cotugno Hospital, Naples; ²Department of Infectious Diseases, II University of Naples, Naples; ³Department of Parasitology, Istituto Superiore di Sanità, Rome, Italy

Received 14 July 2004; accepted 15 November 2004

Objectives: Visceral leishmaniasis (VL) is endemic in tropical and sub-tropical areas. Only anecdotal cases of VL in pregnancy are reported in the literature, although the disease is life-threatening for both mothers and infants. Here we report a small series of pregnant women with VL observed in the Neapolitan area over a 7 year period and carry out a systematic review of the literature on this topic.

Methods: Consecutive cases of VL in HIV-negative female patients between 1996 and 2002 were evaluated. Pregnant women who fulfilled criteria for VL diagnosis were included and diagnostic, clinical and therapeutic features were considered. The outcome for both the pregnant woman and the fetus was evaluated over a 24 month period of post-therapy follow-up. A systematic search of English language literature through the MEDLINE database and Cochrane Library with the search strings 'leishmaniasis AND pregnancy' and 'leishmaniasis AND visceral AND congenital' integrated with a manual search completed our study.

Results: Five consecutive pregnant women were diagnosed as having VL. Fever and hepatosplenomegaly were the main presenting symptoms. All received liposomal amphotericin B without any toxicity to either the mothers or newborns. No treatment failure or congenital VL case was observed. The systemic review of the literature revealed 17 cases of VL during pregnancy. Untreated VL resulted in consequences on the fetus or congenital VL.

Conclusions: The efficacy and safety of amphotericin B formulations for mother and fetus are supported by the cumulative analysis of our data and literature data.

Keywords: therapy, antimonials, amphotericin B

Introduction

Visceral leishmaniasis (VL) is endemic in tropical and sub-tropical areas including the Mediterranean basin. The vast majority of cases are recorded in the Indian subcontinent, East Africa and northeastern Brazil, where *Leishmania donovani* and *Leishmania infantum* (syn.: *Leishmania chagasi*) are the main aetiological agents. In the Mediterranean where the incidence is estimated to be at least 1000 cases per year and dogs provide the reservoir for *Leishmania infantum*, the disease affects patients of all ages, but children and the immunodepressed are more frequently involved because of a relative inability to contain the infection.^{1–3}

Pentavalent antimony (PA) therapy has been extensively used in both immunocompetent and immunodepressed patients with leishmaniasis. However, the increasing rate of resistance reported in areas with high prevalence of VL, the incidence of serious adverse events, and concerns about long-term toxicity and teratogenicity have limited the use of antimonial drugs and promoted alternative treatments, such as amphotericin B (AmB). Because renal toxicity of the conventional drug formulation limits daily dosage, lipid formulations of AmB, i.e. liposomal (l-AmB), colloidal dispersion and lipid complex, have been developed and found effective and safe, since they result in higher concentrations in liver and spleen tissue macrophages and in low concentrations in the kidney. High cost makes lipid

*Corresponding author. Tel: +39-081-5908292; Fax: +39-081-5908300; E-mail: ppagliano@libero.it

formulations of AmB unaffordable in developing countries, where VL is endemic.⁴⁻⁷

Normal pregnancy is accompanied by changes in immune response, mainly a decrease in cellular immunity and a proportional increase in humoral immunity, which may in part account for the successful growth and delivery of the fetus hemi-allograft. These physiological events result in an increase in the risk for infections sustained by some parasitic agents whose immunity is based on a T-helper 1 predominant response.^{8,9} Although on the basis of this immunological evidence the risk of VL during pregnancy may be higher, no specific epidemiological data support the hypothesis.

VL is a severe disease and warrants treatment. During pregnancy the disease is life-threatening for the mother and may have consequences for the fetus. Some concerns may arise about the safety of the drugs used for VL on the fetus, since all registrative trials of new drugs for VL exclude pregnant women.^{5,6}

Here we report a small series of VL in pregnant women treated with l-AmB. We examined the safety and efficacy of the drug in both pregnant women and newborns, and carried out a systematic review of the literature on this topic.

Materials and methods

We reviewed all cases of VL in HIV-negative female patients admitted to the I Division of Infectious Diseases at the 'D. Cotugno' Hospital, Naples and to the Department of Infectious Diseases of the II University of Naples (main regional referring centres for adult VL), between January 1996 and December 2002.

Inclusion criteria for the study were: (i) pregnancy diagnosed by β -human chorionic gonadotropin measurement; (ii) positive test for antibodies against *Leishmania* determined by the immunofluorescent antibody test (IFAT); (iii) demonstration of *Leishmania* from Giemsa-stained smears of bone marrow or spleen aspirates, or from cultures carried out with this material. The exclusion criterion was co-infection with HIV.

At admission, we collected demographic data (age, sex and residence), previous or underlying disease(s), period of gestation, history of previous pregnancy, presenting signs and symptoms (fever, hepatic and spleen size), non-specific laboratory data such as full blood count, gammaglobulin concentration, erythrocyte sedimentation rate (ESR), blood urea and creatinine, and specific laboratory data such as antileishmanial antibody titre determined by IFAT. Cultures were attempted from bone marrow aspirates, and zymodeme analysis of *Leishmania* strains obtained was carried out. Positive cases were treated with l-AmB at a dosage that had proved highly effective in adult Italian patients in a multicentre trial (3 mg/kg at days 1-5 and 3 mg/kg at day 10).¹⁰ Post-treatment follow-up included clinical examination, blood cell count, ESR and IFAT titre at the end of therapy and monthly in both women and newborns.

Pregnant women were considered cured when symptoms disappeared, laboratory data improved and no clinical relapse was observed during the subsequent 24 months.

At delivery, newborns' weight and vitality (defined by Apgar score at 1 min after delivery) were evaluated. Newborns were considered disease free if no clinical signs of VL developed during the follow-up and IFAT titre decreased until it became undetectable, during the 24 months of follow-up.

To better evaluate the effect of the treatment of VL during pregnancy and the impact of the treatment on both mother and fetus, we carried out a systematic search of the English language literature

using the MEDLINE database with the search strings 'leishmaniasis AND pregnancy' and 'leishmaniasis AND visceral AND congenital' for reports published from January 1968 to March 2004 and by checking of the Cochrane Library and manual research of the references from available review reports about VL and pregnancy and treatment. Furthermore, using the same search strings, we checked the 'Google' and 'Altavista' search engines in order to find other unpublished papers (i.e. post-doctoral theses). Cases were eligible for review when diagnosis in the mother was based on serological and/or parasitological evidence and data about newborn conditions were available. The initially selected articles were independently (P.P. and G.B.G.) reviewed if deemed relevant and data were extracted. Manual research on the papers regarding series of VL completed our literature search. In each reported case, we recorded, when available, age, parity, period of gestation at the beginning of the disease, therapy and outcome. The retrieved cases were pooled together with our own cases and the impact of the treatment on both the mother and newborn was evaluated by a two-tailed χ^2 test.

Results

Five consecutive pregnant women were diagnosed as having VL during the study period. All cases were from the Neapolitan area; none had underlying diseases. The onset of clinical symptoms varied between 1 and 12 weeks (median 9 weeks) before diagnosis. Fever was reported in all cases, weight loss in three and abdominal pain in two. Four women were in their first pregnancy, and one in her second.

The main demographic, clinical and laboratory findings at admission are reported in Table 1.

Anti-*Leishmania* antibodies were always present, IFAT titres ranging between 1/640 and 1/10 240 (median 1/1256). In all cases, amastigotes were observed from Giemsa-stained smears of bone marrow aspirate. Cultures from such specimens were attempted in three patients and found to be positive in two. Zymodeme analysis was carried out in two cases. One strain was characterized as zymodeme Montpellier (MON) 1, i.e. the commonest *L. infantum* zymodeme in the Mediterranean area; and one as MON 72, an *L. infantum* zymodeme exclusively found in our area.¹¹ On treatment, all patients had a rapid improvement of clinical and laboratory parameters. Defervescence occurred between 48 and 96 h after first drug administration. Spleen size was reduced to 2.6 ± 1.5 cm below left costal margin by day 10 and to impalpable by day 40 in all cases. Changes in spleen size,

Table 1. Main demographic, clinical and laboratory findings at admission

Parameter	Mean \pm S.D.
Age (years)	30.2 \pm 9
Time from onset of symptoms (weeks)	7.4 \pm 4
Period of pregnancy (weeks)	11.8 \pm 2
Spleen size (cm)	6.0 \pm 2
Haemoglobin (g/dL)	8.3 \pm 1
White blood cells ($\times 10^3$ cells/mm ³)	2.6 \pm 0.5
Platelets ($\times 10^3$ cells/mm ³)	111.2 \pm 26
ESR (mm/h)	78.2 \pm 43

ESR, erythrocyte sedimentation rate.

Leishmaniasis and pregnancy

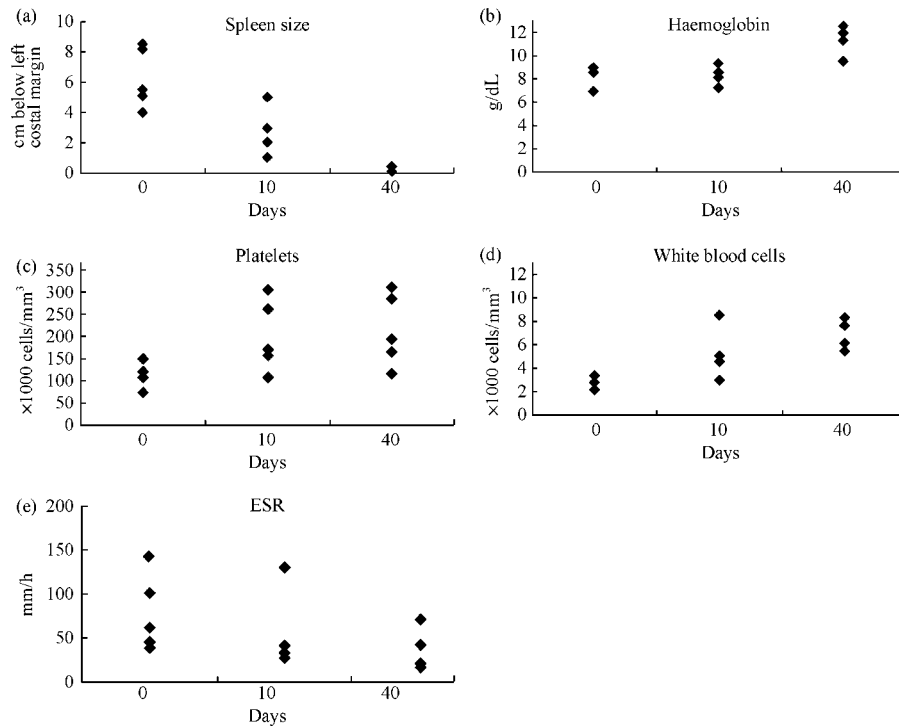


Figure 1. Changes in spleen size, haemoglobin concentration, white blood cell and platelet counts and ESR during the treatment and the follow-up.

white blood cell and platelet counts, haemoglobin concentration and ESR are reported in Figure 1. No case had a rise in blood urea and creatinine levels during treatment. Anti-*Leishmania* antibodies declined until they became undetectable by month 6. No relapse was observed.

All patients conducted a full term pregnancy. Five healthy newborns were delivered; Apgar score ranged between 7 and 9, and weight ranged between 3200 and 3700 g. At delivery, four newborns had detectable levels of anti-*Leishmania* antibodies; all became negative within 6 months, indicating passive transmission of antibodies. Newborns from infected mothers did not show any abnormality during the 24 month post-delivery follow-up period.

A total of 65 published studies were extracted from MEDLINE; none was extracted by checking of the Cochrane Library and of 'Altavista' and 'Google' search engines on the basis of our inclusion criteria. Of these studies, 54 were excluded from the analysis for the following reasons: 16 were not in the English language, 18 did not report original cases (general comments or report of previously described cases), seven reported experimental studies of treatment or non-human transmission, seven reported cases affected with cutaneous leishmaniasis, and six described cases in infants without clinical evidence of VL in the mother. Therefore, 11 studies (total number of patients 17) remained, and eight described a single case.

Table 2 summarizes the studies analysed.¹²⁻²² Four untreated cases are reported; of them, two resulted in newborn VL, one in *in utero* death at the fifth month of pregnancy, and one in a small for date newborn. Treatment was reported in 13 cases and resulted in a favourable outcome in both mothers and newborns in all but three. 'No treatment' or 'relapse' resulted in a significantly higher risk of fetal complication or death ($\chi^2=4.6$; $P<0.05$). By adding our five cases treated with l-AmB, a total of 22 VL cases were available and the association between no

treatment and fetal complication or death became stronger ($\chi^2=7.0$; $P<0.01$). Of note, no information about type and length of therapy received by the mothers was reported in two cases that lead to VL in newborns despite treatment of mothers, whereas relapse after a 4 week course of Pentostam was reported in one case with intrauterine growth retardation and subsequent congenital VL. No toxicity was reported in eight cases receiving AmB (two received l-AmB) and in three cases receiving PA.

Discussion

We report five cases of VL in pregnant women from the Neapolitan area. As 60 000 women become pregnant each year in our area,²³ we may assume that during the study period the yearly incidence of VL in pregnancy was 1/83 000, quite similar to the incidence of VL in the whole adult population (1/100 000). Although depression of cell-mediated immune mechanisms during pregnancy favours infections sustained by other intracellular agents, our data indicate that an increase in the risk of VL does not occur in pregnant women.^{8,9}

Four of our patients were in their first pregnancy and only one was in her second pregnancy. Higher susceptibility to parasitic infections, such as malaria, was reported in primiparous women with respect to multiparous women because of depression of natural killer cell cytotoxicity, mediated by high cortisol levels, which may play a role in the inability to develop or maintain the immunity. Such immune mechanisms may also explain the higher prevalence of women in their first pregnancy observed in our cases.²⁴

Time from the onset of symptoms and diagnosis was higher than 7 weeks in four of our cases and in most cases reported by other authors. Frequently, a long lasting history of fever, weight loss and unexplained low haemoglobin levels preceded diagnosis

Table 2. Studies in English literature reporting cases of VL during pregnancy

Reference	Cases (country)	<i>Leishmania</i> culture	Age	Parity	Month of pregnancy	Outcome		
						Therapy	mother	newborn
Mittal <i>et al.</i> ¹²	1 (India)	NR	32	NR	VII	treated, drug unknown	cured	VL at 8 months
Nyakundi <i>et al.</i> ¹³	1 (Sudan)	NR	NR	VII	VI	untreated		VL at 6 months
Yadav <i>et al.</i> ¹⁴	1 (India)	<i>L. donovani</i> (Indian)	30	NR	VI	untreated		VL at 11 months
Elamin & Omer ¹⁵	1 (Sudan)	NR	NR	NR	VII	treated, drug unknown	cured	VL at 6 weeks
Eltoum <i>et al.</i> ¹⁶	2 (Sudan)	NR	30	NR	IV	PA	relapse	small for date and VL at 7 months abortion
Thakur <i>et al.</i> ¹⁷	5 (India)	NR	30	NR	V	untreated		
			23	NR	IV	AmB	cured	healthy
			24	NR	V	AmB	cured	healthy
			19	NR	III	AmB	cured	healthy
			22	NR	II	AmB	cured	healthy
Gradoni <i>et al.</i> ¹⁸	2 (Italy)	<i>L. infantum</i>	29	II	V	AmB	cured	healthy
			20	NR	V	l-AmB	cured	healthy
			24	NR	IX	PA	cured	healthy
Utili <i>et al.</i> ¹⁹	1 (Italy)	NR	39	NR	V	PA	cured	healthy
Kumar <i>et al.</i> ²⁰	1 (India)	NR	28	I	III	untreated		small for date
Dereure <i>et al.</i> ²¹	1 (France)	<i>L. infantum</i>	33	NR	V	l-AmB	cured	healthy
Caldas <i>et al.</i> ²²	1 (Brazil)	NR	17	NR	II	AmB	cured	healthy

NR, not reported; AmB, amphotericin B deoxycholate; l-AmB, liposomal amphotericin B; PA, pentavalent antimonial salt.

of VL in pregnancy, particularly in the developed world. These findings warrant a careful evaluation of the diagnosis of leishmaniasis in pregnant women with fever of unknown origin and haematological abnormalities, if a history of exposure in endemic areas is reported.²⁵

Because untreated VL during pregnancy may lead to severe disease, characterized by high grade anaemia, spontaneous loss of the fetus, and congenital VL because of transplacental transfer of parasites, the treatment cannot be deferred, even in apparently low symptomatic cases. This indication to therapy of VL during pregnancy is supported by the association between ‘no treatment’ and abortion or disease in the newborns that emerged from the literature analysis (Table 2). In three of these cases, however, a higher virulence of the agent (Indian or African strains of *L. donovani*) cannot be ruled out.^{13,14,16,20}

Antimonials are not considered safe during pregnancy, mainly because of concerns derived from experimental studies.²⁶ Data derived from three cases treated with pentavalent antimonial suggest a careful evaluation of antimonial use during pregnancy. Favourable outcome was reported in two pregnant women observed in our area, whereas the delivering of a small for date newborn who developed fatal VL at the 7th month of age was observed in a case from Sudan who had post-treatment relapse.^{16,18,19}

AmB has already been investigated in pregnant women with mycotic infections and is considered safe and effective.²⁷ A favourable outcome was reported in six pregnant women with VL treated with AmB deoxycholate, but the renal toxicity and the long duration of the treatment may raise some concerns.^{17,22} In all, l-AmB was found safe and effective in seven cases. In our series of five cases, haemoglobin levels had a more rapid improvement than generally observed in patients treated with AmB deoxycholate, no toxicity was observed in either mothers or newborns and the cure rate was 100% with a short course

treatment. Of note, no study reporting l-AmB use in pregnancy was analysed in approving the drug by the US Food and Drug Administration.⁵

In most of the cases described in this article, the characterization of *Leishmania* spp. was not done, so that we cannot exclude that transmission rate to fetus may differ among *Leishmania* species. Of note, fetal transmission occurred only in areas where *L. donovani* is endemic. Interestingly, we retrieved five cases from India that were treated with AmB, and all of them had a favourable outcome.

In our cases treated with l-AmB, the cost is about 4000 €/case (assuming a 5 day hospitalization period for treatment and a hospital acquisition price for l-AmB of 125 €/50 mg). Treatment with AmB deoxycholate formulation would cost about 4200 €/case (assuming a 20 day hospitalization period for treatment and a hospital acquisition price for AmB deoxycholate of 5 €/50 mg). The reduction in the hospitalization period obtained with l-AmB balances the high cost of the drug and makes the use of l-AmB cost-effective in industrialized countries.

Overall, the data reported in this paper suggest that amphotericin B-based treatments can be safely and effectively used in pregnant women with VL. l-AmB offers the additional advantage of a short-course treatment and causes a prompt improvement in clinical and laboratory parameters.

References

- Guerin, P. J., Olliaro, P., Sundar, S. *et al.* (2002). Visceral leishmaniasis: current status of control, diagnosis, and treatment, and a proposed research and development agenda. *Lancet Infectious Diseases* **2**, 494–501.
- Gradoni, L., Pizzuti, R., Scalone, A. *et al.* (1996). Recrudescence of visceral leishmaniasis unrelated to HIV infection in the Campania

Leishmaniasis and pregnancy

region of Italy. *Transactions of the Royal Society of Tropical Medicine and Hygiene* **90**, 234–5.

3. Pagliano, P., Rossi, M., Rescigno, C. *et al.* (2003). Mediterranean visceral leishmaniasis in HIV-negative adults: a retrospective analysis of 64 consecutive cases (1995–2001). *Journal of Antimicrobial Chemotherapy* **52**, 264–8.

4. Sundar, S., More, D. K., Singh, M. K. *et al.* (2000). Failure of pentavalent antimony in visceral leishmaniasis in India: report from the centre of the Indian epidemic. *Clinical Infectious Diseases* **31**, 1104–6.

5. Meyerhoff, A. (1999). U.S. Food and Drug Administration approval of AmBisome (liposomal amphotericin B) for treatment of visceral leishmaniasis. *Clinical Infectious Diseases* **28**, 42–8.

6. Murray, H. W. (2001). Clinical and experimental advances in treatment of visceral leishmaniasis. *Antimicrobial Agents and Chemotherapy* **45**, 2185–97.

7. Sundar, S., Mehta, H., Suresh, A. V. *et al.* (2004). Amphotericin B treatment for Indian visceral leishmaniasis: conventional versus lipid formulations. *Clinical Infectious Diseases* **38**, 377–83.

8. Wegman, T. G., Lin, H., Guibert, L. *et al.* (1993). Bidirectional cytokine interactions in the maternal-fetal relationship: is successful pregnancy a TH-2 phenomenon? *Immunology Today* **14**, 353–6.

9. Mellor, A. L. & Munn, D. H. (2000). Immunology at the maternal-fetal interface: lessons for T cell tolerance and suppression. *Annual Review of Immunology* **18**, 367–91.

10. Davidson, R. N., di Martino, L., Gradoni, L. *et al.* (1996). Short-course treatment of visceral leishmaniasis with liposomal amphotericin B (AmBisome). *Clinical Infectious Diseases* **22**, 938–42.

11. Gramiccia, M., Gradoni, L., di Martino, L. *et al.* (1992). Two syntopic zymodemes of *Leishmania infantum* cause human and canine visceral leishmaniasis in the Naples area, Italy. *Acta Tropica* **50**, 357–9.

12. Mittal, V., Sehgal, S., Yadav, T. P. *et al.* (1987). Congenital transmission of kala-azar. *Journal of Communicable Diseases* **19**, 184–5.

13. Nyakundi, P. M., Muigai, R., Were, J. B. *et al.* (1988). Congenital visceral leishmaniasis: case report. *Transactions of the Royal Society of Tropical Medicine and Hygiene* **82**, 564.

14. Yadav, T. P., Gupta, H., Sattaya, U. *et al.* (1989). Congenital kala-azar. *Annals of Tropical Medicine and Parasitology* **83**, 535–7.

15. Elamin, A. & Omer, M. I. (1992). Visceral leishmaniasis in a 6-week-old infant: possible congenital transmission. *Tropical Doctor* **22**, 133–5.

16. Eltoun, I. A., Zijlstra, E. E., Ali, M. S. *et al.* (1992). Congenital kala-azar and leishmaniasis in the placenta. *American Journal of Tropical Medicine and Hygiene* **46**, 57–62.

17. Thakur, C. P., Sinha, G. P., Sharma, V. *et al.* (1993). The treatment of kala-azar during pregnancy. *National Medical Journal of India* **6**, 263–5.

18. Gradoni, L., Gaeta, G. B., Pellizzer, G. *et al.* (1994). Mediterranean visceral leishmaniasis in pregnancy. *Scandinavian Journal of Infectious Diseases* **26**, 627–9.

19. Utili, R., Rambaldi, A., Tripodi, M. F. *et al.* (1995). Visceral leishmaniasis during pregnancy treated with meglumine antimoniate. *Infection* **23**, 182–3.

20. Kumar, A., Mittal, M. & Prasad, S. (2001). Treatment of leishmaniasis in pregnancy. *International Journal of Gynaecology and Obstetrics* **72**, 189–90.

21. Dereure, J., Duong Thanh, H., Lavabre-Bertrand, T. *et al.* (2003). Visceral leishmaniasis. Persistence of parasites in lymph nodes after clinical cure. *Journal of Infection* **47**, 77–81.

22. Caldas, A. J., Costa, J. M., Gama, M. E. *et al.* (2003). Visceral leishmaniasis in pregnancy: a case report. *Acta Tropica* **88**, 39–43.

23. CNEL STATS. (2001). Demografia e presenze straniere—Campania. [Online.] <http://www.cnel.it/cnelstats> (12 July 2004, date last accessed).

24. Bouyou-Akotet, M. K., Issifou, S., Meye, J. F. *et al.* (2004). Depressed natural killer cell cytotoxicity against *Plasmodium falciparum*-infected erythrocytes during first pregnancies. *Clinical Infectious Diseases* **38**, 342–7.

25. Pearson, R. D. & Sousa, A. Q. (1996). Clinical spectrum of leishmaniasis. *Clinical Infectious Diseases* **22**, 1–13.

26. Paumgarten, F. J. R. & Chahoud, I. (2001). Embryotoxicity of meglumine antimoniate in the rat. *Reproductive Toxicology* **15**, 327–31.

27. King, C. T., Rogers, P. D., Cleary, J. D. *et al.* (1998). Antifungal therapy during pregnancy. *Clinical Infectious Diseases* **27**, 1151–60.