

Visceral Leishmaniasis without Fever in a Kidney Transplant Recipient

S.	Süheyla	Apaydin ^a
R.	Rezzan	Ataman ^a
K.	Kamil	Serdengeç ^a
N.	Nükhet	Tüzüner ^b
E.	Erdal	Polat ^c
E.	Ekrem	Erek ^a
U.	Uğur	Ülkü ^a

Departments of ^aNephrology, ^bPathology and ^cMicrobiology, Cerrahpaşa Medical Faculty, Istanbul, Turkey

Dr. S. Apaydin, Department of Nephrology, Cerrahpaşa Medical Faculty, Kocamustafapaşa Caddesi, Kimyacı Apt. No. 60/4, TR-34300 Cerrahpaşa/Istanbul (Turkey)

m

margin together with dullness over Traube's space. Laboratory findings were as follows: serum urea, 33 mg/dl; serum creatinine, 1.1 mg/dl; hematocrit, 22%; leukocyte count, 2,200/mm³; platelet count, 260,000/mm³; ESR, 63 mm/h; albuminemia, 3.3 g/dl; globulinemia, 5.5 g/dl; protein electrophoresis; polyclonal gammopathy; ALT, 56 IU; AST, 54 IU; γ -GT, 57 IU; total bilirubinemia, 0.7 mg/dl; C-reactive proteinemia, 41 mg/dl; β 2-microglobulinemia, 8.2 mg/dl. Anti-HCV antibody was negative (RIBA 2). A stool test for occult blood was negative. No acid-resistant bacilli were found in the spu-

Dear Sir,

Visceral leishmaniasis (kala-azar), a sub-acute infectious disease caused by the protozoan *Leishmania donovani* and endemic in Mediterranean countries, has been reported previously in small numbers of transplant recipients [1-7].

We would like to report the first such case diagnosed in Turkey. Our patient, a 34-year-old male with end-stage kidney failure due to chronic glomerulonephritis, had a live donor renal transplant in out unit on May 1988 and was put under standard prednisolone (Pred)-azathioprine (Aza) immunosuppressive regimen.

His follow-up was uneventful until post-transplant month 30 when hepatitis B markers were found positive. ALT and AST levels were normal and a liver biopsy was not done.

At posttransplant month 52 his hematocrit was 32%, hemoglobin 10.2 g/dl and leukocyte count 3,800/mm³. At posttransplant month 58, he had lost 13 kg weight and complained of weakness and night sweats. In addition to anemia and leukopenia, his ALT-AST levels had increased twofold above normal and he had low normal albuminemia and hyperglobulinemia. Because of a likelihood of Aza toxicity his Aza dosage was lowered from 100 to 75 mg/day. At post-transplant month 64 he was hospitalized.

He had lost 13 kg over the last 4 months and weighed 60 kg. Body temperature, blood pressure and pulse rate were normal. At physical examination he had no lymphadenomegaly, no liver enlargement, but a splenic enlargement of 1 cm beyond the costal

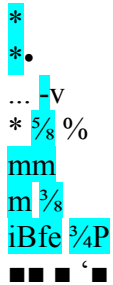


Fig. 1. *L. donovani* showing typical morphology in the bone marrow biopsy.

tum and gastric fluid and the skin test for tuberculin remained negative. An abdominal ultrasonography revealed a normal-looking liver with normal size and outline. The portal vein diameter was 15 mm and the spleen was enlarged with a diameter of 147 mm. No abdominal lymphadenomegaly was noted.

His spleen became palpable at 3 cm below the costal margin. An abdominal CT revealed a spleen size of 162 × 60 × 65 mm. The portal vein diameter had increased to 20 mm, but the liver size and structure were normal and there was no detectable intra-

KARGER

E-Mail karger@karger.ch Fax + 41 61 306 12 34 <http://www.karger.ch>

© 1997 S.Karger AG, Basel 0028-2766/97/0752-0241\$12.00/0

This article is also accessible online at: <http://BioMedNet.com> | karger

abdominal lymphadenomegaly. A bone marrow aspiration specimen revealed a normo-cellular marrow and uninterrupted myeloid maturation. The specimen caused no growth in a Novy-MacNeal-Nicolle (NNN) culture medium. Leishmania IgG antibody was positive in ELISA test. A bone marrow biopsy was performed and intrahistiocytic organisms with typical morphology for *L. donovani* were detected (fig. 1). A diagnosis of visceral leishmaniasis was made and the patient was treated for the next 28 days by pentavalent antimonial compound Glucantime (60 mg/kg/day, i.m.)

There was no fever throughout the treatment and posttreatment periods. By the end of treatment he had regained 6 kg weight and his fatigue had disappeared. One month later, an ultrasonography revealed a return of splenic size back to normal (137 mm). The portal vein diameter had decreased to 15 mm. His new laboratory findings were as follows: hemoglobin, 14.5 g/dl; hematocrit, 41%; leukocyte count, 8,100/mm³; ESR, 10 mm/h; serum urea, 65 mg/dl; serum creatinine, 1.3 mg/dl; albuminemia, 3.6 g/dl; globulinemia, 2.8 g/dl. The repeat ELISA test was negative for Leishmania IgG antibody. No protozoan could be seen in the repeat aspiration and biopsy specimens of the bone marrow and there was no growth in the NNN culture medium. Because of high posttreatment levels of liver enzymes (ALT, 149 IU; AST, 77 IU) and alkaline phosphatase (242 BU) and the presence of HbsAg and anti-Hbc antibody positivity, a liver biopsy was done. It revealed no substantial evidence of hepatitis. The liver enzyme levels subsided within a few weeks to normal.

Four months after cessation of therapy, the patient developed again complaints of fatigue. His hemoglobin, hematocrit and leukocyte levels were decreased anew (10.8 g/dl, 37% and

2,800/mm³, respectively). An abdominal ultrasonography revealed liver and spleen enlargement and the portal vein diameter was 17 mm. The ELISA test for Leishmania IgG antibody had become negative. The bone marrow aspiration and biopsy and also a splenic aspiration remained negative for protozoa under light microscopy. However, *L. donovani* was cultured from bone marrow biopsy in NNN medium.

Therapy was reinstated with allopurinol (1,200-1,600 mg) and Glucantime (20 mg/kg/day, total 850 mg) for 25 days. During therapy there was no alternation in serum urea and creatinine and the liver enzymes were normal. The spleen was 147 mm on ultrasonography.

At 6 weeks posttreatment, all clinical findings and laboratory values were within normal limits except the hepatic enzyme levels (ALT, 39 IU; AST, 45 IU). Ten months after cessation of Glucantime treatment (posttransplant 82nd month) the liver biopsy was repeated because of high levels of liver enzymes. There was only one portal area infiltrated by mononuclear cells in the histo-pathologic examination of the biopsy material. First-degree esophageal varices were observed in the upper gastrointestinal endoscopic examination. Atrophy of the right lobe of the liver, an enlarged vena porta (> 15 mm) and splenomegaly were found in the abdominal USG. These findings were consistent with portal hypertension. The patient has been followed in good general condition for 18 months after the end of his treatment for leishmaniasis and no signs of decompensated portal hypertension have been observed.

All of the cases of posttransplant leishmaniasis reported in the literature were diagnosed while investigating etiology of the fever [1-7]. In our case, however, despite the presence of bicytopenia and splenomegaly, fever was absent. Our patient's liver biopsy findings were consistent with minimal hepatitis and signs of portal hypertension were apparent. Since the initial liver biopsy findings did not match with either hepatitis B or hepatitis C, the portal hypertension could possibly be related to kala-azar.

In conclusion, in endemic areas, visceral leishmaniasis should be taken into consideration in immunocompromised or kidney transplant patients with unexplained accelerated ESR, bi/pancytopenia and hypergam-maglobulinemia.

References

- Ma DDF, Concannon A, Hayes J: Fatal leishmaniasis in renal transplant recipient. *Lancet* 1979;ii:311-312.
- Broeckart A, Michielsen P, Vandepitte S: Fatal leishmaniasis in renal transplant patient. *Lancet* 1979;ii:740-741.
- Martinez J, Masa Vasquez C, Pere Maeztu R: Visceral leishmaniasis as an opportunistic infection. *Lancet* 1986;i:1904.
- Lamas B, Orte L, Parras F, Garcia Larana J, Matesan ZR, Ortuna J: Non-fatal leishmaniasis in a renal transplant recipient. *Nephron* 1987; 45:71.
- Moulin B, Oilier J, Bouchouareb D, Purgus R, Olmer M: Leishmaniasis: A rare cause of unexplained fever in a renal graft recipient. *Nephron* 1992;60:360-362.
- Portoles J, Prats D, Tarralbo A, Herrero JA, Torrentc JA, Bairientos A: Visceral leishmaniasis: A cause of opportunistic infection in renal transplant patient in endemic areas. *Transplantation* 1994;57:1677-1679
- Mittal R, Saxena S, Guleria S, Mittal SK, Agar-wal SK, Tiwari SC, Dash SC: Visceral leishmaniasis: A rare cause of unexplained pyrexia in a renal allograft recipient. *Nephron* 1995;70: 123-124.

242

Nephron 1997;75:241-242

Apaydin/Ataman/Serdengeç/Tüzüner/ Polat/Erek/Ülkü