

Visual hallucinations in Lewy body disease relate to Lewy bodies in the temporal lobe

A. J. Harding,¹ G. A. Broe¹ and G. M. Halliday¹

¹Prince of Wales Medical Research Institute and University of New South Wales, Barker Street, Sydney, NSW 2031, Australia

Correspondence to: Associate Professor G. M. Halliday, Prince of Wales Medical Research Institute, Barker Street, Randwick, NSW 2031, Australia.
E-mail: G.Halliday@unsw.edu.au

Summary

Consensus opinion characterizes dementia with Lewy bodies (DLB) as a progressive dementing illness, with significant fluctuations in cognition, visual hallucinations and/or parkinsonism. When parkinsonism is an early dominant feature, consensus opinion recommends that dementia within the first year is necessary for a diagnosis of DLB. If dementia occurs later, a diagnosis of Parkinson's disease with dementia (PDD) is recommended. While many previous studies have correlated the neuropathology in DLB with dementia and parkinsonism, few have analysed the relationship between fluctuating cognition and/or well-formed visual hallucinations and the underlying neuropathology in DLB and PDD. The aim of the present study was to determine any relationship between these less-studied core clinical features of DLB, and the distribution and density of cortical Lewy bodies (LB). The brains of 63 cases with LB were obtained over 6 years following population-based studies of dementia and parkinsonian syndromes. Annual, internationally standardized, clinical assessment batteries were reviewed to determine the presence and onset of the core clinical features of DLB. The maximal density of LB, plaques and tangles in the amygdala, parahippocampal, anterior cingulate, superior frontal, inferior temporal, inferior parietal and visual cortices were determined. Current clinicopathological diagnostic criteria were used to classify cases into DLB ($n = 29$), PDD ($n = 18$) or parkinsonism without demen-

tia ($n = 16$) groups. Predictive statistics were used to ascertain whether fluctuating cognition or visual hallucinations predicted the clinicopathological group. Analysis of variance and regressions were used to identify any significant relationship(s) between the presence and severity of neuropathological and clinical features. Cognitive fluctuations and/or visual hallucinations were not good predictors of DLB in pathologically proven patients, although the absence of these features early in the disease course was highly predictive of PDD. Cases with DLB had higher LB densities in the inferior temporal cortex than cases with PDD. There was no association across groups between any neuropathological variable and the presence or absence of fluctuating cognition. However, there was a striking association between the distribution of temporal lobe LB and well-formed visual hallucinations. Cases with well-formed visual hallucinations had high densities of LB in the amygdala and parahippocampus, with early hallucinations relating to higher densities in parahippocampal and inferior temporal cortices. These temporal regions have previously been associated with visual hallucinations in other disorders. Thus, our results suggest that the distribution of temporal lobe LB is more related to the presence and duration of visual hallucinations in cases with LB than to the presence, severity or duration of dementia.

Keywords: cortical Lewy bodies; dementia with Lewy bodies; fluctuating cognition; Parkinson's disease; visual hallucinations

Abbreviations: CDR = clinical dementia rating; DLB = dementia with Lewy bodies; LB = Lewy bodies; NPV = negative predictive value; PDD = Parkinson's disease with late dementia; PPV = positive predictive value

Introduction

Dementia with Lewy bodies (DLB) is a clinicopathological diagnosis for a progressive dementing illness with fluctuating cognition, visual hallucinations and/or parkinsonism in

association with Lewy bodies (LB) in the brain (McKeith *et al.*, 1996). However, LB pathology in the midbrain has been most closely associated with idiopathic Parkinson's

disease and is currently mandatory for a definitive clinicopathological diagnosis of this disease (Gelb *et al.*, 1999). While there is still debate concerning the pathological overlap between these distinct clinical phenotypes, midbrain LB accumulate independently from those found in the cortex in DLB (Gómez-Tortosa *et al.*, 1999) and high densities of temporal lobe LB differentiate Parkinson's disease from cases with dementia (Harding and Halliday, 2001).

The consensus criteria for DLB require progressive cognitive decline, but do not require dementia as the initial symptom (McKeith *et al.*, 1996, 1999). The criteria state: 'The central feature required for a diagnosis of DLB is progressive cognitive decline of sufficient magnitude to interfere with normal social or occupational function. Prominent or persistent memory impairment may not necessarily occur in the early stages, but is usually evident with progression' (McKeith *et al.*, 1996). DLB is differentiated from Parkinson's disease with late developing dementia (PDD) by the early presentation of cognitive decline within a year of the initial presentations of the disease (most often parkinsonism) (McKeith *et al.*, 1996; McKeith, 1999).

Our recent comparison of the distribution and density of cortical LB in DLB, PDD and Parkinson's disease revealed considerable overlap between DLB and PDD, suggesting that the timing of the onset of dementia does not relate to the quantity or distribution of cortical LB (Harding and Halliday, 2001). Surprisingly, there have been very few studies of the relationship between the early presence of other differentiating clinical features of DLB (visual hallucinations and/or fluctuating cognition) and the amount of cortical LB. In the absence of a dominant dementia syndrome at presentation, these additional features reliably predict the clinicopathological phenotype of DLB. However, visual hallucinations are also found in approximately 25% of patients with Parkinson's disease (Aarsland *et al.*, 1999a, b; Fénelon *et al.*, 2000). It may be that the distribution and amount of cortical LB pathology relate more to additional and overlapping clinical features in such patient groups.

The present study analyses a large cohort of cases with LB pathology. Homogeneous clinicopathological groups of patients with DLB, PDD and Parkinson's disease were segregated and the predictive value of visual hallucinations and/or fluctuating cognition assessed. Correlations between the distribution of cortical LB and these clinical features were also performed. The literature would predict a close association between these variables. Recent analyses of specific hallucination categories identify three psychosyndromes that reflect activation of specific visual pathways (Santhouse *et al.*, 2000). In particular, the ventral temporal lobe is specialized for complex features relating to people, objects and landscapes (Tanaka, 1996; Halgren *et al.*, 1999; Santhouse *et al.*, 2000)—features characteristic of the well-formed visual hallucinations in DLB and some Parkinson's disease patients. It is well known that LB concentrate in the ventral temporal lobe in DLB, particularly in the amygdala (Mattila *et al.*,

1998, 1999, 2000; Hamilton, 2000), an area of the ventral temporal lobe activated by emotional facial interactions (Morris *et al.*, 1996). Additionally, our recent analysis of cortical LB densities in DLB, PDD and Parkinson's disease highlights the importance of parahippocampal LB in distinguishing cases with dementia from those with clinical Parkinson's disease (Harding and Halliday, 2001). In this study, we assess whether this distribution of cortical LB reflects the presence of these additional core features of DLB in homogeneous groups of cases followed to autopsy.

Methods

Brains were obtained over a 6-year period from participants in a number of clinical population-based studies of dementia (Broe *et al.*, 1990; Reid *et al.*, 1996a; Waite *et al.*, 1996) and parkinsonian syndromes (Hely *et al.*, 1999; Reid *et al.*, 1996b) in the Sydney area. For all participants, regular annual clinical assessments using protocols devised from internationally standardized assessment batteries were available for analysis. Cases with ocular abnormalities were excluded. Immediately following death, information on the presence and severity of all clinical features was verified using standardized questionnaires completed by the subject's specialist and general medical practitioners and a relative/carer/friend. Patients who significantly declined between their last assessment and death were excluded. Procedures for all studies (including consent) have been approved by the ethics review committees of the Central and South Eastern Sydney Areas Health Services and the Universities of Sydney and New South Wales.

For each case, the brain was removed, weighed and fixed by immersion in 15% buffered formalin for 2 weeks. The brain was routinely prepared for neuropathological analysis using current diagnostic criteria (Braak and Braak, 1991; Mirra *et al.*, 1991; McKeith *et al.*, 1996; National Institute on Aging and Reagan Institute Working Group on Diagnostic Criteria for the Neuropathological Assessment of Alzheimer's Disease, 1997; Gelb *et al.*, 1999; Harding and Halliday, 1998, 2001). Cases with prior head injury, cerebral infarction, frontotemporal dementia or progressive supranuclear palsy were excluded. Only cases with brainstem LB (McKeith *et al.*, 1996; Harding and Halliday, 1998, 2001) were included (98 of 185 participants coming to autopsy). Of the 98 LB cases, 32 had additional neuropathology excluding them from further analysis. Cases were then assessed clinicopathologically using our new screening algorithm to separate cases with Parkinson's disease only from those with dementia (Harding and Halliday, 2001). Of the cases with a maximum parahippocampal LB density of $>1/\text{field}$ ($n = 42$), three cases were not demented (all with maximum of two LB/field). These cases were excluded in order to define homogeneous clinicopathological groups of both non-demented and demented patients. Sixty-three cases satisfied all criteria and were included in the study.

Quantitation of cerebral pathology

Five cortical regions [frontal (Brodmann area 9), temporal (area 20), parietal (area 39), occipital (areas 17 and 18) and anterior cingulate (area 24) cortices], as well as the hippocampus and parahippocampus at the level of the lateral geniculate nucleus and the amygdala at its greatest cross-sectional area were assessed quantitatively. Standard application of the CERAD (Consortium to Establish a Registry for Alzheimer's Disease) method was initially used to determine the semi-quantitative levels of neuritic plaque within the cortex of each case (Mirra *et al.*, 1991).

In each region of each case, the assessment of neurofibrillary tangles in adjacent sections stained with antibodies to tau enabled the semi-quantitative assessment of the distribution of tangles for Braak staging of Alzheimer's disease (Braak and Braak, 1991). Additionally, this ensured no globose tangles were inadvertently included as LB in the analyses. Alzheimer's disease (National Institute on Aging and Reagan Institute Working Group on Diagnostic Criteria for the Neuropathological Assessment of Alzheimer's Disease, 1997) was a permissible pathological diagnosis, although cases with Alzheimer's disease but without brainstem LB were excluded.

In each region LB were identified in immunohistochemically stained sections using antibodies to ubiquitin or α -synuclein and formic acid pre-treatment (Takeda *et al.*, 1998). Sites of greatest LB density were determined at $\times 100$ magnification; the magnification was then increased to quantify the number of LB/ $\times 200$ field (field diameter of 1 mm). Paired Student's *t*-tests revealed no significant differences in the number of LB identified in sequential sections using either ubiquitin or α -synuclein antibodies (Fig. 1A and B; $P > 0.14$). Counts from sections containing the highest densities of LB were used.

Evaluation of clinical signs and symptoms

For each case, assessments were performed routinely throughout the disease course, including assessments for the presence or absence of spasticity, brisk reflexes, ankle clonus and/or extrapyramidal features (tremor, bradykinesia, cogwheeling, stooped posture and glabellar tap). The clinical response and dosage of levodopa therapy were documented. The clinical severity of parkinsonism was assessed using the Hoehn and Yahr score (Hoehn and Yahr, 1967). Cases were diagnosed with dementia using the NINCDS-ADRDA (National Institute for Neurological and Communicative Disorders and Stroke and the Alzheimer's Disease and Related Disorders Association) criteria for probable or possible Alzheimer's disease (McKhann *et al.*, 1984). Severity and progression of dementia were assessed according to the Mini-Mental State Examination and the Clinical Dementia Rating Scale (Morris, 1993). Functional impairment was rated by the Instrumental Activities of Daily Living (Lawton and Brody, 1969). The Neuropsychiatric Inventory

(Cummings *et al.*, 1994) was used to record psychiatric features, including depressive symptoms, hallucinations, disinhibition and apathy. Hallucinations are an under-reported phenomenon (Ballard *et al.*, 1997), and therefore careful repeated enquiries were made regarding this clinical feature. The average interval \pm standard deviation from last examination to death was 10 ± 7 months—substantially shorter than in previous analyses (Gómez-Tortosa *et al.*, 1999). The last assessments prior to death (verified or modified by the information received after death from the specialist, general medical practitioners and carers) were used in all correlations. Given all the clinical information available for each case, the present study concentrated on analysing the core clinical features of DLB (McKeith *et al.*, 1996, 1999), including bradykinesia and rigidity, fluctuations or clouding of consciousness, well-formed recurrent visual hallucinations and dementia. If these features were present, the date first noted was included in the analysis.

Visual hallucinations were noted when reported in the presence of the examiner on at least one occasion and/or when there were consistent reports by the subject to a carer. Flashing lights and similar phenomena reported to occur on hallucinogenic drugs (Fénelon *et al.*, 2000) were not considered well-formed visual hallucinations. The types of visual hallucinations considered were mostly complex features relating to people, objects and landscapes. Because there has been some discussion on the difficulty with the reliability of fluctuations in cognition (Ince *et al.*, 1998; McKeith *et al.*, 1999), transient reductions or loss of consciousness were recorded as fluctuations in cognition. These resembled transient ischaemic attacks or delirium. Because of poor reproducibility and reliability, episodic periods of confusion were not considered sufficient to be recorded as true fluctuations in cognition.

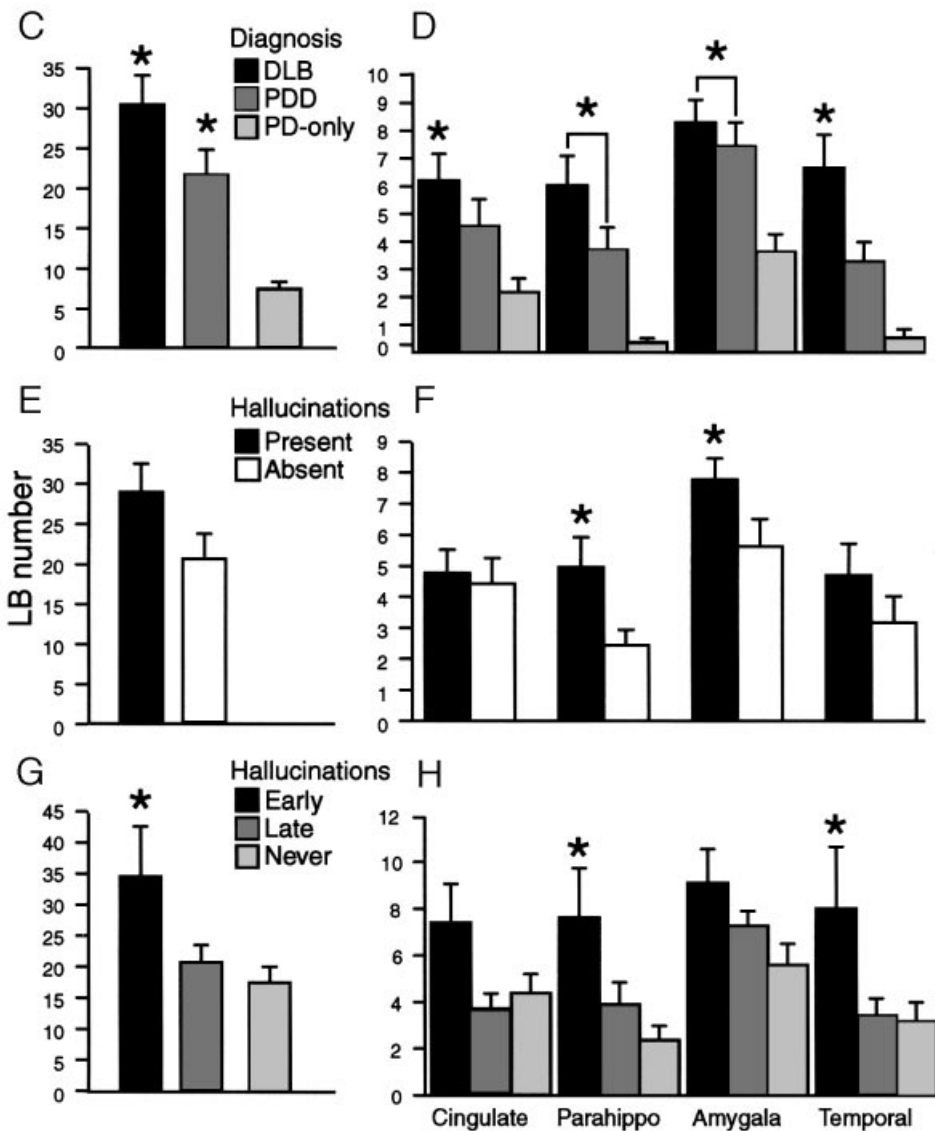
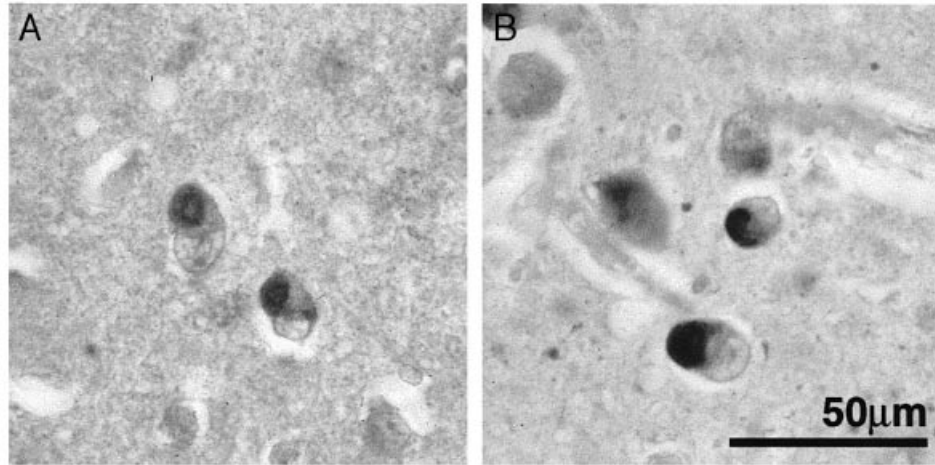
Case classification and statistics

Cases were classified according to their clinical presentations. Four cases had no evidence of parkinsonism throughout their course (DLB-PD group in Table 1). Because of their small number, this group was not evaluated in the statistical analyses. All remaining cases ($n = 59$) had a clinical history of parkinsonism, and were grouped into those without dementia (PD-only group in Table 1), those with early dementia (DLB group, Table 1) and those with late dementia (PDD group, Table 1). All Parkinson's disease-only and PDD subjects had good clinical improvement with high-dose levodopa therapy as required for a diagnosis of Parkinson's disease (Gelb *et al.*, 1999). The majority (14 out of 25) of cases in the DLB group were also on dopamine replacement therapy at their last assessment.

Most statistics were generated using the Statview programme (Abacus Concepts, Berkeley, Calif., USA) and a *P* value of 0.05 was taken as the level of significance. Differences between clinical groups were analysed using ANOVA (analysis of variance) and *post hoc* protected *t*-tests.

Positive and negative predictive values were calculated to ascertain whether other core clinical feature(s) predicted the clinicopathological group(s). Positive predictive values (PPVs) refer to the probability of having the clinical

feature(s) for a particular clinicopathological diagnosis, while negative predictive values (NPVs) refer to the probability of not having the clinical feature(s) for a particular clinicopathological diagnosis. As parkinsonism was common to all



groups subjected to statistical assessment, no significant relationships were found for this clinical feature. Separate analyses were conducted using the presence or absence of early features (within 2 years of the first clinical symptom or sign). For pathological correlations, a separate series of ANOVA (feature early/first, late or never) were performed. A similar group analysis was performed for dementia severity correlates with cortical LB densities. Regression analyses were performed to relate the duration of any clinical feature/s to cortical LB densities.

Results

Clinical findings

After applying all exclusion criteria, 63 cases with a mean age of 73 ± 10 years were assessed (47 males, 16 females, age range 42–89 years). A total of 47 cases had a clinical diagnosis of dementia (75% of the sample), and 59 cases (94%) had a clinical diagnosis of parkinsonism. Overall disease duration was significantly shorter for cases with clinical DLB than for those with clinical Parkinson's disease (Table 1; ANOVA = 11.7, $P < 0.0001$, protected t -test P values for DLB versus PDD < 0.0001 , DLB versus Parkinson's disease-only = 0.007, PDD versus Parkinson's disease-only = 0.10). As expected, the average clinical dementia rating (CDR) score was significantly different for demented versus non-demented cases (Table 1; ANOVA = 48.5, $P < 0.0001$; protected t -test P values for

Parkinson's disease-only versus clinical DLB, $P < 0.0001$; Parkinson's disease-only versus PDD, $P < 0.0001$; clinical DLB versus PDD, $P = 0.00003$). Cases with DLB had a significantly longer duration of dementia than cases with PDD (Table 1; $t = 3.02$, $P = 0.004$). There was no significant difference in the average Hoehn and Yahr score prior to death for any group (Table 1; ANOVA = 0.52, $P = 0.60$).

Only four cases had no clinical evidence of parkinsonism (DLB-PD group in Table 1). One case had sufficient plaques and tangles to reach NIA–Reagan (National Institute on Aging and Reagan Institute Working Group on Diagnostic Criteria for the Neuropathological Assessment of Alzheimer's Disease) criteria for the diagnosis of Alzheimer's disease. The remaining cases in this group all had short disease durations without any evidence of parkinsonism, even though they had significant midbrain cell loss and LB (required for study entry). All remaining cases ($n = 59$) had a clinical history of parkinsonism. Fifty-eight per cent of dementia cases were classified as DLB (Table 1), 19 with probable DLB and six with possible DLB (McKeith *et al.*, 1996). In terms of dementia severity, six DLB cases had only a mild dementia, six cases had moderate dementia and 13 cases had severe dementia (52% of DLB group; Table 1). In contrast, the majority of PDD cases had only a mild dementia (67%; Table 1). 72% of DLB cases ($n = 18$) and 89% of PDD cases ($n = 16$) had early parkinsonism, severe in 52% and 67%, respectively (Hoehn and Yahr scores of 4–5; Table 1).

Fig. 1 Photomicrographs (A and B) and graphs of Lewy body density data (C–H). Mean \pm Standard error of the mean. * indicates group(s) significantly different from Parkinson's disease without dementia (PD-only) group. (A and B) Photomicrographs showing the typical appearance of cortical Lewy bodies (LB) visualized in serial sections of the parahippocampal gyrus of a demented case using (α -synuclein (A) or ubiquitin (B) immunohistochemistry following formic acid pre-treatment. A similar pattern of LB pathology is seen (equal numbers of Lewy bodies were identified using either antibody, $P > 0.3$). Scale in B is equivalent to that for A. (C and D) Bar graphs of the total LB burden (C) and the individual regions with high LB densities (D) for the three clinicopathological groups, dementia with Lewy bodies (DLB), Parkinson's disease with later-onset dementia (PDD) and Parkinson's disease cases without dementia (PD-only). The total LB burden is determined by adding the maximum LB density per microscopic field for each of the anterior cingulate cortex, frontal association cortex, parahippocampal cortex, inferior temporal cortex and amygdala. LB densities were greatest in the amygdala. Both the DLB and PDD groups have greater LB densities than the PD-only group, although the PDD group was only significantly greater than the PD-only group in the parahippocampus and amygdala. The DLB group differed from the PDD group in the total sum of LB and in the LB density in the inferior temporal cortex. ANOVA (all regions, C) = 13.7, $P < 0.0001$; *post hoc* tests—DLB versus PDD, $P = 0.04$; DLB versus PD-only, $P < 0.0001$; PDD versus PD-only, $P = 0.004$. ANOVA (cingulate, D) = 4.6, $P = 0.01$; *post hoc* tests—DLB versus PDD, $P = 0.20$; DLB versus PD-only, $P = 0.004$; PDD versus PD-only, $P = 0.10$. ANOVA (parahippo, D) = 10.3, $P = 0.0002$; *post hoc* tests—DLB versus PDD, $P = 0.06$; DLB versus PD-only, $P < 0.0001$; PDD versus PD-only, $P = 0.02$. ANOVA (amygdala, D) = 7.4, $P = 0.0014$; *post hoc* tests—DLB versus PDD, $P = 0.49$; DLB versus PD-only, $P = 0.0004$; PDD versus PD-only, $P = 0.006$. ANOVA (temporal, D) = 9.6, $P = 0.0003$; *post hoc* tests—DLB versus PDD, $P = 0.017$; DLB versus PD-only, $P < 0.0001$; PDD versus PD-only, $P = 0.08$. (E and F) Bar graph comparing the total LB burden (E) and the individual regions with high LB densities (F) for cases who had hallucinations compared with those without them. Cases with hallucinations had greater LB densities in the parahippocampal cortex (F, $t = 5.1$, $P = 0.03$), and amygdala (F, $t = 4.2$, $P = 0.05$), but no significant differences were found for the overall LB burden (E, $t = 2.8$, $P = 0.10$), or for the other regions examined (F, anterior cingulate cortex ($t = 0.1$, $P = 0.7$), inferior temporal cortex ($t = 1.4$, $P = 0.25$), frontal association cortex ($t = 0.2$, $P = 0.9$)). (G and H) Bar graphs comparing the total LB burden (G) and the individual regions with high LB densities (H) for the cases who experienced hallucinations first or early in their disease (early), for those with hallucinations only later in their disease process (late), or those who never experienced hallucinations during their disease course (never). Only cases with early hallucinations had a greater LB burden compared with non-hallucinators (G). These cases had higher LB densities in the parahippocampal and inferior temporal cortices (H). ANOVA (all regions, G) = 3.9, $P = 0.03$; *post hoc* tests—early hallucinations versus late hallucinations, $P = 0.03$; early hallucinations versus no hallucinations, $P = 0.007$; late hallucinations versus no hallucinations, $P = 0.5$. ANOVA (cingulate, H) = 2.6, $P = 0.08$. ANOVA (parahippo, H) = 5.2, $P = 0.009$; *post hoc* tests—early hallucinations versus late hallucinations, $P = 0.03$; early hallucinations versus no hallucinations, $P = 0.002$; late hallucinations versus no hallucinations, $P = 0.2$. ANOVA (amygdala, H) = 2.8, $P = 0.07$. ANOVA (temporal, H) = 3.8, $P = 0.03$; *post hoc* tests—early hallucinations versus late hallucinations, $P = 0.02$; early hallucinations versus no hallucinations, $P = 0.01$; late hallucinations versus no hallucinations, $P = 0.9$.

Table 1 Number of cases and symptom duration (in years) for core symptoms of dementia with Lewy bodies (DLB): i.e. dementia, hallucinations, clouding of consciousness and parkinsonism.

	Total	DLB-PD	DLB	PDD	PD-only	
Number of cases	63	4	25	18	16	
Age (years)	73 ± 10	78 ± 3	72 ± 11	76 ± 7	70 ± 13	n.s.
Disease duration (years)	11 ± 6	7 ± 5	8 ± 5	15 ± 7	12 ± 4	<i>P</i> < 0.0001
Dementia	47	4	25	18	0	
First/early	28	4	25	0	0	
CDR 1	19	1	6	12	0	
CDR 2	10	1	6	3	0	
CDR3	18	2	13	3	0	
Duration (years)	4 ± 4	6 ± 5	7 ± 5	3 ± 2	0	<i>P</i> < 0.0001
Hallucinations	35	3	14	14	4	
Early	11	2	6	3	0	
Fluctuating cognition	25	2	13	7	3	
Early	13	1	9	2	1	
Parkinsonism	59	0	25	18	16	
Early	50	0	18	16	16	
H&Y 2–3	22	0	12	6	4	
H&Y 3–4	37	0	13	12	12	
Duration (years)	10 ± 8	0	5 ± 3	15 ± 7	12 ± 4	<i>P</i> < 0.0001

Groups are divided into: DLB without parkinsonism (DLB-PD); DLB (dementia before or within two years of developing parkinsonism); PDD (dementia developing at least 2 years after parkinsonism); and PD-only (parkinsonism without dementia). Severity of dementia and parkinsonism are reported as measured by the clinical dementia rating (CDR) scale and the Hoehn and Yahr scale (H&Y), respectively. Results are expressed as mean ± standard deviation.

Eleven cases had parkinsonism as their only feature (69% of Parkinson's disease-only group). As most cases with parkinsonism were at end-stage, parkinsonism was severe in most (Table 1). Fifty cases (85%) had parkinsonism early in the disease course. Of the two remaining DLB core symptoms, recurrent visual hallucinations were present in 35 cases (31 with dementia), an early symptom in 11 cases (31% of hallucinating cases, all with dementia). There were four Parkinson's disease-only cases that had visual hallucinations during their disease—although this was a feature only late in the disease course. Two of these four cases also had fluctuating cognition, including one case where fluctuating cognition was an early sign. Fluctuating cognition was recorded in 25 cases overall (22 with dementia) and was an early feature in 13 (52% of cases with this feature; Table 1).

Frequency of core DLB features in the clinicopathological groups

As dementia and parkinsonism were used for clinical grouping, these features will not be considered further. The presence of the other core clinical features of DLB (i.e. fluctuating cognition and visual hallucinations) were examined within each group to determine diagnostic profiles. The majority of DLB (56%) and PDD (78%) cases had visual hallucinations, an early sign in 43% and 21%, respectively. In contrast, only 25% of the Parkinson's disease-only group had hallucinations, and none was early. The majority of DLB

cases had cognitive fluctuations (52%), an early sign in 69%. In contrast, 39% of PDD and 19% of Parkinson's disease-only cases had recorded cognitive fluctuations, an early sign in only a minority (Table 1).

To analyse whether visual hallucinations and/or cognitive fluctuations were better predictors for either DLB or PDD, positive and negative predictive values were calculated using the proportion of cases with or without these features in each dementia group. Of these two symptoms, cognitive fluctuations had the best overall predictive power for DLB (PPV = 52%, NPV = 61% compared with PPV = 56%, NPV = 22% for hallucinations). The combination of these two features did not improve this predictive power (PPV = 32%, NPV = 67%). When the onset of the clinical feature was early, NPV improved for PDD (89% for fluctuations, 83% for hallucinations, 94% for both features occurring early) at the expense of PPV for DLB (36% for fluctuations, 24% for hallucinations, 4% for both features occurring early). These data show that, although neither of these features are good predictors of DLB in pathologically proven patients, the absence of these features early in the disease course is highly suggestive of PDD.

Distribution and densities of cerebral pathology

Across all groups, only six DLB cases had rare parietal lobe LB and fewer had LB in occipital cortex. LB in these regions were not considered further. Frontal association cortex had relatively low LB densities (2.1 ± 0.5 LB/field) with only 30% of cases having a maximum density of two or more LB/field. The greatest

densities of LB were found in the amygdala (6.8 ± 0.6 per field), anterior cingulate (4.4 ± 0.5 per field), inferior temporal (3.9 ± 0.6 per field) and parahippocampal (3.8 ± 0.6 per field) regions. Over 60% of cases had two or more LB per field in these cortical regions, with approximately half of these cases having seven or more LB per field. With the exception of the amygdala, where high densities of LB were present in the vast majority of cases, high densities of LB in one region usually predicted high densities in other regions (multiple regression analyses, $P < 0.001$, r^2 range = 0.64 to 0.81). These densities and distributions are similar to those reported by Mattila *et al.* (1998).

Comparing between the groups, Parkinson's disease-only cases were screened to exclude cases with significant cortical LB (Harding and Halliday, 2001) and all demented cases had significant densities of cortical LB. As described for both DLB and PDD (Samuel *et al.*, 1996; Haroutunian *et al.*, 2000; Mattila *et al.*, 2000), the combined sum of the maximum LB density across all regions examined was significantly greater in cases with DLB compared with PDD, and significantly greater in PDD compared with the Parkinson's disease-only cases (Fig. 1C; $P < 0.0001$). However, further analysis of the contribution of each individual region to this result shows that there were significantly higher LB densities only in the inferior temporal cortex of DLB cases compared with those with PDD (Fig. 1D; $P = 0.017$). Surprisingly, LB densities in all other regions examined were not significantly different between the dementia groups (Fig. 1D).

Twenty-seven cases (43%) had neuritic plaque densities sufficient for a CERAD diagnosis of probable or definite Alzheimer's disease. These criteria for Alzheimer's disease were reached by 72% of DLB cases and 33% of PDD cases. The cases with dementia and CERAD Alzheimer's disease had more cortical LB only in the parahippocampus (LB/field) compared with the demented cases without Alzheimer's disease (6.4 ± 5.1 LB/field versus 2.8 ± 2.2 LB/field, $P = 0.011$). Six cases had significant numbers of neurofibrillary tangles (Braak stages 4–6, all demented). One DLB case had significant tangles but rare plaques, whereas the remaining five cases reached NIA–Reagan criteria for the diagnosis of Alzheimer's disease (National Institute on Aging and Reagan Institute Working Group on Diagnostic Criteria for the Neuropathological Assessment of Alzheimer's Disease, 1997). LB concentrations within the amygdala (12 LB/field) were significantly higher in these cases with Braak stages 4–6 ($P = 0.0002$), even though the overall LB burden did not differ ($P = 0.96$). Together these data show that cases with DLB are more likely to have plaque pathology and higher temporal lobe LB compared with cases with PDD. Neurofibrillary tangles are rare in both groups using the exclusion criteria outlined. However, those cases with tangles that achieve all criteria for Alzheimer's disease (likely to contribute to or cause the dementia itself) concentrate LB in the amygdala.

Relationship between clinical features and cerebral Lewy bodies

Dementia

The sum of the combined maximum LB densities across all regions did not differentiate cases with mild dementia from those with more severe dementia ($P > 0.3$), although cases with DLB had more LB overall compared with both Parkinson's disease groups (Fig. 1C). There was no correlation between overall cortical LB burden and the duration of dementia ($P = 0.96$). As described above, DLB cases had significantly higher LB densities in the inferior temporal cortex (Fig. 1D), although there was no correlation between LB density and the duration of dementia ($P = 0.2$). This shows that high LB densities in the inferior temporal neocortex relate to the presence of early dementia and a diagnosis of DLB. In the PDD group, cases with moderate to severe dementia had higher densities of LB in the frontal cortex than those with mild dementia ($t = 5.6$, $P = 0.04$), as previously shown (Samuel *et al.*, 1996; Mattila *et al.*, 1998, 2000). However, this relationship did not hold true for cases with DLB ($t = 0.9$, $P = 0.3$) and was not related to the duration of dementia ($P = 0.7$).

Hallucinations

The majority of cases with hallucinations (28 out of 32) had dementia (either DLB or PDD). Cases with hallucinations had significantly more LB/field on average than those without hallucinations in the parahippocampus ($P = 0.028$) and amygdala ($P = 0.046$), but not in the frontal ($P = 0.88$), anterior cingulate ($P = 0.74$) or inferior temporal ($P = 0.25$) cortices (Fig. 1F). The overall cortical LB burden was significantly greater in those cases hallucinating initially or within the first years of disease onset regardless of diagnostic group (Fig. 1E and G; $P = 0.03$). This association was due to significantly more LB within the temporal cortices (Fig. 1H; $P = 0.009$ for parahippocampus, $P = 0.03$ for inferior temporal cortex). This indicates that LB pathology in medial temporal regions predisposes to hallucinations with the increasing involvement of more inferolateral temporal cortices ensuring the presence of hallucinations in cases with LB.

Fluctuating cognition

No significant statistical relationships were found between the summed or regional LB densities and fluctuations in cognition.

Discussion

The present study compares the clinical and pathological features of patients with parkinsonism and either early (DLB) or late (PDD) dementia. Our recent work revealed marked overlap between these clinical groups in the concentration and distribution of cortical LB (Harding and Halliday, 2001).

This prompted us to question the correlation between cortical LB and dementia. In order to address this issue, the analysis of any associations between other core clinical features and the degree of LB pathology is required. A direct comparison of the presence or absence of well-formed visual hallucinations between patient groups revealed that significant numbers of patients with either DLB or PDD had visual hallucinations. There is some suggestion in the literature that dopamine replacement therapy contributes to or exacerbates this clinical feature. However, all our Parkinson's disease and PDD cases had clinical benefit from high-dose levodopa therapy, regardless of the presence or absence of hallucinations, supporting the majority of studies showing no major association between levodopa therapy and hallucinations (Fénelon *et al.*, 2000; Aarsland *et al.*, 2001; Barnes and David, 2001; Holroyd *et al.*, 2001). Visual hallucinations were an early feature for 21% of the PDD group analysed, even though these patients did not reach criteria for dementia until much later in their disease (some 10–12 years later). The visual hallucinations reported by patients were mostly well-formed landscapes and figures (people and animals), with no significant difference in the form of hallucination experiences between groups. This finding is consistent with the recent reports on the incidence of well-formed visual hallucinations in Parkinson's disease (Manford and Andermann, 1998; Aarsland *et al.*, 1999a, b; Fénelon *et al.*, 2000; Holroyd *et al.*, 2001). Thus, the overlap in the pathological distribution of cortical LB may relate more to this clinical feature than to the diagnosis of dementia or brain dopamine levels.

The clinical information used in the current study was collected prospectively in a standard manner (Waite *et al.*, 1996; Reid *et al.*, 1996a, b; Hely *et al.*, 1999). The structured nature of this data collection ensured that all core symptoms were considered in all patients studied. Patients were followed throughout their disease until close to death (last assessment 10 ± 7 months prior to death). Thus, it is unlikely that core features were missed (false negatives) in the repeated (annual or biannual) clinical examinations. The well-formed, recurrent visual hallucinations were the only feature that may have relied on patient or carer reporting. In instances where visual hallucinations were not evidenced by the examiner at any stage, consistent reports by the subject of visual hallucinations, corroborated by a carer, were mandatory for inclusion as a disease feature. While visual hallucinations are considered an under-reported phenomenon (Ballard *et al.*, 1997), we believe that the repeated assessments over many years in these cases are likely to have revealed that the vast majority of patients experiencing this clinical feature. The significant relationship between LB densities and such visual hallucinations implies that the reporting of this clinical feature was reliable in this sample.

Previous prospective (Hohl *et al.*, 2000) and retrospective (Litvan *et al.*, 1998) studies have suggested that a more accurate diagnosis of DLB could be achieved if greater weight were given to the feature of visual hallucinations. Well-formed visual hallucinations help differentiate DLB

from other dementia syndromes (Hirono *et al.*, 1999). Our analysis comparing DLB and PDD suggests that this sign is not a good isolated predictor of DLB in patients with parkinsonism, as it occurs early in a proportion of Parkinson's disease patients who will dement much later. Recent studies have suggested that fluctuations in cognition give greater accuracy of diagnosis for DLB (McKeith *et al.*, 2000a; Walker *et al.*, 2000). While our results suggest that this feature concentrates in DLB, particularly as an early feature, our statistics show that this feature is also a poor isolated predictor in patients with parkinsonism.

Histopathological differences

Apart from our recent work (Harding and Halliday, 2001), few studies have compared the neuropathology of patients with DLB versus those with PDD. For such a comparison, we standardized our methods for analysing LB, plaques and tangles comparing the maximal densities for all lesions—as now widely adopted (Mirra *et al.*, 1991; Harding and Halliday, 1998; Newell *et al.*, 1999). Our data show that cases with DLB are more likely to have cortical plaque densities similar to those seen in Alzheimer's disease. This association is well-known (Hansen *et al.*, 1993; McKenzie *et al.*, 1996; Armstrong *et al.*, 1997, 1998; Samuel *et al.*, 1997; Brown *et al.*, 1998; Mattila *et al.*, 1998, 2000; Haroutunian *et al.*, 2000), although few studies have compared DLB with PDD cases. Our results suggest that the vast majority of cases with PDD do not have sufficient densities of cortical plaques to suggest Alzheimer's disease. Our previous analysis showed that, in DLB patients, both LB and plaques independently contributed to the dementia process (Harding and Halliday, 2001). We speculated that the combinations of these pathologies may account for the rapidity of the disease process in DLB (Harding and Halliday, 2001).

The present study also shows that patients with DLB have higher densities of LB in temporal neocortex compared with cases with PDD. This suggests that abnormal protein deposition in temporal neocortex relates to onset of cognitive decline and dementia in DLB rather than the stage or duration of dementia. A recent study suggests otherwise, reporting that the only clinicopathological relationship in cases with DLB is an increase in global LB burden with the duration of dementia (Gómez-Tortosa *et al.*, 1999). However, this study did not evaluate many of the temporal lobe structures analysed in the present study and included dementia cases who had parkinsonism for >2 years (PDD in the present study). Increasing pathology within the temporal neocortex relating to dementia onset may have been predicted based on multiple studies in cases with Alzheimer's disease (e.g. Braak and Braak, 1991) where increasing temporal neocortical pathology relates to dementia onset, stage and disease duration (Gertz *et al.*, 1996; Berg *et al.*, 1998; Delacourte *et al.*, 1999). Our results show that high densities of LB in the inferior temporal neocortex differentiate cases with DLB, and that

cases of PDD have increasing frontal LB densities with increasing dementia severity. We have previously shown that increasing densities of frontal LB are associated with significant frontal lobe atrophy (Cordato *et al.*, 2000), and others have shown increasing frontal LB burden relates to increasing cognitive impairment (Samuel *et al.*, 1996; Mattila *et al.*, 1998, 2000). This dichotomy of regional pathology suggests that the disease processes driving DLB and PDD differ.

In the present study, neurofibrillary tangles were rarely seen in either DLB or PDD. However, in those cases with sufficient neuritic pathology to reach all criteria for Alzheimer's disease (likely to contribute to or cause the dementia itself), LB concentrated in the amygdala. It has been noted that LB occur in the amygdala in the majority of cases with diverse neurodegenerative disorders, including familial and sporadic Alzheimer's disease (Lippa *et al.*, 1998; Hamilton, 2000; Marui *et al.*, 2000; Mukaetova-Ladinska *et al.*, 2000), Down's syndrome (Lippa *et al.*, 1999), Hallervorden–Spatz syndrome (Saito *et al.*, 2000) and the parkinsonian–dementia complex of Guam (Yamazaki *et al.*, 2000). These diseases have tau deposition in the amygdala in common with LB formation, suggesting that the formation of neurofibrillary tangles appears to precipitate LB within the amygdala independently of Parkinson's disease and/or DLB.

Clinicopathological correlates

We found no associations between cortical LB pathology and fluctuations in cognition, consistent with previous reports (Gómez-Tortosa *et al.*, 1999). In the present study, transient reductions or loss of consciousness were required for this feature to be positively identified. Reliable identification of this clinical feature is an acknowledged problem (McKeith *et al.*, 1999). Previous studies describe excessive daytime drowsiness and other milder features as consistent with cognitive fluctuations (McKeith *et al.*, 1996), and we may have chosen an arbitrarily severe cut-off for case inclusion. The prospective use of operational criteria for less severe fluctuations in cognition (Walker *et al.*, 2000) may reveal relationships not identified in the present study. Additionally, the measurement of subcortical pathology may relate better to this clinical feature than the cortical pathology we analysed.

High LB densities in the amygdala and parahippocampal cortex were associated with visual hallucinations. Furthermore, increasing numbers of temporal lobe LB were associated with the earlier onset of this clinical feature. Although not significant, higher average LB densities have been previously observed in paralimbic cortices in patients with hallucinations compared with those without (Gómez-Tortosa *et al.*, 1999). The larger numbers of cases analysed in the present study (35 out of 63 compared with 12 out of 25) are likely to have contributed to identifying this relationship as the numerical densities of cortical LB are relatively low. It should be noted that four of the 35 cases with recurrent visual hallucinations did not have dementia, but still had higher

densities of temporal lobe LB. This frequency of visual hallucinations in patients with Parkinson's disease is consistent with recent reports (Aarsland *et al.*, 1999a, b; Fénelon *et al.*, 2000). The amygdala and parahippocampus are regions commonly affected by pathology in dementing disorders, being the initiating sites for the pathology of Alzheimer's disease (Braak and Braak, 1991), which possibly precipitates amygdala LB formation (Lippa *et al.*, 1998; Hamilton, 2000; Marui *et al.*, 2000; Mukaetova-Ladinska *et al.*, 2000). Previously about 30% of cases with Alzheimer's disease were thought to experience similar well-formed visual hallucinations (Ballard *et al.*, 1997). However, recent studies suggest significantly fewer cases of Alzheimer's disease have this clinical feature (<5%) compared with the majority of cases with DLB (Hirono *et al.*, 1999). Parkinsonism and exaggerated cognitive decline are significant predictors of visual hallucinations in patients meeting criteria for probable Alzheimer's disease (Paulsen *et al.*, 2000), with prospective studies showing cortical LB in such cases (McShane *et al.*, 1995). This suggests that a similar distribution of cortical LB in cases with Alzheimer's disease may contribute to the clinical manifestation of visual hallucinations.

Few other neuropathological changes have been associated with well-formed visual hallucinations. Ocular pathology can precipitate visual hallucinations possibly via abnormal cortical release phenomena (Manford and Andermann, 1998; Santhouse *et al.*, 2000). Brainstem vascular lesions in the midbrain reticular formation can also cause complex visual hallucinations (Manford and Andermann, 1998). Although speculative, this is possibly due to the involvement of ascending noradrenergic, cholinergic and serotonergic pathways which are also associated with sleep disturbances (Manford and Andermann, 1998; Arnulf *et al.*, 2000; Turner *et al.*, 2000). To our knowledge, we have described the first consistent association between the presence of visual hallucinations and a structural pathology in the cortex. As isolated lesions of the temporal lobe do not cause such visual hallucinations, the participation of other brain pathways is highly likely. In this regard, greater reductions in choline acetyltransferase activity in the temporal lobe have been associated with a higher prevalence of hallucinations in Parkinson's disease, PDD and DLB (Perry *et al.*, 1991; Tiraboschi *et al.*, 2000). Thus, visual hallucinations are associated with two biological changes in the temporal cortex in LB disease—LB formation and decreased choline acetyltransferase activity. It will be important to determine the time course of the loss of presynaptic acetylcholine to reveal whether this pathology is a consequence of LB formation in the postsynaptic cortical neurones or a contributor to such intracellular pathology. This has important implications for long-term treatment benefit with cholinesterase inhibitors currently reported in cases with DLB (McKeith *et al.*, 2000b, Rojas-Fernandez, 2001).

The underlying brain activation patterns of people undergoing complex visual hallucinations have recently been described. In particular, patients with Charles Bonnet

syndrome, who report similar visual hallucinations to patients with LB, activate the anterior temporal projection of the ventral visual pathway when hallucinating about landscapes, figures, and vehicles with appropriate emotional context (ffytche *et al.*, 1998; ffytche and Howard, 1999; Santhouse *et al.*, 2000). These hallucinations are thought to occur because of a lack of occipital stimulation due to ocular pathology (ffytche *et al.*, 1998; ffytche and Howard, 1999; Santhouse *et al.*, 2000). Downstream ventral association cortices increase their activity as a result of cortical disinhibition with this abnormal activity in visual processing regions activating complex visual hallucinations. It would appear more than coincidental that the same brain regions concentrating LB in our patients with visual hallucinations were those activated by visual hallucinations in patients with the Charles Bonnet syndrome (Santhouse *et al.*, 2000), particularly as decreased occipital glucose metabolism also occurs in patients with LB (Imamura *et al.*, 1999, 2001; Lobotesis *et al.*, 2001). The reduction in occipital metabolism occurs without underlying pathological inclusions, with a recent study suggesting that white matter abnormalities contribute to this metabolic deficit (Higuchi *et al.*, 2000). In addition, DLB patients have preserved glucose metabolism in ventral temporal lobe regions, particularly those cases with visual hallucinations (Imamura *et al.*, 1999; Higuchi *et al.*, 2000; Lobotesis *et al.*, 2001). These data suggest that activity in ventral visual pathways in association with underactivity of the primary visual cortices contributes to the well-formed visual hallucinations reported in cases with LB.

While it is generally believed that intracytoplasmic inclusions are a sign of neurodegeneration, several studies quantifying cortical neuronal loss in patients with DLB have shown a remarkable neuronal preservation (Gómez-Isla *et al.*, 1999; Broe *et al.*, 2001), suggesting that cortical LB may not signify neurodegeneration. If these cortical inclusions do not disrupt neuronal metabolism sufficiently to cause degeneration, they may disrupt cell mechanisms sufficiently to cause an increase in metabolic demand for neuronal survival. This may contribute to the association between the concentration of temporal lobe LB and well-formed visual hallucinations found in the present study. In fact, the overall pattern of temporal lobe LB formation appears to be more relevant to the onset of visual hallucinations than to the onset of dementia in cases with cortical LB disease.

Acknowledgements

We wish to thank the many brain donors and their families who have made this work possible. This work was funded by a donor who wishes to remain anonymous (with no potential for conflict of interest), the National Health and Medical Research Council of Australia, the Australian Brain Foundation and Parkinson's NSW, as well as by equipment grants from the Ian Potter Foundation, the Clive and Vera Ramaciotti Foundation Equipment and the National Health and Medical Research Council of Australia.

References

- Aarsland D, Larsen J, Cummings JL, Laake K. Prevalence and clinical correlates of psychotic symptoms in Parkinson disease: a community-based study. *Arch Neurol* 1999a; 56: 595–601.
- Aarsland D, Larsen JP, Lim NG, Janvin C, Karlsen K, Tandberg E, et al. Range of neuropsychiatric disturbances in patients with Parkinson's disease. *J Neurol Neurosurg Psychiatry* 1999b; 67: 492–6.
- Aarsland D, Ballard C, Larsen JP, McKeith I. A comparative study of psychiatric symptoms in dementia with Lewy bodies and Parkinson's disease with and without dementia. *Int J Geriatr Psychiatry* 2001; 16: 528–36.
- Armstrong RA, Cairns NJ, Lantos PL. β -Amyloid A β deposition in the medial temporal lobe of patients with dementia with Lewy bodies. *Neurosci Lett* 1997; 227: 193–6.
- Armstrong RA, Cairns NJ, Lantos PL. The spatial patterns of Lewy bodies, senile plaques and neurofibrillary tangles in dementia with Lewy bodies. *Exp Neurol* 1998; 150: 122–7.
- Arnulf I, Bonnet A-M, Damier P, Bejjani B-P, Seilhean D, Derenne J-P, et al. Hallucinations, REM sleep and Parkinson's disease. A medical hypothesis. *Neurology* 2000; 55: 281–8.
- Ballard C, McKeith I, Harrison R, O'Brien J, Thompson P, Lowery K, et al. Aspects of dementia: a detailed phenomenological comparison of complex visual hallucinations in dementia with Lewy bodies and Alzheimer's disease. *Int Psychogeriatr* 1997; 9: 381–8.
- Barnes J, David AS. Visual hallucinations in Parkinson's disease: a review and phenomenological survey. [Review]. *J Neurol Neurosurg Psychiatry* 2001; 70: 727–33.
- Berg L, McKeel DW, Miller JP, Storandt M, Rubin EH, Morris JC, et al. Clinicopathologic studies in cognitively healthy aging and Alzheimer's disease. Relation of histologic markers to dementia severity, age, sex, and apolipoprotein E genotype. *Arch Neurol* 1998; 55: 326–35.
- Braak H, Braak E. Neuropathological staging of Alzheimer-related changes. [Review]. *Acta Neuropathol (Berl)* 1991; 82: 239–59.
- Broe GA, Henderson AS, Creasey H, McCusker E, Korton AE, Jorm AF, et al. A case-control study of Alzheimer's disease in Australia. *Neurology* 1990; 40: 1698–707.
- Broe M, Shepherd CE, Milward EA, Halliday GM. Relationship between DNA fragmentation, morphological changes and neuronal loss in Alzheimer's disease and dementia with Lewy bodies. *Acta Neuropathol (Berl)* 2001; 101: 616–24.
- Brown DF, Dababo MA, Bigio EH, Risser RC, Eagan KP, Hladik CL, et al. Neuropathologic evidence that the Lewy body variant of Alzheimer disease represents coexistence of Alzheimer disease and idiopathic Parkinson disease. *J Neuropathol Exp Neurol* 1998; 57: 39–46.
- Cordato NJ, Halliday GM, Harding AJ, Hely MA, Morris JG. Regional brain atrophy in progressive supranuclear palsy and Lewy body disease. *Ann Neurol* 2000; 47: 718–28.
- Cummings JL, Mega M, Gray K, Rosenberg-Thompson S, Carusi DA, Gornbein J. The Neuropsychiatric Inventory: comprehensive

- assessment of psychopathology in dementia. *Neurology* 1994; 44: 2308–14.
- Delacourte A, David JP, Sergeant N, Buée L, Watzet A, Vermersch P, et al. The biochemical pathway of neurofibrillary degeneration in aging and Alzheimer's disease. *Neurology* 1999; 52: 1158–65.
- Fénelon G, Mahieux F, Huon R, Ziegler M. Hallucinations in Parkinson's disease. Prevalence, phenomenology and risk factors. 2000; *Brain* 123: 733–45.
- ffytche DH, Howard RJ. The perceptual consequences of visual loss: 'positive' pathologies of vision. *Brain* 1999; 122: 1247–60.
- ffytche DH, Howard RJ, Brammer MJ, David A, Woodruff P, Williams S. The anatomy of conscious vision: an fMRI study of visual hallucinations. *Nat Neurosci* 1998; 1: 738–42.
- Gelb DJ, Oliver E, Gilman S. Diagnostic criteria for Parkinson's disease. [Review]. *Arch Neurol* 1999; 56: 33–9.
- Gertz H-J, Xuereb JH, Huppert FA, Brayne C, Krüger H, McGee MA, et al. The relationship between clinical dementia and neuropathological staging (Braak) in a very elderly community sample. *Eur Arch Psychiatry Clin Neurosci* 1996; 246: 132–6.
- Gómez-Isla T, Growden JH, McNamara M, Newell K, Gómez-Tortosa E, Hedley-Whyte ET, et al. Clinicopathologic correlates in temporal cortex in dementia with Lewy bodies. *Neurology* 1999; 53: 2003–9.
- Gómez-Tortosa E, Newell K, Irizarry MC, Albert M, Growden JH, Hyman BT. Clinical and quantitative pathologic correlates of dementia with Lewy bodies. *Neurology* 1999; 53: 1284–91.
- Halgren E, Dale AM, Sereno MI, Tootell RB, Marinkovic K, Rosen BR. Location of human face selective cortex with respect to retinotopic areas. *Hum Brain Mapp* 1999; 7: 29–37.
- Hamilton RL. Lewy bodies in Alzheimer's disease: a neuropathological review of 145 cases using α -synuclein immunohistochemistry. *Brain Pathol* 2000; 10: 378–84.
- Hansen LA, Masliah E, Galasko D, Terry RD. Plaque-only Alzheimer disease is usually the Lewy body variant, and vice versa. *J Neuropathol Exp Neurol* 1993; 52: 648–54.
- Harding AJ, Halliday GM. Simplified neuropathological diagnosis of dementia with Lewy bodies. *Neuropathol Appl Neurobiol* 1998; 24: 195–201.
- Harding AJ, Halliday GM. Cortical Lewy body pathology in the diagnosis of dementia. *Acta Neuropathol (Berl)* 2001; 102: 355–63.
- Haroutunian V, Serby M, Purohit DP, Perl DP, Marin D, Lantz M, et al. Contribution of Lewy body inclusions to dementia in patients with and without Alzheimer disease neuropathological conditions. *Arch Neurol* 2000; 57: 1145–50.
- Hely MA, Morris JG, Traficante R, Reid WG, O'Sullivan DJ, Williamson PM. The Sydney multicentre study of Parkinson's disease: progression and mortality at 10 years. *J Neurol Neurosurg Psychiatry* 1999; 67: 300–7.
- Higuchi M, Tashiro M, Arai H, Okamura N, Hara S, Higuchi S, et al. Glucose hypometabolism and neuropathological correlates in brains of dementia with Lewy bodies. *Exp Neurol* 2000; 162: 247–56.
- Hirono N, Mori E, Tanimukai S, Kazui H, Hashimoto M, Hanihara T, et al. Distinctive neurobehavioural features among neurodegenerative dementias. *J Neuropsychiatry Clin Neurosci* 1999; 11: 498–503.
- Hoehn MM, Yahr MD. Parkinsonism: onset, progression and mortality. *Neurology* 1967; 17: 427–42.
- Hohl U, Tiraboschi P, Hansen LA, Thal LJ, Corey-Bloom J. Diagnostic accuracy of dementia with Lewy bodies. *Arch Neurol* 2000; 57: 347–51.
- Holroyd S, Currie L, Wooten GF. Prospective study of hallucinations and delusions in Parkinson's disease. *J Neurol Neurosurg Psychiatry* 2001; 70: 734–8.
- Imamura T, Ishii K, Hirono N, Hashimoto M, Tanimukai S, Kazui H, et al. Visual hallucinations and regional cerebral metabolism in dementia with Lewy bodies DLB. *Neuroreport* 1999; 10: 1903–7.
- Imamura T, Ishii K, Hirono N, Hashimoto M, Tanimukai S, Kazui H, et al. Occipital glucose metabolism in dementia with Lewy bodies with and without parkinsonism: a study using positron emission tomography. *Dement Geriatr Cogn Disord* 2001; 12: 194–7.
- Ince PG, Perry EK, Morris CM. Dementia with Lewy bodies: a distinct non-Alzheimer dementia syndrome? [Review]. *Brain Pathol* 1998; 8: 299–324.
- Lawton MP, Brody EM. Assessment of older people: self-maintaining and instrumental activities of daily living. *Gerontologist* 1969; 9: 179–86.
- Lippa CF, Fujiwara H, Mann DM, Giasson B, Baba M, Schmidt ML, et al. Lewy bodies contain altered α -synuclein in brains of many familial Alzheimer's disease patients with mutations in presenilin and amyloid precursor protein genes. *Am J Pathol* 1998; 153: 1365–70.
- Lippa CF, Schmidt ML, Lee VM, Trojanowski JQ. Antibodies to α -synuclein detect Lewy bodies in many Down's syndrome brains with Alzheimer's disease. *Ann Neurol* 1999; 45: 353–7.
- Litvan I, MacIntyre A, Goetz CG, Wenning GK, Jellinger K, Verny M, et al. Accuracy of the clinical diagnoses of Lewy body disease, Parkinson's disease and dementia with Lewy bodies. A clinicopathologic study. *Arch Neurol* 1998; 55: 969–78.
- Lobotesis K, Fenwick JD, Phipps A, Ryman A, Swann A, Ballard C, et al. Occipital hypoperfusion on SPECT in dementia with Lewy bodies but not AD. *Neurology* 2001; 56: 643–9.
- Manford M, Andermann F. Complex visual hallucinations: clinical and neurobiological insights. [Review]. *Brain* 1998; 121: 1819–40.
- Marui W, Iseki E, Ueda K, Kosaka K. Occurrence of human α -synuclein immunoreactive neurons with neurofibrillary tangle formation in the limbic areas of patients with Alzheimer's disease. *J Neurol Sci* 2000; 174: 81–4.
- Mattila PN, Roytta M, Torikka H, Dickson DW, Rinne JO. Cortical Lewy bodies and Alzheimer-type changes in patients with Parkinson's disease. *Acta Neuropathol* 1998; 95: 576–82.
- Mattila, PM, Rinne JO, Helenius H, Roytta M. Neuritic degeneration in the hippocampus and amygdala in Parkinson's disease in relation to Alzheimer pathology. *Acta Neuropathol* 1999; 98: 157–64.

- Mattila PM, Rinne JO, Helenius H, Dickson DW, R oytt  M. α -Synuclein-immunoreactive cortical Lewy bodies are associated with cognitive impairment in Parkinson's disease. *Acta Neuropathol* 2000; 100: 285–90.
- McKeith IG. Dementia with Lewy bodies. In: Wolters EC, Scheltens P, Berendse HW, editors. *Mental dysfunction in Parkinson's disease*. Utrecht: Academic Pharmaceutical Productions; 1999. p. 194–208.
- McKeith IG, Galasko D, Kosaka K, Perry EK, Dickson DW, Hansen LA, et al. Consensus guidelines for the clinical and pathologic diagnosis of dementia with Lewy bodies DLB: report of the consortium on DLB international workshop. [Review]. *Neurology* 1996; 47: 1113–24.
- McKeith IG, Perry EK, Perry RH. Report of the second dementia with Lewy body international workshop: diagnosis and treatment. Consortium on Dementia with Lewy Bodies. [Review]. *Neurology* 1999; 53: 902–5.
- McKeith IG, Ballard CG, Perry RH, Ince PG, O'Brien JT, Neill D, et al. Prospective validation of consensus criteria for the diagnosis of dementia with Lewy bodies. *Neurology* 2000a; 54: 1050–8.
- McKeith IG, Del Ser T, Spano P, Emre M, Wesnes K, Anand R, et al. Efficacy of rivastigmine in dementia with Lewy bodies: a randomized, double-blind, placebo-controlled international study. *Lancet* 2000b; 356: 2031–6.
- McKenzie JE, Edwards RJ, Gentleman SM, Ince PG, Perry RH, Royston MC, et al. A quantitative comparison of plaque types in Alzheimer's disease and senile dementia of the Lewy body type. *Acta Neuropathol* 1996; 91: 526–9.
- McKhann G, Drachman D, Folstein M, Katzman R, Price DL, Stadlan EM. Clinical diagnosis of Alzheimer's disease: report of the NINCDS-ADRDA Work Group under the auspices of Department of Health and Human Services Task Force on Alzheimer's Disease. *Neurology* 1984; 34: 939–44.
- McShane R, Gedling K, Reading M, McDonald B, Esiri MM, Hope T. Prospective study of relations between cortical Lewy bodies, poor eyesight and hallucinations in Alzheimer's disease. *J Neurol Neurosurg Psychiatry* 1995; 59: 185–8.
- Mirra SS, Heyman A, McKeel D, Sumi SM, Crain BJ, Brownlee LM, et al. The consortium to establish a registry for Alzheimer's disease (CERAD). Part II. Standardization of the neuropathologic assessment of Alzheimer's disease. *Neurology* 1991; 41: 479–86.
- Morris JC. The Clinical Dementia Rating (CDR): current version and scoring rules. *Neurology* 1993; 43: 2412–14.
- Morris JS, Frith CD, Perrett DI, Rowland D, Young AW, Calder AJ, et al. A differential neural response in the human amygdala to fearful and happy facial expressions. *Nature* 1996; 383: 812–15.
- Mukaetova-Ladinska EB, Hurt J, Jakes R, Xuereb J, Honer WG, Wischik CM. α -Synuclein inclusions in Alzheimer and Lewy body diseases. *J Neuropathol Exp Neurol* 2000; 59: 408–17.
- National Institute on Aging and Reagan Institute Working Group on Diagnostic Criteria for the Neuropathological Assessment of Alzheimer's Disease. Consensus recommendations for the post-mortem diagnosis of Alzheimer's disease. [Review]. *Neurobiol Aging* 1997; 18 (4 Suppl): S1–2.
- Newell KL, Hyman BT, Growdon JH, Hedley-Whyte ET. Application of the National Institute on Aging NIA-Reagan Institute criteria for the neuropathological diagnosis of Alzheimer's disease. *J Neuropathol Exp Neurol* 1999; 58: 1147–55.
- Paulsen JS, Salmon DP, Thal LJ, Romero R, Weisstein-Jenkins C, Galasko D, et al. Incidence of and risk factors for hallucinations and delusions in patients with probable AD. *Neurology* 2000; 54: 1965–71.
- Perry EK, McKeith I, Thompson P, Marshall E, Kerwin J, Jabeen S, et al. Topography, extent, and clinical relevance of neurochemical deficits in dementia of Lewy body type, Parkinson's disease, and Alzheimer's disease. *Ann NY Acad Sci* 1991; 640: 197–202.
- Reid W, Broe G, Creasey H, Grayson D, McCusker E, Bennett H, et al. Age at onset and patterns of neuropsychological impairment in mild early-stage Alzheimer's disease: a study of a community-based population. *Arch Neurol* 1996a; 53: 1056–61.
- Reid WJ, Hely MA, Morris JGL, Broe GA, Adena M, O'Sullivan DJ, et al. A longitudinal study of Parkinson's disease: clinical and neuropsychological correlates of dementia. *J Clin Neurosci* 1996b; 3: 327–33.
- Rojas-Fernandez CH. Successful use of donepezil for the treatment of dementia with Lewy bodies. *Ann Pharmacother* 2001; 35: 202–5.
- Saito Y, Kawai M, Inoue K, Sasaki R, Arai H, Nanba E, et al. Widespread expression of α -synuclein and tau immunoreactivity in Hallervorden-Spatz syndrome with protracted clinical course. [Review]. *J Neurol Sci* 2000; 177: 48–59.
- Samuel W, Galasko D, Masliah E, Hansen LA. Neocortical Lewy body counts correlate with dementia in the Lewy body variant of Alzheimer's disease. *J Neuropathol Exp Neurol* 1996; 55: 44–52.
- Samuel W, Alford M, Hofstetter CR, Hansen L. Dementia with Lewy bodies versus pure Alzheimer disease: differences in cognition, neuropathology, cholinergic dysfunction and synapse density. *J Neuropathol Exp Neurol* 1997; 56: 499–508.
- Santhouse AM, Howard RJ, ffytche DH. Visual hallucinatory syndromes and the anatomy of the visual brain. *Brain* 2000; 123: 2055–64.
- Takeda A, Hashimoto M, Mallory M, Sundsumo M, Hansen L, Sisk A, et al. Abnormal distribution of the non-A β component of Alzheimer's disease amyloid precursor/ α -synuclein in Lewy body disease as revealed by proteinase K and formic acid pretreatment. *Lab Invest* 1998; 78: 1169–77.
- Tanaka K. Inferotemporal cortex and object vision. [Review]. *Annu Rev Neurosci* 1996; 19: 109–39.
- Tiraboschi P, Hansen LA, Alford M, Sabbagh MN, Schoos B, Masliah E, et al. Cholinergic dysfunction in diseases with Lewy bodies. *Neurology* 2000; 54: 407–11.
- Turner RS, D'Amato CJ, Chervin RD, Blaivas M. The pathology of REM sleep behaviour disorder with comorbid Lewy body dementia. *Neurology* 2000; 55: 1730–2.
- Waite LM, Broe GA, Creasey H, Grayson DA, Edelbrock D, O'Toole B. Neurological signs, aging and the neurodegenerative syndromes. *Arch Neurol* 1996; 53: 498–502.

Walker MP, Ayre GA, Cummings JL, Wesnes K, McKeith IG, O'Brien JT, et al. Quantifying fluctuation in dementia with Lewy bodies, Alzheimer's disease and vascular dementia. *Neurology* 2000; 54: 1616–25.

Yamazaki M, Arai Y, Baba M, Iwatsubo T, Mori O, Katayama Y, et al. α -Synuclein inclusions in amygdala in the brains of patients

with the parkinsonism-dementia complex of Guam. *J Neuropath Exp Neurolol* 2000; 59: 585–91.

Received April 12, 2001. Revised August 6, 2001.

Second revision September 27, 2001. Accepted October 4, 2001