

VISUAL IMPROVEMENT FOLLOWING INTRAVITREAL BEVACIZUMAB (AVASTIN) IN EXUDATIVE AGE-RELATED MACULAR DEGENERATION

PRADEEPA YOGANATHAN, MD,* VINCENT A. DERAMO, MD,*†
JAMES C. LAI, MD,*† RAJEN K. TIBREWALA, DESc,‡
DAVID M. FASTENBERG, MD*†

Purpose: To study the visual and anatomic outcome of intravitreal bevacizumab injection in the treatment of exudative age-related macular degeneration (AMD).

Methods: Retrospective review of patients who received one or more intravitreal bevacizumab injections for exudative AMD. Outcome measures include standardized visual acuity, optical coherence tomography (OCT), macular thickness and volume, intraocular pressure, and blood pressure at 24 or more weeks follow-up.

Results: Fifty eyes of 48 patients were identified. Patients were observed for a median length of follow-up of 34 weeks (range, 24–50 weeks). Thirty-six eyes (72%) had prior treatment with pegaptanib (Macugen) and/or photodynamic therapy (PDT) and 14 eyes (28%) were treatment-naive. Mean visual acuity increased by 6.5 letters ($P < 0.01$) at 4 weeks and 5.3 letters ($P < 0.01$) at 24 weeks after initial bevacizumab injection. At 24 weeks, naive eyes had a mean increase of 14.2 letters ($P < 0.001$) and previously treated eyes had a mean increase of 2.8 letters ($P = 0.06$). Overall, mean OCT macular thickness and volume decreased by 73 μm ($P < 0.001$) and 1.0 mm^3 ($P < 0.001$) respectively at last follow-up. At last follow-up, all eyes received an average of 3.5 injections and experienced an average of 1.08 recurrences. There was no incidence of severe vision loss or adverse effect.

Conclusion: Intravitreal bevacizumab has the potential for improvement in vision in both naive and previously treated eyes for at least 6 months. The benefit is more pronounced in eyes without prior pegaptanib and/or PDT.

RETINA 26:994–998, 2006

Choroidal neovascularization (CNV) is the primary cause of vision loss in wet age-related macular degeneration (AMD).¹ Molecular studies have shown that upregulation of vascular endothelial growth factor (VEGF) stimulates angiogenesis, the principle mech-

anism behind neovascularization.² VEGF increases vascular permeability and promotes endothelial cell growth, growth mediator release, and leukocyte recruitment.³ In animal models, anti-VEGF therapy has been shown to prevent the formation of CNV and decrease leakage from existing CNV.⁴

Pegaptanib (Macugen, OSIP, Melville, NY) is the only anti-VEGF agent approved for the treatment of exudative AMD.⁵ It is an aptamer that binds specifically to the VEGF₁₆₅ isoform and its intravitreal use has been shown to delay visual loss at 1 year.⁵ Ranibizumab (Lucentis, Genentech, South San Francisco, CA), currently in Phase III clinical trials, is an anti-

From the *Department of Ophthalmology, North Shore–Long Island Jewish Health System, Great Neck, New York; †Long Island Vitreoretinal Consultants, Great Neck, New York; and ‡School of Management, New York Institute of Technology, Old Westbury, New York.

None of the authors has any proprietary interest in the subject matter.

Reprint requests: Vincent A. Deramo, MD, Long Island Vitreoretinal Consultants, 600 Northern Blvd., Suite 216, Great Neck, NY 11021.

VEGF antibody fragment that binds all isoforms of VEGF-A.⁶ Ranibizumab and bevacizumab (Avastin, Genentech, South San Francisco, CA) are derived from a common murine antibody.^{6,7} Bevacizumab, the full-length anti-VEGF antibody, is approved for intravenous use in metastatic colon cancer.^{6,7} In a pilot study, patients with wet AMD who were treated with intravenous bevacizumab demonstrated visual improvement at 12 weeks.⁸ Avery and associates reported improved visual acuity after intravitreal bevacizumab in a series of patients in whom the majority had prior pegaptanib and/or photodynamic therapy (PDT) with verteporfin (Visudyne, Novartis AG, Bülach, Switzerland).⁹

We report a retrospective case series of patients who have been treated with intravitreal bevacizumab for subfoveal CNV secondary to AMD. All patients in this study have standardized visual acuity measurements and at least 24 weeks (6 months) of follow-up data.

Materials and Methods

Approval for this study was obtained through the North Shore–Long Island Jewish Health System Institutional Review Board Committee. A computerized database search selected patients with subfoveal CNV from neovascular AMD between September 1, 2005, and January 1, 2006. Patients were included if they received intravitreal bevacizumab for the treatment of AMD and if their visual acuity was recorded using a standardized Early Treatment Diabetic Retinopathy Study (ETDRS) chart.¹⁰ Patients with and without prior treatments of pegaptanib and/or PDT were included. Patients with less than 24 weeks follow-up, incomplete ETDRS visual acuity records, and previous treatments of bevacizumab outside our institution were excluded. Patients who underwent ocular surgery or laser during the study period were also eliminated. The following data were collected from the medical record: age, sex, past medical history, number and type of previous AMD treatment, and fluorescein angiographic classification of subfoveal CNV on presentation.

Initial and monthly data points included ETDRS visual acuity, presence of anterior chamber inflammation, intraocular pressure (IOP), and blood pressure (BP). Optical coherence tomography (OCT) (Stratus III OCT, Carl Zeiss, Dublin, CA) was used to assess central macular thickness and macular volume with six individual radial scans centered on the fovea. Recurrences were noted, defined as an increase in subretinal or intraretinal fluid or a significant increase in hemorrhage. The student *t*-test was used to analyze

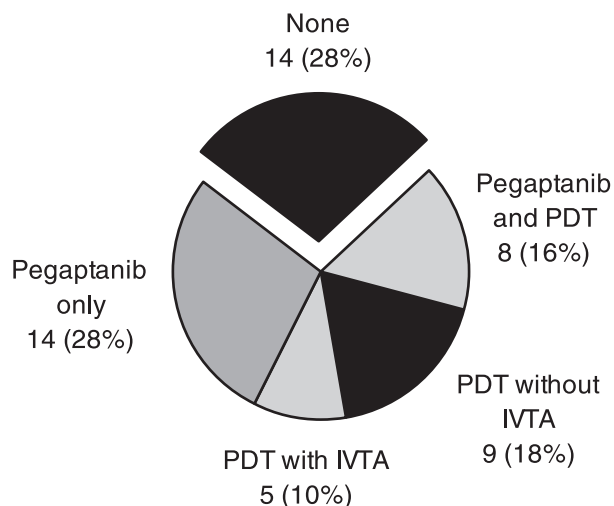


Fig. 1. Treatment history for all eyes. (PDT, photodynamic therapy; IVTA, intravitreal triamcinolone)

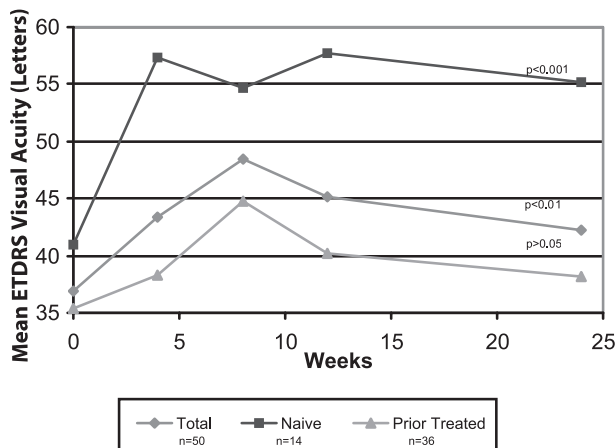
changes in ETDRS visual acuity, IOP, systolic BP, diastolic BP, macular thickness, and macular volume.

After the risks, benefits, and alternatives were discussed with patients, informed consent was obtained for the off-label use of intravitreal bevacizumab. Patients were not offered bevacizumab if they had untreated hypertension, myocardial infarction (MI), or cerebrovascular accident (CVA) in the prior 6 months. BP was recorded for patients before each injection. All eyes were treated with 5% povidone/iodine and topical antibiotics. Using aseptic technique, 1.25 mg (0.05 mL) of bevacizumab was injected into the vitreous cavity via the pars plana. Patients were instructed to use topical antibiotics for 3 days and were re-examined within 5 days after each treatment. Patients were asked to return at 1-month intervals to assess the need for additional treatments.

Results

Fifty eyes of 48 patients met all inclusion criteria. Median age was 79 years (range, 62–89 years). Thirty-one of 48 patients (65%) were female. Twenty-five patients (52%) had a history of hypertension, 9 patients (19%) had coronary artery disease, and 2 (4%) patients had prior myocardial infarction. Seven patients (15%) had glaucoma. At the time of initial diagnosis, 9 eyes (18%) had predominantly classic CNV, 9 (18%) had minimally classic CNV, and 32 (64%) had occult CNV. Fourteen of 50 eyes (28%) had no prior treatment for their subfoveal CNV. Thirty-six of 50 eyes (72%) had prior treatment of either pegaptanib and/or PDT (Figure 1).

Patients were observed for a median of 34 weeks (range, 24–50 weeks). Overall, the initial mean visual



P values significant at every time interval except at 24 weeks for Prior Treated patients only

Fig. 2. Mean standardized visual acuity over time for total, naive, and previously treated eyes.

acuity improved from 36.9 ± 21 (mean \pm SD) ETDRS letters (Snellen equivalent 20/200) to 42.2 ± 19 letters (Snellen equivalent 20/160) ($P < 0.01$) at 24 weeks (Figure 2). Twenty-three eyes (46%) gained at least five letters of visual acuity and 10 eyes (20%) gained at least 15 letters. Twelve eyes (24%) lost five or more letters and no eye lost 15 or more letters (Figure 3).

Visual acuity in the treatment-naive group improved from 41.0 ± 26 (Snellen equivalent 20/160) to 55.2 ± 22 letters (Snellen equivalent 20/63) ($P <$

0.001) at 24 weeks (Figure 2). Ten eyes (71%) gained at least five letters of visual acuity and 6 eyes (43%) gained at least 15 letters. One eye lost five letters (Figure 3). Eyes with prior subfoveal treatment with pegaptanib and/or PDT improved from 35.4 ± 19 (Snellen equivalent 20/200) to 38.2 ± 25 (Snellen equivalent 20/200) letters ($P = 0.06$ at 24 weeks [Figure 2]). Thirteen eyes (36%) gained at least five letters and 6 (17%) gained at least 15 letters. Eleven eyes (30%) lost five or more letters (Figure 3). Sub-group analyses revealed that improvement in visual acuity was greater in treatment-naive eyes compared to those previously treated with either pegaptanib and/or PDT ($P = 0.04$, *t*-test of unequal variance) (Figure 4).

Overall, mean initial macular thickness for all eyes was $339 \pm 130 \mu\text{m}$. Macular thickness decreased at 4 weeks to $269 \pm 94 \mu\text{m}$ ($P < 0.001$) and at 24 weeks to $266 \pm 92 \mu\text{m}$ ($P < 0.001$). Forty eyes (80%) had reduced thickness at last follow-up (Figure 5). Overall, mean initial macular volume for all eyes was $8.21 \pm 1.9 \text{ mm}^3$. Macular volume decreased at 4 weeks to $7.17 \pm 1.1 \text{ mm}^3$ ($P < 0.001$) and at 24 weeks to $7.15 \pm 1.2 \text{ mm}^3$ ($P < 0.001$). Forty eyes (80%) had reduced volume at last follow-up (Figure 6).

In the first 24 weeks (6 months) of treatment, all eyes received a mean of 3.5 injections (range, 1–6). The initial induction dose of intravitreal bevacizumab was given at the discretion of the doctor, and ranged from one to four monthly injections. After induction,

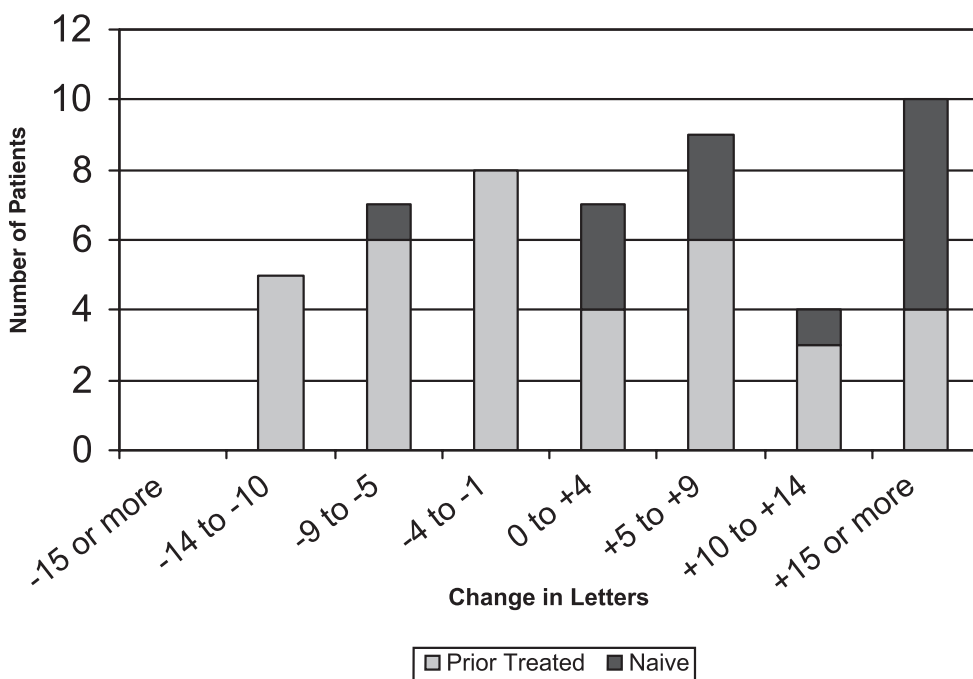


Fig. 3. Distribution of visual acuity change from baseline to 24 weeks.

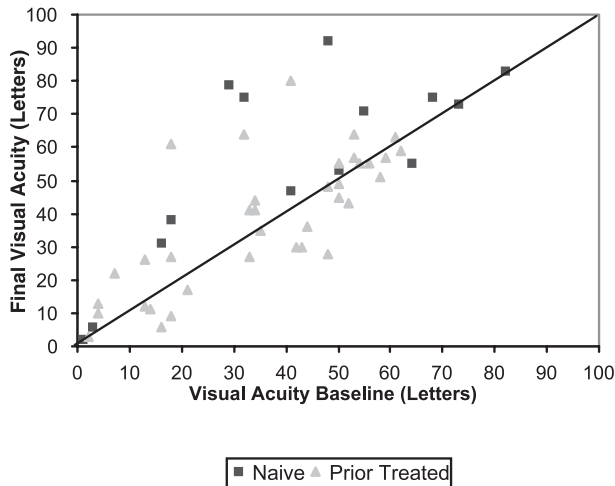


Fig. 4. Change in visual acuity from baseline to 24 weeks in treatment-naive and previously treated eyes.

patients were reinjected if recurrence was noted. Fifteen eyes (30%) developed a recurrence in the first 6 months. After 6 months, three eyes developed a second recurrence, and an additional 10 eyes developed their first recurrence. In total at last follow-up, 25 eyes (50%) never experienced recurrence. Eyes without recurrence received a mean of 2.6 injections and eyes with recurrence received a mean of 4.5 injections ($P < 0.001$). However, the mean number of injections did not vary significantly between the previously treated and treatment-naive groups with 3.3 and 3.6 injections respectively ($P > 0.5$).

There were no statistically significant changes in IOP, systolic BP, or diastolic BP at each monthly and final follow-up period (Table 1). No anterior chamber inflammation, retinal detachment, or endophthalmitis

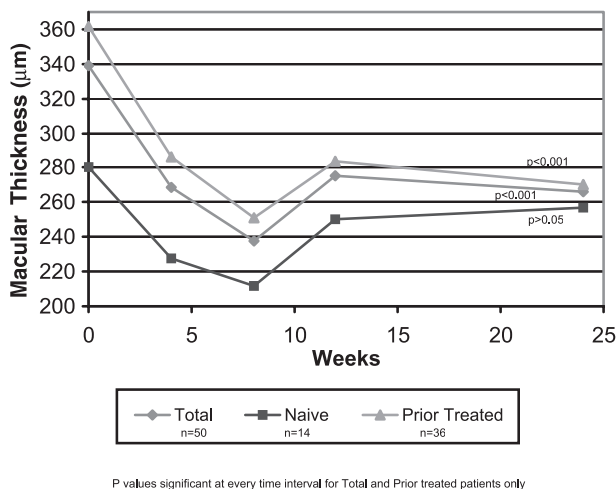


Fig. 5. Mean optical coherence tomography central macular thickness over time for total, naive, and previously treated patients.

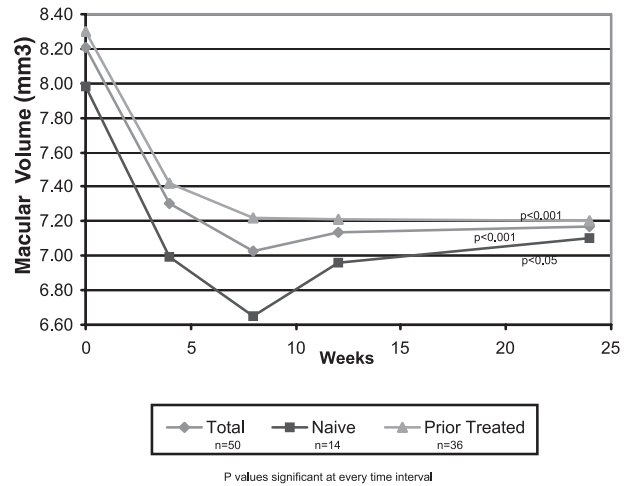


Fig. 6. Mean optical coherence tomography macular volume over time for total, naive, and previously treated patients.

was noted in any eye. No patient developed myocardial infarction or thromboembolic event.

Discussion

Intravitreal anti-VEGF therapies have emerged as an important modality in the treatment of neovascular AMD. Pegaptanib, an anti-VEGF aptamer, was approved by the Food and Drug Administration for the treatment of wet AMD based on its ability to effectively reduce the rate of vision loss in these patients.⁵ Preliminary data from Phase III clinical trials of ranibizumab, an anti-VEGF antibody fragment which binds all isoforms of VEGF-A, demonstrates an improvement in visual acuity in a significant proportion of treated patients (Miller JW, Chung CY, Kim R. Randomized, controlled phase III study of ranibizumab [Lucentis] for minimally classic or occult neovascular age-related macular degeneration. Paper presented at: American Society of Retinal Specialists 23rd annual meeting; July 18, 2005; Montreal, Canada). More recently, investigators have found that intravitreal injections of bevacizumab, the antibody similar in origin to ranibizumab, can improve visual

Table 1. Mean Intraocular Pressure (IOP), Systolic Blood Pressure (BP), and Diastolic Pressure Over Time

	IOP	Systolic BP, mmHg	Diastolic BP, mmHg
Onset	14.6	137.5	75.4
4 wk	15.0	132.7	73.8
8 wk	14.9	131.0	73.4
12 wk	14.4	130.4	74.4
Last follow-up	14.2	130.0	74.5
	$P > 0.4$	$P > 0.1$	$P > 0.2$

and anatomic outcomes in patients with neovascular AMD.^{9,12}

This study supports the growing body of evidence that bevacizumab is an effective treatment for exudative AMD.^{9,12} Eyes treated with intravitreal bevacizumab experienced a rapid and significant sustained improvement in not only standardized visual acuity but also macular thickness and volume through at least 24 weeks of follow-up. One-fifth of all eyes improved at least 15 letters of ETDRS visual acuity. Furthermore, the positive treatment effect was significantly greater in treatment-naïve eyes. Finally, the number of eyes that did not experience a recurrence was 50% at an average of 8 months follow-up.

Intravitreal bevacizumab at a dose of 1.25 mg (0.05 mL) appeared to be well tolerated by all patients. There is an increased risk of elevated BP and thromboembolic events following the administration of intravenous bevacizumab (5 mg/kg) and concurrent chemotherapy in patients with metastatic colon cancer.¹¹ However, the administered intravitreal dose of bevacizumab is approximately 1/400th that of the intravenous dose.¹² Our patient population had no reported thromboembolic events or change in BP during the study. Additionally, there were no adverse ocular events following the intravitreal injection of bevacizumab.

This study is limited by its retrospective nature and few patients. Lesion size and chronicity were not evaluated, and may have contributed to the dampened visual benefit in eyes previously treated with pegaptanib and/or PDT. Furthermore, the large percentage of eyes (64%) presenting with occult neovascularization makes comparisons with other studies difficult. Finally, the number of bevacizumab injections per eye was not uniform in our study. At 24 weeks follow-up, patients may still require further treatment and may not have exhibited their final visual acuity.

Our results demonstrate an overall rapid visual improvement after one intravitreal injection of bevacizumab. This improvement may remain stable for up to a period of 24 weeks. Additionally, treatment-naïve patients may show a greater response to intravitreal

bevacizumab compared to eyes previously treated with pegaptanib and/or PDT. These results support the need for a prospective, randomized clinical trial of intravitreal bevacizumab in the treatment of neovascular AMD.

Key words: age-related macular degeneration, Avastin, bevacizumab, choroidal neovascularization, vascular endothelial growth factor.

References

1. Ferris FL III, Fine SL, Hyman L. Age-related macular degeneration and blindness due to neovascular maculopathy. *Arch Ophthalmol* 1984;102:1640–1642.
2. Kliffen M, Sharma HS, Mooy CM, et al. Increased expression of angiogenic factors in age-related maculopathy. *Br J Ophthalmol* 1997;81:154–162.
3. Ferrara N, Davis-Smyth T. The biology of vascular endothelial growth factor. *Endocr Rev* 1997;18:4–25.
4. Krzystolik MG, Afshari MA, Adamis AP, et al. Prevention of experimental choroidal neovascularization with intravitreal anti-vascular endothelial growth factor antibody fragment. *Arch Ophthalmol* 2002;120:338–346.
5. Gragoudas ES, Adamis AP, Cunningham ET, et al. Pegaptanib for neovascular age-related macular degeneration. *N Engl J Med* 2004;351:2805–2816.
6. Heier JS, Antoszyk AN, Pavan PR, et al. Ranibizumab for treatment of neovascular age-related macular degeneration. *Ophthalmology* 2006;113:633–642.
7. Ferrara N, Hillan KJ, Gerber HP, Novotny W. Discovery and development of bevacizumab, an anti-VEGF antibody for treating cancer. *Nature* 2004;3:391–400.
8. Michels S, Rosenfeld PJ, Puliafito CA, et al. Systemic bevacizumab (Avastin) therapy for neovascular age-related macular degeneration. Twelve-week results of an uncontrolled open-label clinical study. *Ophthalmology* 2005;112:1035–1047.
9. Avery RL, Pieramici DJ, Rabena MD, et al. Intravitreal bevacizumab (Avastin) for neovascular age-related macular degeneration. *Ophthalmology* 2006;113:363–372.
10. Early Treatment Diabetic Retinopathy Study Research Group. Early treatment diabetic retinopathy study design and baseline patient characteristics. ETDRS report number 7. *Ophthalmology* 1991;98:741–756.
11. Rosiak J, Sadowski L. Hypertension associated with bevacizumab. *Clin J Oncol Nurs* 2005;9:407–411.
12. Rosenfeld PJ, Moshfeghi AA, Puliafito CA. Optical coherence tomography findings after intravitreal injection of bevacizumab (Avastin) for neovascular age-related macular degeneration. *Ophthalmic Surg Lasers Imaging* 2005;36:331–335.