

# Vogt Koyanagi Harada Disease: Treatment and Visual Prognosis

Mumtaz Alam, Mustafa Iqbal, Bakht Samar Khan and Ibrar Hussain

## ABSTRACT

Vogt Koyanagi Harada (VKH) disease is a chronic, bilateral, granulomatous panuveitis associated with central nervous system, auditory and integumentary manifestations. The study was conducted from January 2001 to December 2010 at the Department of Ophthalmology, Khyber Teaching Hospital, Peshawar. A total of 9 patients with diagnosis of Vogt Koyanagi Harada disease were included in the study. Extracted data included age, gender, duration of disease, initial and final visual acuities, treatment and complications. Initial visual acuity was ranging from 6/24 to perception of light. All the patients were treated with systemic and topical corticosteroids. In addition, one patient also received cytotoxic therapy. Final visual acuity was 6/18 or better in all cases (100%). One patient developed bilateral cataract, glaucoma and sub-retinal fibrosis at the macula. The cataract and glaucoma were managed as per established protocols. The visual prognosis of Vogt Koyanagi Harada disease is generally favourable if the disease is identified early and adequately treated and the associated complications are addressed properly.

**Key Words:** *Corticosteroids. Uveitis. Vogt Koyanagi Harada disease.*

---

## INTRODUCTION

Vogt Koyanagi Harada (VKH) disease is a chronic, bilateral, granulomatous panuveitis associated with central nervous system, auditory and integumentary manifestations.<sup>1</sup> The exact cause of this disease is uncertain, but T-lymphocyte mediated autoimmunity directed against melanocytes may play an important role.<sup>2</sup> There is an association between human leukocyte antigen (HLA) DR4 and VKH disease, especially the HLA-DRB1\*0405 allele.<sup>3</sup>

The clinical manifestations and course of the disease can be divided into four distinct phases,<sup>4</sup> i.e. prodromal phase, acute uveitic phase, convalescent phase and chronic-recurrent phase. It initially manifests with prodromal symptoms similar to aseptic meningitis and cerebrospinal fluid (CSF) pleocytosis, followed by posterior uveitis with exudative retinal detachments (RD) and optic disc hyperemia.<sup>5</sup> The acute phase is also characterized by anterior uveitis and diffuse choroidal infiltration. Later in the disease sunset-glow fundus and Dalen-Fuchs nodules may occur.<sup>6</sup>

The usual treatment for VKH disease is high-dose corticosteroid therapy followed by a slow tapering of the drug over 3 – 6 months. Patients who are intolerant to or with disease, that is resistant to corticosteroid therapy, may be treated with immunosuppressive drug therapy.<sup>7,8</sup>

Since VKH disease is a very rare disease and no tests are available to confirm its diagnosis, therefore, in our clinical practice its diagnosis cannot often be made confidently.

The aim of this study was to describe the clinical spectrum of patients with VKH disease and to document their long-term visual prognosis.

## METHODOLOGY

It was a case series conducted from January 2001 to December 2010, at the Department of Ophthalmology, Khyber Teaching Hospital, Peshawar. Seventeen eyes of 9 patients with clinical diagnosis of VKH disease were included in the study. They were studied for their final visual outcome after treatment.

Diagnosis of VKH disease was based on clinical features present at the time of initial assessment with the exclusion of other uveitic conditions. The exclusion was done by detailed history, ocular and systemic examination and relevant investigations. The published criteria for VKH disease were followed as advised by international committee on Vogt Koyanagi Harada disease.

Patients' demographic variables like age and gender were recorded. Initial and final best corrected visual acuities (BCVA) were the key variables studied in the long-term follow-up. Other parameters like duration of disease, treatment given, number and types of complications were also noted.

Initial visual acuity was that recorded at the time of first examination. The presence or absence of glaucoma and cataract was noted and were properly treated to exclude them as cause of visual deterioration and to have a clear view of fundus. Final visual acuity was taken as the

---

*Department of Ophthalmology, Eye 'B' Unit, Khyber Teaching Hospital, Peshawar.*

*Correspondence: Dr. Mumtaz Alam, House No. 310, Street No. 5, Sector E-4, Phase 7, Hayatabad, Peshawar.*

*E-mail: drmumtazalam@gmail.com*

*Received: February 09, 2012; Accepted: June 03, 2013.*

**Table I:** Summary of clinical findings, management, initial and final visual acuity.

No.	Ocular features / complications	Systemic features	Initial BCVA	Treatment	Final BCVA
1.	Bilateral panuveitis, serous retinal detachment and periorbital swelling	Vitiligo	Rt 6/60 Lt CF 2 m	Oral + topical steroids	Rt 6/6 Lt 6/12
2.	Bilateral panuveitis and serous retinal detachment	Meningismus	Rt CF 1 m Lt CF 1 m	Oral + topical steroids	Rt 6/6 Lt CF 1m
3.	Bilateral panuveitis, serous retinal detachment and swollen disc; Bilateral cataract, glaucoma and macular sub-retinal fibrosis	Meningismus	Rt 6/24 Lt CF 1 m	Oral + topical steroids + Cyclosporine + Bilateral Phaco + IOL, Topical + Oral anti-glaucoma drugs, Bilateral Diode laser cycloablation	Rt 6/9 Lt 6/9
4.	Bilateral panuveitis and serous retinal detachment	--	Rt CF 1 m Lt CF 1 m	Oral + topical steroids	Rt 6/6 Lt 6/6
5.	Bilateral panuveitis and serous retinal detachment	--	Rt CF 1 m Lt CF 1 m	Oral + topical steroids	Rt 6/12 Lt 6/12
6.	Bilateral panuveitis, serous retinal detachment; sunset glow fundus	--	Rt CF 1 m Lt CF 1 m	Oral + topical steroids	Rt 6/6 Lt 6/6
7.	Bilateral panuveitis and serous retinal detachment	--	Rt CF 1 m Lt CF 1 m	Oral + topical steroids	Rt 6/6 Lt 6/6
8.	Bilateral panuveitis, serous retinal detachment; peripheral chorioretinal scarring	--	Rt CF 1 m Lt PL+	Oral + topical steroids	Rt 6/9 Lt 6/9
9.	Bilateral panuveitis, serous retinal detachment and swollen disc	Meningismus	Rt 6/24 Lt CF 1 m	Intravenous + oral + topical steroids	Rt 6/6 Lt 6/6

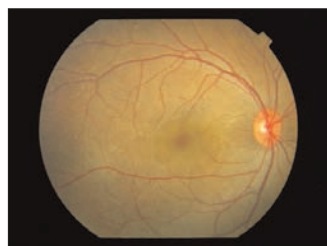BCVA = Best corrected visual acuity; Rt = Right; Lt = Left; CF = Counting fingers; m = Meter; Phaco = Phacoemulsification; IOL = Intraocular lens; PL+ = Perception of light.

visual acuity at last follow-up visit. Follow-up period was variable with a mean of 44 months. Fundus photograph of all the patients were taken (when there was a clear fundus view).

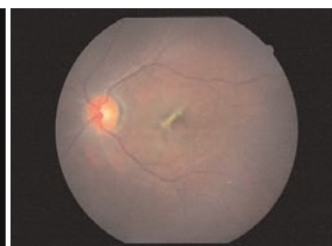
## RESULTS

A total of 9 patients with a diagnosis of Vogt Koyanagi Harada disease were identified. Out of them, 4 were males and 5 were females. Age of the patients at the time of diagnosis was ranging from 16 to 43 years with a mean of 28 years. Ocular signs (Figures 1-6) were present in all the 9 patients and systemic findings were present in 4 patients. The left eye of patient no. 2 already had traumatic macular scar and was not included in the study (Table I). Initial visual acuity (VA) was ranging from 6/24 to light perception (PL+) [Table II]. All the 9 patients were treated with topical plus oral corticosteroids. The dose of oral steroids (Prednisolone) was 1-1.5 mg/

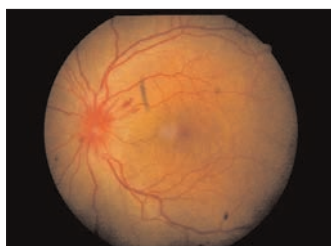
kg/day initially and it was then gradually tapered. One patient also received pulse steroid therapy (Intravenous Methylprednisolone 1 g/day) for 3 days which was followed by oral steroid therapy. In addition, one of the patients also received cytotoxic therapy (cyclosporine). All the patients were followed for 12 – 94 months with a mean duration of 44 months. Vision threatening ocular complications included glaucoma, cataract and macular



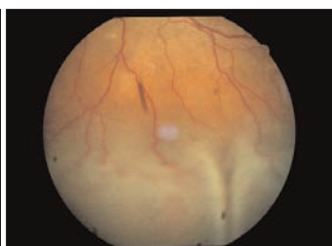**Figure 3:** Fundus photograph showing serous retinal detachment involving macula.



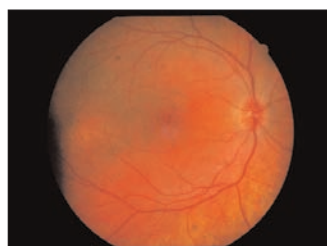**Figure 4:** Fundus photograph showing macular sub-retinal fibrosis.



**Figure 1:** Fundus photograph showing optic disc hyperemia and haemorrhages near the disc.



**Figure 2:** Fundus photograph showing serous retinal detachment involving inferior retina.



**Figure 5:** Fundus photograph showing leopard skin appearance after resolution of retinal detachment.



**Figure 6:** Fundus photograph showing sunset glow appearance.

**Table II:** Initial and final BCVA.

	Initial BCVA	Final BCVA
	n (%)	n (%)
PL +	01 eyes (05.88%)	-
HM	-	-
CF	13 eyes (76.47%)	-
6/60	01 eyes (05.88%)	-
6/36	-	-
6/24	02 eyes (11.76%)	-
6/18	-	02 eyes (11.76%)
6/12	-	03 eyes (17.64%)
6/9	-	02 eyes (11.76%)
6/6	-	10 eyes (58.82%)

BCVA = Best corrected visual acuity; PL = Perception of light; HM = Hand movement; CF = Counting fingers.

sub-retinal fibrosis in 2 eyes (11.7%) each. They all occurred in the same patient. Glaucoma was treated medically and with diode laser cycloablation in both eyes. Cataract was treated by phacoemulsification with intraocular lens implantation. Final visual acuity was 6/18 or better in all the 17 eyes (Table II).

## DISCUSSION

VKH disease has been known since long-time but exact cause and effective therapy is still unknown. Since the cause is unknown so there is no specific diagnostic test for this disease. The diagnosis is based on a combination of clinical findings and ancillary tests.

The first diagnostic criteria for Vogt Koyanagi Harada disease was established in 1978 by the American Uveitis Society. In 2001, the revised diagnostic criteria for Vogt Koyanagi Harada disease was established by VKH disease committee.<sup>9</sup> The disease is characterized by both ocular and systemic features. In this study, ocular signs were present in all the patients while systemic features were present in 4 out of 9 (44%) patients.

High dose systemic steroid therapy is the mainstay of treatment for Vogt Koyanagi Harada disease.<sup>10</sup> In this study, 8 patients (15 eyes) were treated with oral corticosteroid therapy. The regimen was 1-1.5 mg/kg body weight with gradual tapering over several months. One patient with very severe disease received intravenous methylprednisolone 1 g/day for 3 days followed by oral prednisolone 1 mg/kg/day. The resolution of retinal detachment was observed within a week with regression of inflammation and improvement of VA in all cases.

Immunosuppressive therapy may be required in patient who are steroid resistant or those who develop side effects due to steroids. In this study, most of the patients responded well to steroids. Only 1 patient (11.1%) was resistant to maximum dose of steroids, and was given oral immunosuppressive therapy (tablet cyclosporine).

In well-established Vogt Koyanagi Harada syndrome, the visual prognosis is quite fair. Mondkar *et al.* achieved final vision between 6/60 and 6/18 in 73.6% cases and 6/18 or better in 15.04% cases.<sup>7</sup> Tesavibul *et al.* achieved final visual acuity of 6/12 or better in 75.8% of the eyes, between 6/12 and 6/60 in 10.6%, less than 6/60 to light perception in 10.6% and no light perception in 3%.<sup>11</sup> In this study the visual acuity improved in all the eyes. Final visual acuity was 6/18 or better in all the 17 eyes. The mean follow-up period was 44 months. Better results in these patients were due to the prompt initiation of aggressive therapy, very slow tapering of corticosteroids and proper management of complications.

## CONCLUSION

Vogt Koyanagi Harada disease is a very rare disease and needs long-term systemic steroid therapy. Steroid resistant cases benefit from immunosuppressive therapy. If the disease is diagnosed early and the disease and its complications are adequately treated, long-term visual prognosis is very good.

## REFERENCES

- Cardoso IH, Zajdenweber ME, Muccioli C, Fimamor LP, Belfort R Jr. Applicability of the 2001 revised diagnostic criteria in Brazilian Vogt-Koyanagi-Harada disease patients. *Arq Bras Ophthalmol* 2008; **71**:67-70.
- Gocho K, Kondo I, Yamaki K. Identification of autoreactive T cells in Vogt-Koyanagi-Harada disease. *Invest Ophthalmol Vis Sci* 2001; **42**:2004-9.
- Sheu SJ. Update on uveomeningoencephalitides. *Curr Opin Neurol* 2005; **18**:323-9.
- Tesavibul N. Vogt-Koyanagi-Harada syndrome. In: Vitale AT, editor. *Diagnosis and treatment of uveitis*. Philadelphia: WB Saunders; 2002. p. 748-56.
- Read RW, Rao NA, Cunningham ET. Vogt-Koyanagi-Harada disease. *Curr Opin Ophthalmol* 2000; **11**:437-42.
- Kanski JJ. Uveitis. In: Kanski JJ, editor. *Clinical ophthalmology: a systemic approach*. 6th ed. Philadelphia: Butterworth Heinmann; 2007. p. 441-508.
- Mondkar SV, Biswas J, Ganesh SK. Analysis of 87 cases with Vogt-Koyanagi-Harada disease. *Jpn J Ophthalmol* 2000; **44**:296-301.
- Beniz J, Forster DJ, Lean JS, Smith RE, Rao NA. Variations in clinical features of the Vogt-Koyanagi-Harada syndrome. *Retina* 1991; **11**:275.
- Read RW, Holland GN, Rao NA, Tabbara KF, Ohno S, Arellanes-Garcia L, *et al.* Revised diagnostic criteria for Vogt-Koyanagi-Harada disease: report of an international committee on nomenclature. *Am J Ophthalmol* 2001; **131**:647-52.
- Kotake S, Ohno S. Pulse methylprednisolone therapy in the treatment of Vogt-Koyanagi-Harada's disease. *Jpn J Clin Ophthalmol* 1984; **38**:1053-8.
- Tesavibul N, Sansanayuth W. Vogt-Koyanagi-Harada disease in Thai patients. *J Med Assoc Thai* 2005; **88**:S26-30.

