

Volumetric brain analysis in neurosurgery: Part 3. Volumetric CT analysis as a predictor of seizure outcome following temporal lobectomy

*Jason G. Mandell, MS, MD,^{1,2} Kenneth L. Hill, MD,³ Dan T. D. Nguyen, MD,⁴ Kevin W. Moser, PhD,⁴ Robert E. Harbaugh, MD,⁵ James McInerney, MD,⁵ Brian Kaaya Nsubuga,⁶ John K. Mugamba, MD,⁶ Derek Johnson,⁶ Benjamin C. Warf, MD,^{6,7,8} Warren Boling, MD,⁹ Andrew G. Webb, PhD,¹⁰ and Steven J. Schiff, MD, PhD^{1,5,11,12}

¹Center for Neural Engineering, ¹¹Department of Engineering Science and Mechanics and Departments of ²Bioengineering and ¹²Physics, The Pennsylvania State University, University Park; Departments of ⁴Radiology and ⁵Neurosurgery, The Pennsylvania State University, Penn State Hershey Medical Center, Hershey, Pennsylvania; ³Department of Neurosurgery, Emory University, Atlanta, Georgia; ⁷Department of Neurosurgery, Boston Children's Hospital; ⁸Department of Global Health and Social Medicine, Harvard Medical School, Boston, Massachusetts; ⁹Department of Neurosurgery, University of Louisville, Louisville, Kentucky; ⁶CURE Children's Hospital of Uganda, Mbale, Uganda; and ¹⁰C.J. Gorter Center for High Field MRI, Department of Radiology, Leiden University Medical Center, Leiden, The Netherlands

OBJECT The incidence of temporal lobe epilepsy (TLE) due to mesial temporal sclerosis (MTS) can be high in developing countries. Current diagnosis of MTS relies on structural MRI, which is generally unavailable in developing world settings. Given widespread effects on temporal lobe structure beyond hippocampal atrophy in TLE, the authors propose that CT volumetric analysis can be used in patient selection to help predict outcomes following resection.

METHODS Ten pediatric patients received preoperative CT scans and temporal resections at the CURE Children's Hospital of Uganda. Engel classification of seizure control was determined 12 months postoperatively. Temporal lobe volumes were measured from CT and from normative MR images using the Cavalieri method. Whole brain and fluid volumes were measured using particle filter segmentation. Linear discrimination analysis (LDA) was used to classify seizure outcome by temporal lobe volumes and normalized brain volume.

RESULTS Epilepsy patients showed normal to small brain volumes and small temporal lobes bilaterally. A multivariate measure of the volume of each temporal lobe separated patients who were seizure free (Engel Class IA) from those with incomplete seizure control (Engel Class IB/IIB) with LDA ($p < 0.01$). Temporal lobe volumes also separate normal subjects, patients with Engel Class IA outcomes, and patients with Class IB/IIB outcomes ($p < 0.01$). Additionally, the authors demonstrated that age-normalized whole brain volume, in combination with temporal lobe volumes, may further improve outcome prediction ($p < 0.01$).

CONCLUSIONS This study shows strong evidence that temporal lobe and brain volume can be predictive of seizure outcome following temporal lobe resection, and that volumetric CT analysis of the temporal lobe may be feasible in lieu of structural MRI when the latter is unavailable. Furthermore, since the authors' methods are modality independent, these findings suggest that temporal lobe and normative brain volumes may further be useful in the selection of patients for temporal lobe resection when structural MRI is available.

<http://thejns.org/doi/abs/10.3171/2014.9.PEDS12428>

KEY WORDS epilepsy; temporal lobe; volume; CT; MRI; developing country; technique

ABBREVIATIONS CAH = cortico-amygdalo-hippocampectomy; CCHU = CURE Children's Hospital of Uganda; EEG = encephalography; IRB = institutional review board; LDA = linear discrimination analysis; MMSE = Mini-Mental State Examination; MTS = mesial temporal sclerosis; TLE = temporal lobe epilepsy.

SUBMITTED September 4, 2012. **ACCEPTED** September 25, 2014.

INCLUDE WHEN CITING Published online November 28, 2014; DOI: 10.3171/2014.9.PEDS12428.

DISCLOSURE This work was supported by a Medical Student Fellowship grant from the American Association of Neurological Surgeons (J.G.M.), a Grace Woodward Grant for Collaborative Research in Engineering and Medicine from Penn State (S.J.S., A.G.W.), and the generosity of the endowment funds of Harvey F. Brush (S.J.S.).

* Drs. Mandell and Hill contributed equally to this work.

THE incidence of temporal lobe epilepsy (TLE) due to mesial temporal sclerosis (MTS) is high in malaria-prone regions of the developing world.^{3,29,30} This is presumably related to damage to the brain from the high incidence of febrile illness in children, especially from the high prevalence of cerebral malaria.^{6,40} Estimates suggest that more than 80% of patients with epilepsy live in developing countries, such as within Sub-Saharan Africa.^{20,30} In industrialized countries, the diagnosis of MTS is performed by using MRI to image the signal changes and reduction in volume of the sclerotic mesial temporal lobe. When concordant with semiology and encephalography (EEG) findings, this has high prognostic value for resection of the deep temporal structures having significant benefit in reducing seizures and improving quality of life.^{4,14,16,23,31,34,35,39} However, most developing countries have limited or no access to MRI. Furthermore, there is no literature suggesting the use of CT as a prognostic indicator for resection.

Evidence from structural MRI suggests that CT could be used as an indicator of hippocampal atrophy. Lee et al. found that the whole temporal lobe, not just the hippocampus, is small in TLE.¹⁷ Moran et al. observed a correlation between the degree of atrophy of extra-hippocampal temporal lobe structures with the atrophy of the hippocampus itself.²² They reported a 13% volume loss for the whole temporal lobe on the ipsilateral side, while the temporal lobe of the contralateral side trended toward subnormality. Finally, McMillan et al. found that gray matter and white matter are affected bilaterally in the brain due to TLE.²¹ Given the widespread impact on extra-hippocampal temporal lobe and brain beyond the temporal lobe associated with TLE, we propose that volumetric analysis of CT could be used in patient selection, as an adjunct to EEG, semiology, and neurocognitive assessment, to predict favorable outcomes following resection.

In this third of the 3 companion papers,^{18,19} we report the measurement of temporal lobe and total brain volumes in 10 pediatric patients treated with temporal lobe resection for TLE at the CURE Children's Hospital of Uganda (CCHU) and previously reported.³ We then used linear discrimination analysis (LDA) to classify seizure outcome by temporal lobe volumes and normalized total brain volumes.

Methods

Epilepsy Patients

A retrospective review of the epilepsy database of the CCHU from 2005 to 2008 was conducted. Institutional review board (IRB) approvals were obtained from CCHU and Penn State. At CCHU, 49 epileptic patients had previously been evaluated with careful histories and physical examination, a modified Edinburgh handedness scale, and long-term video EEG.³ Ten patients with pharmacologically intractable epilepsy (defined as persistent seizures at a rate of more than 1 seizure/month after failure of 2 available anticonvulsants) were offered temporal lobe resection (cortico-amygdalo-hippocampectomy [CAH]). Preoperative CT scans were performed on site at CCHU using a

Siemens Spiral CT to rule out mass lesions or other secondary causes of TLE.

At present there is no validated neuropsychological testing for the languages and culture encountered in East Africa, which is a broader problem for formal neuropsychiatric testing in many regions of the developing world. A modified Mini-Mental State Examination (MMSE)¹³ was therefore administered before surgery, and at 6 and 12 months postsurgery.³ The modifications to the MMSE accounted for cultural norms, language differences, and illiteracy. The MMSE includes simple language and memory testing but is not a full neuropsychiatric evaluation. It is sensitive to the presence of serious cognitive disorders. Normal scores (out of 30) are 27.6 ± 1.7 (range 24–30).¹³ Retest reliability (1 or 2 testers) indicates that less than 5-point discrepancies can be seen in stable patients.¹³ Future validation with formal neuropsychological measures in regions of the developing world will be important to obtain as efforts toward comprehensive epilepsy care expand beyond the borders of the industrialized countries.

All 10 patients underwent resection (CAH) and received standard postoperative care, including inpatient observation at CCHU in the immediate postoperative period and close outpatient follow-up. Postoperative histological analysis confirmed MTS in each case. Seizure occurrence and characteristics were recorded throughout the follow-up period of at least 12 months, postoperative CT was performed, and seizure control at last follow-up was classified with the Engel classification.⁹

CT images were de-identified and labeled with alphanumeric coding with oversight from protocols approved by the IRBs of both Penn State University and CCHU. The de-identified images in DICOM format were then transferred from the CCHU to 3 evaluators (K.L.H., J.G.M., and S.J.S.) for analysis. Preoperative volumes were calculated by investigators blinded for the side of resection.

Normal Subjects

T2-weighted brain MRI data sets were acquired from the NIH Pediatric MRI Data Repository provided by the Montreal Neurological Institute.^{1,37} Normative brain parenchymal volumes (including cerebral hemispheres, cerebellum, and brainstem) and intra-brain fluid volumes (including ventricular fluid and fluid contained within the boundary of the brain parenchyma) were calculated previously from 42 data sets from patients ranging from birth to 18 years of age.¹⁹ In this present study, normative right and left temporal lobe volumes were further calculated using data sets from 3 males and 3 females at 6, 10, 14, and 18 years for a total of 24 additional data sets. Although this is the first database of normal developmental brain anatomy available, it is from a North American population, which may not reflect the population and environmental conditions of this East African population studied here.

Temporal Lobe Volume Analysis

Temporal lobe volumetric analysis of CT and MRI images was conducted using the Cavalieri method (Stereo Investigator, MicroBrightField) on images with slice thickness of 2 mm. A randomly aligned grid with an in-

termarker distance of 2 mm was overlain on the CT and MR images (Fig. 1A and B). Markers within the region of interest were assigned to the right or left temporal lobe or temporal horn of the lateral ventricle (Fig. 1). The Cavalieri method allows for efficient systematic sampling to create both accurate and unbiased volumetric analysis.¹⁵

The inferior margin of the temporal lobe on both MR and CT images was indicated by the first presence of the cerebrum identified in the middle cranial fossa, and the superior border was the level where the sylvian fissure no longer delineated the anterior border of the temporal lobe. Two sets of volumes were calculated for CT images using different landmarks for the posterior margin of the temporal lobe. In the first series, the tentorium cerebelli was used to demarcate the posterior aspect of the temporal lobe, and in images where it was not visible, the poste-

rior border of the collicular plate was used as the posterior margin. In the second series, the floor of the fourth ventricle and the posterior margin of the collicular plate were used as the posterior aspect of the temporal lobe in all images (Fig. 1D and E, Series 1 and 2, respectively). The collicular plate was used as a landmark for both series because of its radiographic correlation with the posterior limit of resection of the medial temporal lobe structures in a typical CAH. In practice, we found that the floor of the fourth ventricle and collicular plate proved to be more reliable landmarks to identify on both CT and MRI images. In addition, we found no statistically significant difference comparing volumetric results from these two series. In the analysis that follows, we report only the results using the floor of the fourth ventricle and collicular plate as the posterior temporal lobe margin.

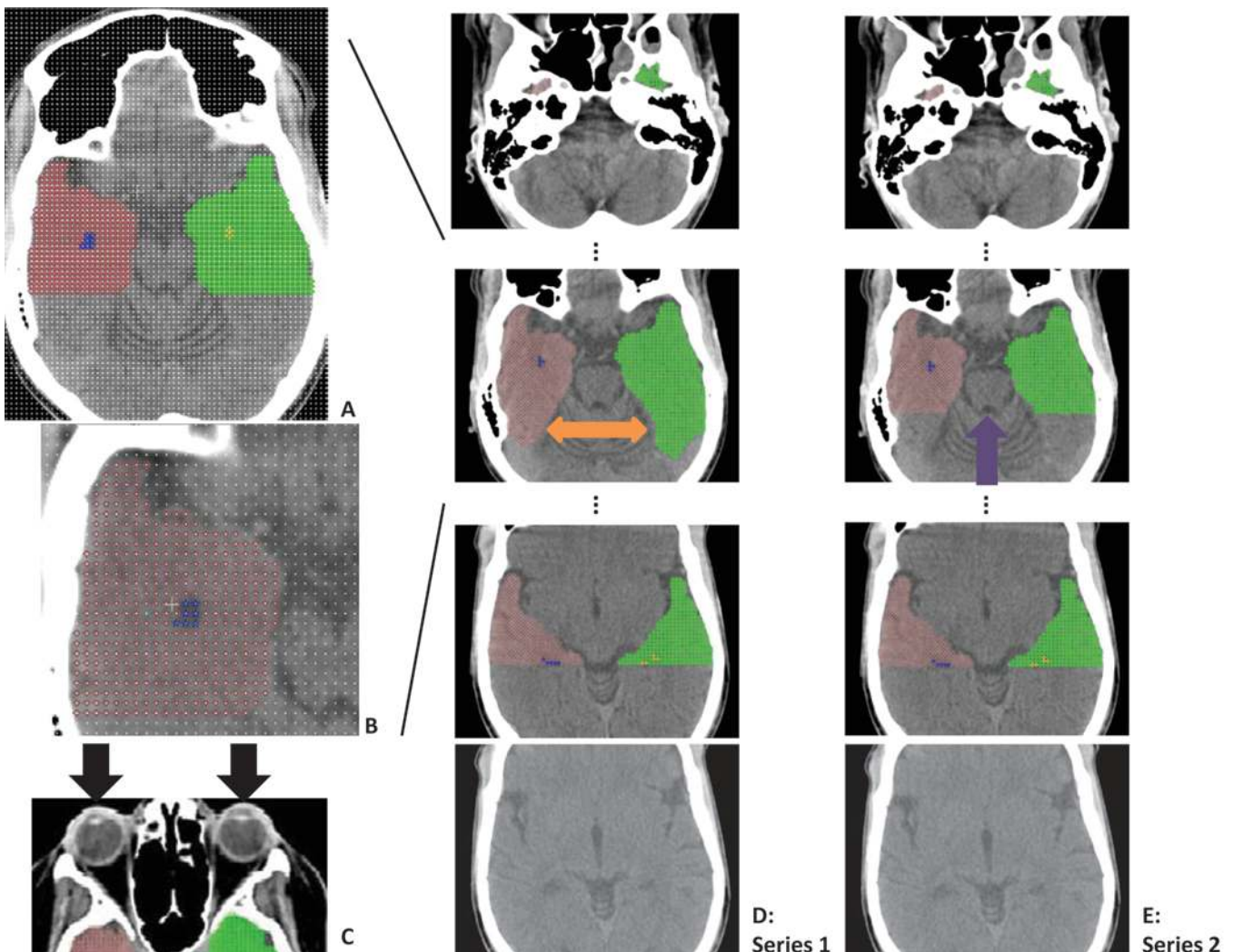


FIG. 1. **A:** Randomly assigned grid with an intermarker distance of 2 mm, whole brain. The temporal lobe and horn areas are indicated in color. **B:** Randomly assigned grid with an intermarker distance of 2 mm. The right temporal lobe and horn area are indicated in color (magnified view). **C:** Representation of proper gantry angle in the CT scanner with both eye lenses captured on the same slice (black arrows). **D:** Series 1. The posterior border of the temporal lobe is the tentorium cerebelli surface when present (double-headed orange arrow) and the posterior margin of the collicular plate when the tentorium cerebelli surface is absent. **E:** Series 2. The posterior border of the temporal lobe is the floor of the fourth ventricle and the posterior margin of the collicular plate (purple arrow). Red indicates right temporal lobe. Green indicates left temporal lobe. Blue indicates right temporal pole CSF of the lateral ventricle. Yellow indicates left temporal pole CSF of the lateral ventricle.

To reduce additional measurement error from head tilt within the CT scanner, we required that 2 sequential images show the presence of the optic lenses bilaterally (Fig. 1C). We performed preliminary analysis requiring 2 mm, 4 mm, or 6 mm of optic lens to be present in the vertical direction. We found that robust results could be shown with the requirement of at least 2 mm of lens overlap in the vertical plane, which led to only 1 patient requiring exclusion for head tilt from ipsilateral and contralateral temporal lobe comparisons. In future prospective studies, attention to such alignment details will be important if, rather than whole brain, the volume of homologous structures are to be measured and compared as suggested by our findings.

Brain and Fluid Volume Analysis

Brain and intra-brain fluid volumes were calculated for the normal subjects using a particle filter image segmentation algorithm for MRI.¹⁹ This same technique for brain and intra-brain fluid volume was used on the CT scans from the Ugandan epilepsy patients. Briefly, this method starts with a pixel classification step to create probability maps of brain and fluid for each slice. Using the probability maps and a user-selected seed point, a particle filter is then used to extract the brain by automatically tracking the outer edge of the brain. Finally, the initial probability maps of brain and fluid are used to segment the extracted brain into brain and intra-brain fluid.

Data Analysis

Linear discrimination analysis (LDA) was originally developed as a method to classify data that had more than 1 measurement (multivariate) and that came from more than 1 group of items.¹¹ LDA calculates the optimal way of combining measurement variables in a linear combination to optimally separate and classify each group. By classification, we mean the ability to separate outcomes into groups. We have refined this method to take into account modern numerical computer algorithms.³³

Seizure outcomes are stratified using the Engel classification,⁹ and optimal seizure control is defined as IA, completely free of seizures following surgery. Less optimal results are less adequate even in the presence of significant seizure improvement.^{29,36} Additionally, in a setting with limited resources without MRI to verify the presence of MTS on the side of resection, CAH outcomes with complete seizure freedom are our strongest quality control with validation of diagnosis and localization.

LDA was used to test the hypothesis that preoperative temporal lobe volumes and age-normalized brain volumes are able to classify postoperative outcomes. Because our patient population included those with both right- and left-sided TLE, we used LDA to compare the volume of the temporal lobe removed (ipsilateral to the seizure focus) to the volume of the temporal lobe to be left in place (contralateral to the seizure focus). Four separate analyses were performed using temporal lobe volumes. The first analysis tested the classification of Engel Class IA patients versus Engel Class IB/IIA/IIB patients. The second analysis compared normal subjects and Engel Class IA patients versus

Engel Class IB/IIA/IIB patients. The third analysis was a 3-way discrimination to compare normal subjects, Engel Class IA patients, and Engel Class IB/IIA/IIB patients. Finally, we use a 3-way discrimination of the above groups classified by normalized brain volume, contralateral temporal lobe volume, and pathological temporal lobe volume.

The Wilks test statistic, W , was used to test for the significance of the classification.¹² This likelihood ratio tests the null hypothesis, H_0 , that each group mean, μ_k , is equal

$$H_0 : \mu_1 = \mu_2 = \dots = \mu_k \quad [\text{Eq. 1}]$$

The Wilks statistic is also used to test random combinations of regrouped data with a bootstrapping method.^{8,12,33} The bootstrap method tests whether the grouping defined prior to the LDA is unlikely to have occurred by chance. The W statistic for each permutation of the data are compared with the W statistic for the originally classified data. The bootstrap probability, P_b , is the probability that the original classification would occur randomly and is given by

$$P_b = \frac{N_{less} + 1}{N_{perm} + 1} \quad [\text{Eq. 2}]$$

where N_{less} is the number of groupings with a W statistic less than or equal to the original W statistic, and N_{perm} is the number of permutations. This calculation includes the original grouping as one of the permutations in addition to those performed in the bootstrapping, thus 1 is added to N_{less} and N_{perm} in equation 2.

Results

Nine preoperative noncontrast and 1 preoperative contrast-enhanced CT scans were obtained for analysis from CCHU. The presence of contrast made the boundaries of the temporal lobe easier to identify in some regions, but this was not essential for selection of landmarks. The patient group included 10 patients (7 female and 3 male). Eight patients had left-sided temporal lobe epilepsy (TLE) and 2 had right-sided TLE. Age at the time of surgery ranged from 13 to 21 years. The Engel classification of seizure control at last follow-up is recorded in Table 1. Total brain and intra-brain fluid volume was calculated for the 7 patients whose CT study was from skull base to vertex.

Of the 10 patients who underwent surgery, there were 7 whose MMSE scores were stable or increased at the 6- and 12-month follow-up assessment, and 3 whose scores decreased (Table 1). The patients whose retest scores differed by at least 4 points included 2 whose scores improved (Cases 5 and 8), and 2 whose scores declined (Cases 7 and 9). One of the patients whose MMSE score decreased was in the Engel Class IA outcome group, but this decrease in score was not seen on the 6-month, but rather the 12-month follow-up examination (noted in Boling et al.³), and therefore was not likely to be directly related to surgery. The other decline was seen in a patient with Class IIIA/B outcome and continued seizure activity. Other causes of such significant declines on MMSE include depression, affective disorders, and drug use.

TABLE 1. Summary of patients' demographic and clinical characteristics and results of surgery

Case No.	Age at Op (yrs), Sex	Age at Sz Onset (yrs)	EEG	Preop MMSE*	Op	Follow-Up (mos)	Postop MMSE* & Timing	Outcome†	Volume Measurements (cm ³)			
									Rt Temp Lobe	Lt Temp Lobe	Rt Temp Horn CSF	Lt Temp Horn CSF
1	14, F	3	Rt TLE	20	Rt CAH	12	20 at 6 mos	IIB	31.6	32.8	0.38	0.02
2	16, F	2	Rt TLE	13	Rt CAH	12	12 at 6 mos	IB	32.7	36.6	0.29	0.16
3	16, F	9	Lt TLE	30	Lt CAH	12	30 at 6 mos	IB	27.5	35.6	0.10	0.13
4	13, F	8	Lt TLE	27	Lt CAH	14	28 at 8 mos	IA	42.8	44.7	0.23	0.12
5	14, M	—‡	Lt TLE	22	Lt CAH	12	29 at 6 mos, 29 at 12 mos	IA	45.1	37.1	0.42	0.48
6	21, F	5	Lt TLE	28	Lt CAH	31	29 at 6 mos, 30 at 12 mos	IIB	34.2	49.3	0.16	0.18
7	15, F	2	Lt TLE	22	Lt CAH	25	21 at 6 mos, 17 at 12 mos	IIIA/B	32.6	42.8	0.20	0.13
8	18, F	1	Lt TLE	21	Lt CAH	23	21 at 6 mos, 25 at 12 mos	IIB	25.2	25.4	0.02	0.001
9	18, M	10	Lt TLE	28, 29	Lt CAH	12	28 at 6 mos	IA	36.2	25.1	0.28	0.35
10	13, M	2	Lt TLE	23	Lt CAH	17	23 at 13 mos	IA	36.7	27.6	0.14	0.10

CAH = cortico-amygdalo-hippocampectomy; Sz = seizure; Temp = temporal.

* A modified version of the MMSE was used; scores are out of a possible 30 points.

† Engel grade.

‡ Since childhood.

Temporal Lobe and Temporal Horn Volumes

Average values were calculated for temporal lobe and temporal horn CSF volumes for the 10 epilepsy patients. The mean volumes for the right temporal lobe, left temporal lobe, right temporal horn CSF, and left temporal horn CSF were 36.8, 35.3, 0.28, and 0.19 cm³, respectively.

Temporal Lobe Volumes Comparison

Temporal lobe volume asymmetry in patients with right and left TLE was compared directly, independent of patient age. In patients with right TLE, the right versus left temporal lobe volume ratio was 0.94. In patients with left TLE, the left versus right temporal lobe volume ratio was 1.05. These values are not significantly different from the normal right versus left temporal lobe volume ratio of 1.03 (p = 0.30) and the normal left versus right ratio of 0.99 (p = 0.36). This ratio was not a predictor of the clinically determined side of seizure focus.

Temporal Horn Volume Comparison

Enlarged temporal horn size was previously noted as a potentially localizing sign on pneumoencephalography in patients with TLE.²⁸ In the present study, we compared temporal horn volumetric asymmetry in patients with right and left TLE directly, independent of patient age. In patients with right TLE, the right versus left temporal horn ratio was 2.5. In patients with left TLE, the left versus right temporal horn volume was 0.76. Again, these values are not substantially different from the normal right versus left temporal horn ratio of 1.61 (p = 0.23) and left versus right temporal horn ratio of 0.79 (p = 0.88). This ratio was not a predictor of the clinically determined side of seizure focus.

Ratio Comparison

A ratio comparison of the temporal horn ventricular volume to the temporal lobe volume was calculated for left and right sides in patients with left TLE and right TLE to evaluate the degree of volumetric asymmetry. This was not a predictor of the clinically determined side of seizure focus.

Volumetric Analysis

Normative growth curves of brain volume were calculated previously¹⁹ using T2-weighted brain MRI data sets from the National Institutes of Health (NIH) Pediatric MRI Data Repository provided by the Montreal Neurological Institute.^{1,37} The whole brain volumes of 7 of the TLE patients from Uganda are plotted with the normative curve in Fig. 2. Note that the normative curve was calculated for North American child development, which may differ from normative growth of the rural Ugandan child. The male Ugandan epilepsy patients show normal-to-small brain volumes. One of the female patients had a brain volume on the high end of normal, while brain volumes in the rest were normal to small compared with the control population.

Volumes of right and left temporal lobes for North American control subjects and Ugandan epilepsy patients are shown in Fig. 3. Right (squares) and left (triangles) temporal lobe volumes of epilepsy patients (solid shapes) are smaller than the control at each age comparison. Note that seizure-free patients (Engel IA, green) had contralateral (right TLE patients outlined in black) temporal lobes that were either close to normal volume or were substantially larger than the ipsilateral resected temporal lobes.

Normative ratios of right temporal lobe to left temporal lobe volumes for male, female, and combined are shown

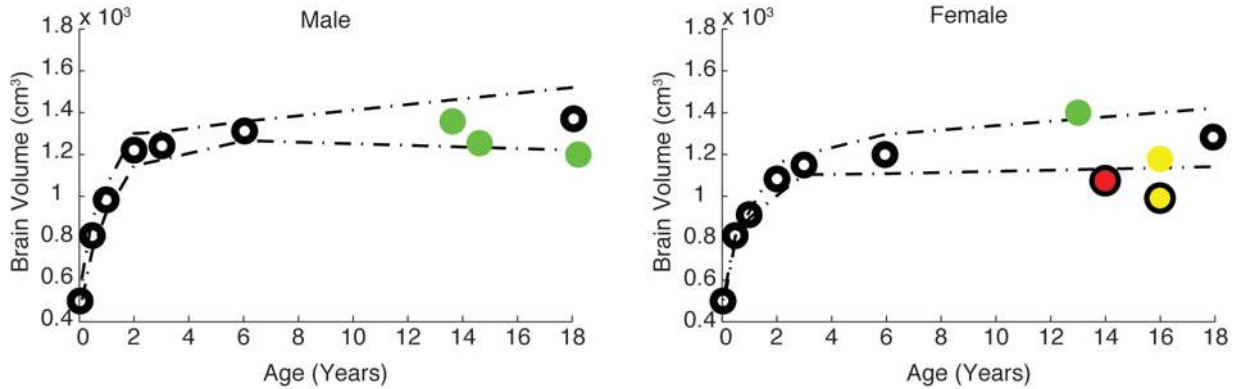


FIG. 2. Brain volumes of 7 Ugandan epilepsy patients (colored circles) plotted on normative growth curves for male (left) and female (right) North American children and adolescents. The normal means are indicated by open black circles and the dashed lines represent ± 1 SD. The colors show Engel classification of seizure outcome: green represents Class IA, yellow Class IB, and red Class IIB. Colored circles with a black outline represent brain volumes of patients with right-sided TLE. Colored circles without a black outline represent brain volumes of patients with left-sided TLE. Three patients (6, 7, and 8 from Table 1) had incomplete scans and whole brain volumes could not be calculated.

in Table 2 for ages 6, 10, 14, and 18 years. The ratios of the temporal lobe volumes of the remaining temporal lobe to the resected temporal lobe are shown in Fig. 4. In 3 of 4 patients with Engel IA outcome, this ratio is larger than in the control group for that age. In all of the patients with Engel IB and IIB outcomes, this ratio ranges from normal to small in comparison with the control values. The optimal discrimination line, comparing IA to IB and IIB cases, is shown as the dashed line.

After obtaining these normative data ratios, we sought to improve our classification based on lobar volumes by employing a multivariate classifier, employing both the volume of the lobe to be removed and the volume of the lobe to be retained. We hypothesized that even when the lobes are both affected by the process that caused epilepsy, the degree of excess shrinkage and asymmetry in the candidate resection lobe would correlate more directly with seizure outcome.

LDA was used to separate the seizure-free group (Engel IA) from groups with less adequate outcomes (Engel IB and IIB). This made the case outcomes significantly

discriminable ($W = 0.29$, $p < 0.01$), as can be seen in Fig. 5. The bootstrap probability demonstrates a 2.8% chance that this classification of data was obtained by chance. Note that the discrimination plot in Fig. 5 demonstrates that the volume of the lobe to be retained contains the most substantial amount of the clinically predictive information. Small size of the lobe to be retained indicates potential pathology in this lobe, and likely elsewhere in the brain, in an epileptic patient. Such pathological evidence outside of the resection site should correlate with non-seizure-free outcomes. LDA was also performed after control subjects were grouped with the Engel IA patients. The data were also discriminable in this way ($W = 0.46$, $p < 0.01$), with a highly significant bootstrap probability ($p < 0.001$, Fig. 6). A 3-way analysis to separate patients with Engel IA outcomes, those with Engel IB/IIB outcomes, and normal subjects was also highly discriminable ($W = 0.29$, $p < 0.01$), with a bootstrap probability of 0.1% that this classification was obtained by chance (Fig. 7). To further test the integrity of our findings, we subjected these results to a leave-one-out analysis, eliminating each

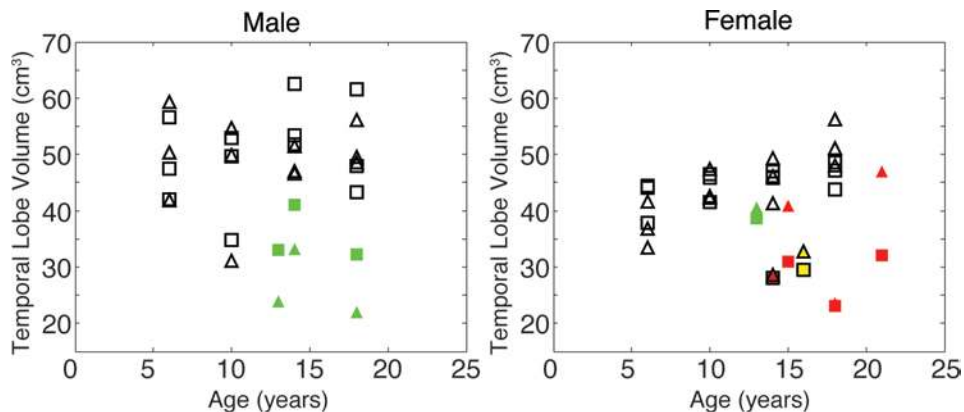


FIG. 3. Temporal lobe volumes of epilepsy patients and normal subjects for males (left) and females (right). The normal subjects are shown with open black shapes. The right temporal lobes are shown with squares and the left temporal lobes are triangles. The colors show Engel classification with Class IA as green, Class IB as yellow, and Class IIB as red. The markers for patients with right-sided surgery are outlined in black. Patient 3 (Table 1) was excluded from lobar comparisons due to excessive head tilt on CT.

TABLE 2. Average normative values of the ratio of right temporal lobe volume to left temporal lobe volume shown by age and sex

Age	Male	Female	Both Sexes
6	0.97	1.14	1.06
10	1.03	1.03	1.03
14	1.15	1.02	1.09
18	0.99	0.90	0.94
All ages	1.04	1.02	1.03

individual's data in turn when training the discriminator, and testing whether that individual's classification would be correct.^{12,33} Such cross-validation revealed an 18.2% error rate for classification of individuals, consistent with the significant population-based Wilks and bootstrap results. Finally, we show a 3-way discrimination comparing the above groups, classifying results by a combination of normalized total brain volume, contralateral temporal lobe volume, and pathological temporal lobe volume (Fig. 8). This analysis is also highly discriminable ($W = 0.23$, $p < 0.01$), with a bootstrap probability of 0.3% that the results were obtained by chance. It should be noted that only 4 patients with an Engel Class IA outcome and 2 patients with Class IB/IIB outcome had CT scans covering the entire brain while satisfying the head tilt requirement. Therefore, these were the only patients who could be included in these latter results (and a leave-one-out analysis would not be feasible). Because this analysis classifies the data with 3 measurements instead of 2, we plotted the results in 2D space using the canonical linear discriminants z_1 and z_2 . These are optimal linear combinations of the original 3 variables.

Discussion

Mesial temporal sclerosis (MTS) is the most common form of temporal lobe epilepsy (TLE) and partial epilepsy,^{2,4,25,34} and it is also the most frequent indication for surgery in adults with TLE.^{2,4,5,10,28,34,38,39} Diagnosis of MTS requires structural MRI and has high prognostic value for predicting whether a temporal lobe resection will reduce seizures and improve quality of life.^{4,13,16,23,31,34,35,39} However, many areas of the world with the highest prevalence of TLE^{3,30} have no or limited access to MRI. With the increased number of surgical epilepsy programs with access to CT in the developing world,^{3,7,24,26} it is important to be able to use CT as a tool to aid in patient selection and evaluation for surgery.^{18,19} In this study, we present data suggesting that temporal lobe and brain volumes measured on CT scans might be useful to discriminate seizure outcome following temporal lobe resection.

Figure 3 shows a comparison of temporal lobe volumes by age. Those patients who maintained a seizure-free outcome had retained temporal lobes that were either substantially larger than the resected temporal lobe or close to normal in size. Those who had IB and IIB outcomes all had small retained temporal lobe volumes, regardless of the volume of the resected side. Nevertheless, a univariate analysis of the ratio of temporal lobe volumes alone was not sufficient to predict seizure outcome (Fig. 4).

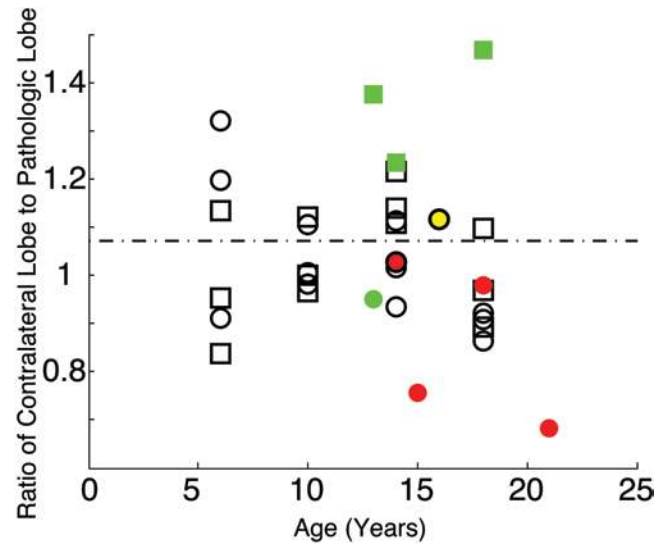


FIG. 4. Ratio of the volume of the contralateral temporal lobe to the volume of the pathological temporal lobe. Cases involving males are shown as squares and those involving females as circles. Data from normal subjects (open black shapes) are represented as a ratio of right side to left side. Class IA outcomes are shown in green, Class IB in yellow, and Class IIB in red, with the symbols representing patients with right-sided TLE outlined in black. The dashed line represents the discrimination line as calculated by LDA comparing Class IA outcomes with Class IB and IIB outcomes.

A multivariate measure taking each lobe independently into account was necessary to demonstrate significant discrimination to predict seizure outcome (Figs. 5–7). We show discrimination of seizure outcome alone (Fig. 5) and also included normal subjects (Fig. 6). Figure 7 shows that by measuring each lobe individually, it is not only possible to discriminate seizure outcome, but it is also possible to discriminate normal subjects from those with TLE. These results are consistent with previous work that found that TLE leads to a reduction of the entire temporal lobe volume on both the ipsilateral and contralateral sides of the seizure focus.^{17,22} Our findings are also consistent with clinical judgment that outcomes are best when the lobe to be resected is substantially atrophied and the lobe to be retained is normal. Therefore, our findings regarding whole lobe and brain volumes may be applicable not only to CT images in developing countries but also for surgery evaluation with MRI in the industrialized world.

Figure 8 discriminates normal, Class IA outcome, and Class IB/IIB outcomes by normalized total brain volume, contralateral temporal lobe volume, and pathological temporal lobe volume. This plot shows that including total brain volume in addition to temporal lobe volumes gives a strong predictor of seizure outcome. We see that in Fig. 2, a smaller brain tends to lead to a poorer outcome. Additionally, of the patients with Class IA outcome, the patient with the smallest brain volume had the largest contralateral temporal lobe. Also, the only patient with a Class IA outcome who had a larger pathological temporal lobe than contralateral lobe also had the largest brain volume. Although the numbers in this study are small, brain volume appeared to be clearly of significance in clinical outcome in these patients. Measuring total brain volume along with

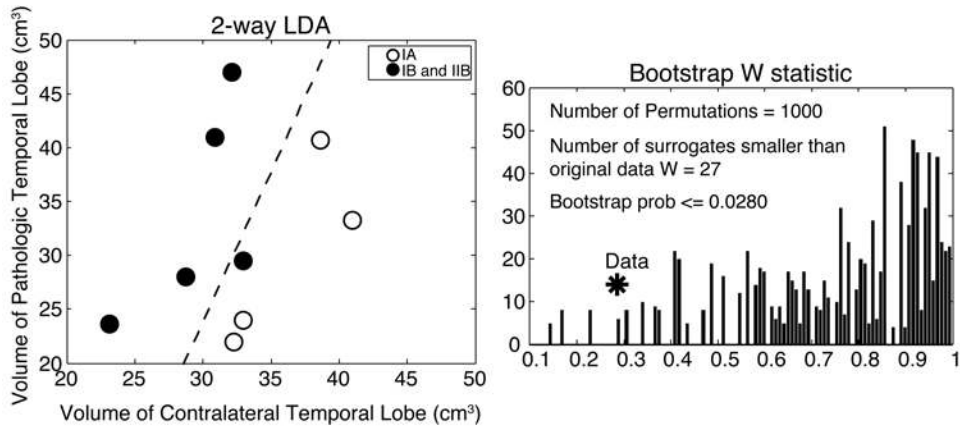


FIG. 5. Left: Fisher’s LDA (left) was used to separate seizure-free outcomes (Engel Class IA) from poor outcomes (Engel Class IB and IIB) by using the volumes of the contralateral temporal lobe and the volume of the pathological temporal lobe. The *dashed line* is the discrimination line. Discrimination is significant ($W = 0.2945$, $p < 0.01$). **Right:** Histogram of the W statistic for random regroupings of the data ($p < 0.028$) showing use of the bootstrap method. prob = probability.

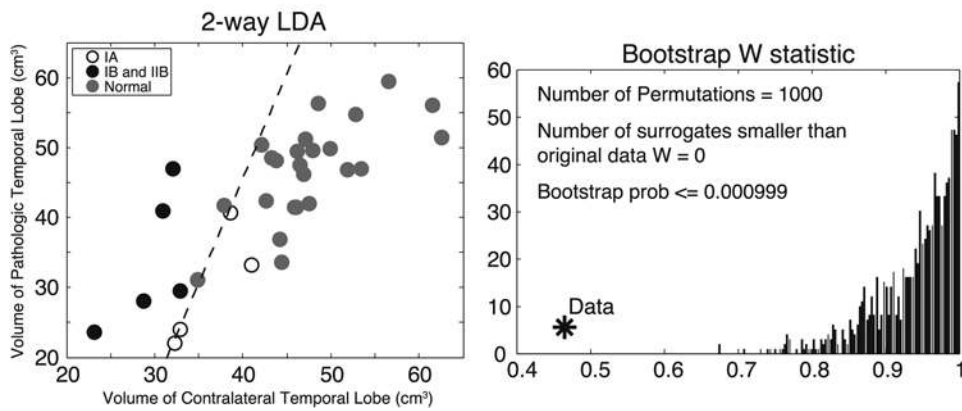


FIG. 6. Left: LDA separating 2 groups: 1) normal subjects and patients with Class IA outcomes and 2) patients with Class IB and Class IA outcomes. The normal subjects are grouped with the patients with Class IA outcomes in this discrimination, assigning the right lobe as contralateral in the normals. The separation was discriminable ($W = 0.4641$, $p < 0.01$). **Right:** Application of the bootstrap method for the classification of these data ($p < 0.001$).

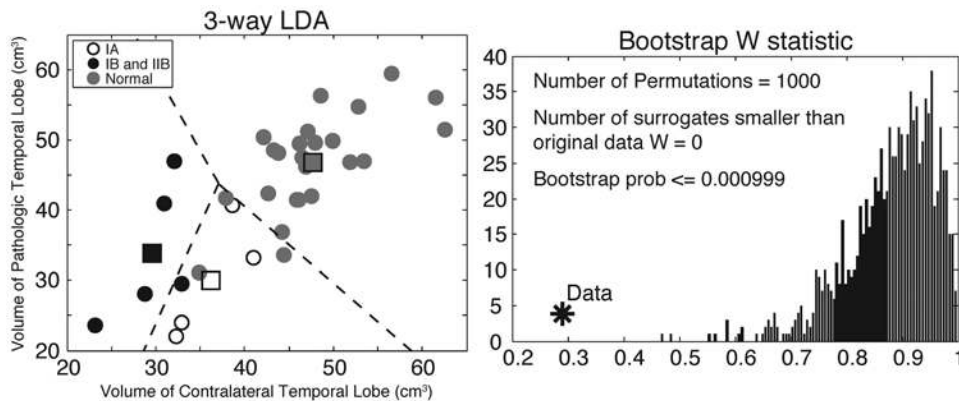


FIG. 7. Left: 3-way LDA comparing Class IA versus Class IB/IIB versus normal. The *squares* are the means of each group and the *dotted line* is the discrimination line. The separation was significantly discriminable ($W = 0.2899$, $p < 0.01$). **Right:** Application of the bootstrap method for the classification of the data ($p < 0.001$).

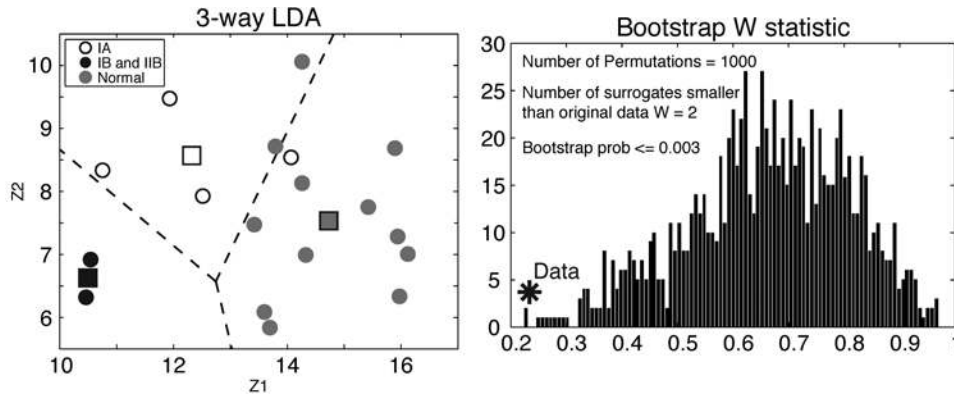


FIG. 8. **Left:** 3-way LDA comparing Class IA versus Class IB/IIB versus normal ($W = 0.23$, $p < 0.01$). This discrimination uses a combination of normalized total brain volume, contralateral temporal lobe volume, and pathological temporal lobe volume. The squares are the means of each group. This is plotted in 2D space using the canonical linear discriminants z_1 and z_2 , which are the optimal linear combinations of the original 3 variables. **Right:** Application of the bootstrap method for the classification of the data ($p = 0.003$).

temporal lobe volumes is a logical independent measure to use in predicting seizure outcome. These results show promising inference toward using these measurements in future studies.

Although this study was focused on seizure outcomes, the MMSE results demonstrated stable or improved scores in 8 of 10 patients. A study using more sophisticated neuropsychological assessment focusing on language and memory function is needed to further characterize the correlations of volumetric assessment with cognitive function in temporal lobectomy.

We expect that temporal lobe and brain asymmetry, as illustrated in Fig. 9, are critical in the evaluation of TLE. Previous reports show that it is possible to have unilateral or bilateral damage to the temporal lobes, as well as unilateral or bilateral damage to the cerebral hemispheres with unilateral TLE.^{17,21,22} It is important to understand the brain volumes in this study within this context. Patients with substantial damage confined to the temporal lobe on one side only should fare best following surgery (Fig. 9B). Indeed, patients with a contralateral temporal lobe that was substantially larger than the ipsilateral temporal lobe tended to be seizure free. Bilateral temporal lobe atrophy, regardless of cerebral hemisphere involvement (Fig. 9C and E), is less likely to predict a good outcome of temporal lobe resection due to the increased possibility of a contralateral ictal source in a retained damaged temporal lobe. If we measure temporal lobe volumes in TLE as a univariate ratio, the conditions shown in panels A, C and E of Fig. 9 will all yield similar ratios. We see that such ratios in Fig. 4 do not discriminate outcome well. However, as shown in Fig. 7, when we measure absolute temporal lobe volumes individually, we can discriminate the normal subjects represented in Fig. 9 (Fig. 9A) from patients with a unilateral atrophy (Fig. 9B and D) and patients with bilateral atrophy (Fig. 9C and E). Additionally, our data suggest that total normalized brain volume may play an important role in seizure outcome, enabling us to detect patterns, as in Fig. 9D and E. In future work, we suggest that with larger numbers of patients it would be helpful to measure cerebral hemisphere asymmetry in addition to temporal lobe

asymmetry to better explore the impact of brain volume on seizure outcome.

Conclusions

In this retrospective analysis, we show evidence that temporal lobe volumes as measured by CT or MRI can be predictive of seizure outcome following temporal lobe resection in patients with TLE. We suggest the feasibility of substituting hippocampal atrophy as measured on MRI with volumetric analysis of the temporal lobe and brain using CT when MRI is not available. Furthermore, since our methods are modality independent, temporal lobe and brain volumes may be useful in our selection of patients for temporal lobe resection when structural MRI is available. Determination of normative data on temporal lobe

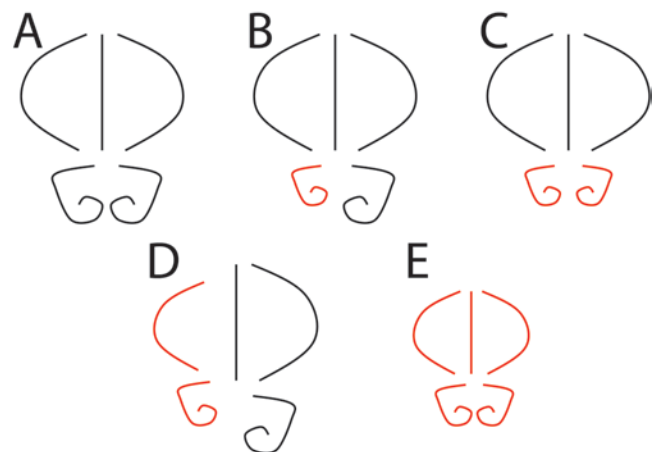


FIG. 9. Brain symmetry as represented by schematics of cerebral hemispheres and temporal lobes. **A:** A brain with normal cerebral hemisphere volume and normal temporal lobe volume. **B:** Unilateral damage to the temporal lobe. **C:** Bilateral temporal lobe damage, with normal cerebral hemisphere volumes. **D:** Unilateral atrophy in both the temporal lobe and the rest of the ipsilateral cerebral hemisphere. **E:** Bilateral damage throughout the cerebral hemispheres.

volumes and asymmetry, as well as evaluation of the predictive value of temporal lobe volumes in addition to total brain volume, await further study in a larger population.

References

- Almli CR, Rivkin MJ, McKinstry RC: The NIH MRI study of normal brain development (Objective-2): newborns, infants, toddlers, and preschoolers. **Neuroimage** **35**:308–325, 2007
- Araújo D, Santos AC, Velasco TR, Wichert-Ana L, Terra-Bustamante VC, Alexandre V Jr, et al: Volumetric evidence of bilateral damage in unilateral mesial temporal lobe epilepsy. **Epilepsia** **47**:1354–1359, 2006
- Boling W, Palade A, Wabulya A, Longoni N, Warf B, Nestor S, et al: Surgery for pharmacoresistant epilepsy in the developing world: a pilot study. **Epilepsia** **50**:1256–1261, 2009
- Caboclo LO, Garzon E, Oliveira PA, Carrete H Jr, Centeno RS, Bianchin MM, et al: Correlation between temporal pole MRI abnormalities and surface ictal EEG patterns in patients with unilateral mesial temporal lobe epilepsy. **Seizure** **16**:8–16, 2007
- Cascino GD, Jack CR Jr, Parisi JE, Sharbrough FW, Hirschorn KA, Meyer FB, et al: Magnetic resonance imaging-based volume studies in temporal lobe epilepsy: pathological correlations. **Ann Neurol** **30**:31–36, 1991
- Cendes F, Andermann F, Gloor P, Lopes-Cendes I, Andermann E, Melanson D, et al: Atrophy of mesial structures in patients with temporal lobe epilepsy: cause or consequence of repeated seizures? **Ann Neurol** **34**:795–801, 1993
- Donadío M, D’Giano C, Moussalli M, Barrios L, Ugarnes G, Segalovich M, et al: Epilepsy surgery in Argentina: long-term results in a comprehensive epilepsy centre. **Seizure** **20**:442–445, 2011
- Efron B, Tibshirani RJ: **An Introduction to the Bootstrap. Monographs on Statistics and Applied Probability 57.** New York: Chapman & Hall/CRC, 1993
- Engel J: **Surgical Treatment of the Epilepsies.** New York: Raven Press, 1987
- Eriksson SH, Thom M, Symms MR, Focke NK, Martinian L, Sisodiya SM, et al: Cortical neuronal loss and hippocampal sclerosis are not detected by voxel-based morphometry in individual epilepsy surgery patients. **Hum Brain Mapp** **30**:3351–3360, 2009
- Fisher RA: The use of multiple measurements in taxonomic problems. **Ann Eugen** **7**:179–188, 1936
- Flury B: **A First Course in Multivariate Statistics.** New York: Springer, 1997
- Folstein MF, Folstein SE, McHugh PR: “Mini-mental state.” A practical method for grading the cognitive state of patients for the clinician. **J Psychiatr Res** **12**:189–198, 1975
- Gonçalves Pereira PM, Oliveira E, Rosado P: Relative localizing value of amygdalo-hippocampal MR biometry in temporal lobe epilepsy. **Epilepsy Res** **69**:147–164, 2006
- Gundersen HJ, Jensen EB: The efficiency of systematic sampling in stereology and its prediction. **J Microsc** **147**:229–263, 1987
- Kan P, Van Orman C, Kestle JR: Outcomes after surgery for focal epilepsy in children. **Childs Nerv Syst** **24**:587–591, 2008
- Lee JW, Reutens DC, Dubeau F, Evans A, Andermann F: Morphometry in temporal lobe epilepsy. **Magn Reson Imaging** **13**:1073–1080, 1995
- Mandell JG, Kulkarni AV, Warf BC, Schiff SJ: Volumetric brain analysis in neurosurgery: Part 2. Brain and CSF volumes discriminate neurocognitive outcomes in hydrocephalus. **J Neurosurg Pediatr** [epub ahead of print November 28, 2014. DOI: 10.3171/2014.9.PEDS12427]
- Mandell JG, Langelan JW, Webb AG, Schiff SJ: Volumetric brain analysis in neurosurgery: Part 1. Particle filter segmentation of brain and cerebrospinal fluid growth dynamics from MRI and CT images. **J Neurosurg Pediatr** [epub ahead of print November 28, 2014. DOI: 10.3171/2014.9.PEDS12426]
- Mbuba CK, Ngugi AK, Newton CR, Carter JA: The epilepsy treatment gap in developing countries: a systematic review of the magnitude, causes, and intervention strategies. **Epilepsia** **49**:1491–1503, 2008
- McMillan AB, Hermann BP, Johnson SC, Hansen RR, Seidenberg M, Meyerand ME: Voxel-based morphometry of unilateral temporal lobe epilepsy reveals abnormalities in cerebral white matter. **Neuroimage** **23**:167–174, 2004
- Moran NF, Lemieux L, Kitchen ND, Fish DR, Shorvon SD: Extrahippocampal temporal lobe atrophy in temporal lobe epilepsy and mesial temporal sclerosis. **Brain** **124**:167–175, 2001
- Moran NF, Lemieux L, Maudgil D, Kitchen ND, Fish DR, Shorvon SD: Analysis of temporal lobe resections in MR images. **Epilepsia** **40**:1077–1084, 1999
- Mrabet Khiari H, Khemiri E, Parain D, Hattab N, Proust F, Mrabet A: Epilepsy surgery program in Tunisia: an example of a Tunisian French collaboration. **Seizure** **19**:74–78, 2010
- Mueller SG, Laxer KD, Barakos J, Cheong I, Garcia P, Weiner MW: Widespread neocortical abnormalities in temporal lobe epilepsy with and without mesial sclerosis. **Neuroimage** **46**:353–359, 2009
- Murthy JM, Yangala R: Etiological spectrum of localization-related epilepsies in childhood and the need for CT scan in children with partial seizures with no obvious causation—a study from south India. **J Trop Pediatr** **46**:202–206, 2000
- Natsume J, Bernasconi N, Andermann F, Bernasconi A: MRI volumetry of the thalamus in temporal, extratemporal, and idiopathic generalized epilepsy. **Neurology** **60**:1296–1300, 2003
- Olivier A, Boling WW, Tanriverdi T: **Techniques in Epilepsy Surgery: The MNI Approach.** Cambridge UK: Cambridge University Press, 2012
- Poochikian-Sarkissian S, Sidani S, Wennberg R, Devins GM: Seizure freedom reduces illness intrusiveness and improves quality of life in epilepsy. **Can J Neurol Sci** **35**:280–286, 2008
- Preux PM, Druet-Cabanac M: Epidemiology and aetiology of epilepsy in sub-Saharan Africa. **Lancet Neurol** **4**:21–31, 2005
- Régis J, Bartolomei F, Rey M, Hayashi M, Chauvel P, Peragut JC: Gamma knife surgery for mesial temporal lobe epilepsy. **J Neurosurg** **93 Suppl 3**:141–146, 2000
- Rwiza HT, Kilonzo GP, Haule J, Matuja WB, Mteza I, Mbena P, et al: Prevalence and incidence of epilepsy in Ulanga, a rural Tanzanian district: a community-based study. **Epilepsia** **33**:1051–1056, 1992
- Schiff SJ, Sauer T, Kumar R, Weinstein SL: Neuronal spatio-temporal pattern discrimination: the dynamical evolution of seizures. **Neuroimage** **28**:1043–1055, 2005
- Schmidek HH, Roberts DW (eds): **Schmidek & Sweet Operative Neurosurgical Techniques: Indications, Methods, and Results, ed 5.** Philadelphia: WB Saunders, 2005
- Sperling MR, Feldman H, Kinman J, Liporace JD, O’Connor MJ: Seizure control and mortality in epilepsy. **Ann Neurol** **46**:45–50, 1999
- Télliez-Zenteno JF, Wiebe S: Long-term seizure and psychosocial outcomes of epilepsy surgery. **Curr Treat Options Neurol** **10**:253–259, 2008
- Waber DP, De Moor C, Forbes PW, Almli CR, Botteron KN, Leonard G, et al: The NIH MRI study of normal brain development: performance of a population based sample of healthy children aged 6 to 18 years on a neuropsychological battery. **J Int Neuropsychol Soc** **13**:729–746, 2007
- Watson C, Cendes F, Fuerst D, Dubeau F, Williamson B, Evans A, et al: Specificity of volumetric magnetic resonance

- imaging in detecting hippocampal sclerosis. **Arch Neurol** **54**:67–73, 1997
39. Wiebe S, Blume WT, Girvin JP, Eliasziw M: A randomized, controlled trial of surgery for temporal-lobe epilepsy. **N Engl J Med** **345**:311–318, 2001
 40. Wu WC, Huang CC, Chung HW, Liou M, Hsueh CJ, Lee CS, et al: Hippocampal alterations in children with temporal lobe epilepsy with or without a history of febrile convulsions: evaluations with MR volumetry and proton MR spectroscopy. **AJNR Am J Neuroradiol** **26**:1270–1275, 2005

Warf. Administrative/technical/material support: Schiff, Warf. Study supervision: Schiff, Warf.

Supplemental Information

Previous Presentation

Portions of this work were submitted for an oral presentation for the 41st Annual Meeting of the AANS/CNS Section on Pediatric Neurological Surgery, November 27–30, 2012, in St. Louis, Missouri.

Companion Papers

Mandell JG, Langelaan JW, Webb AG, Schiff SJ: Volumetric brain analysis in neurosurgery: Part 1. Particle filter segmentation of brain and cerebrospinal fluid growth dynamics from MRI and CT images. DOI: 10.3171/2014.9.PEDS12426.

Mandell JG, Kulkarni AV, Warf BC, Schiff SJ: Volumetric brain analysis in neurosurgery: Part 2. Brain and CSF volumes discriminate neurocognitive outcomes in hydrocephalus. DOI: 10.3171/2014.9.PEDS12427.

Correspondence

Steven J. Schiff, W311 Millennium Science Complex, Pollock Rd., University Park, PA 16802-2131. email: sschiff@psu.edu.

Author Contributions

Conception and design: Schiff, Mandell, Hill, Nguyen, Moser, Harbaugh, McInerney, Johnson, Warf, Boling, Webb. Acquisition of data: Schiff, Mandell, Hill, Nguyen, Moser, Harbaugh, McInerney, Nsubuga, Mugamba, Johnson, Warf, Boling. Analysis and interpretation of data: Schiff, Mandell, Hill, Nguyen, Moser, Harbaugh, McInerney, Warf, Boling. Drafting the article: Schiff, Mandell, Hill, Warf. Critically revising the article: all authors. Reviewed submitted version of manuscript: all authors. Approved the final version of the manuscript on behalf of all authors: Schiff. Statistical analysis: Schiff, Mandell, Hill,