
Wavelet Image Fusion Approach for Classification of Ultrasound Placenta Complicated by Gestational Diabetes Mellitus

G. Malathi and V. Shanthy

Additional information is available at the end of the chapter

<http://dx.doi.org/10.5772/53530>

1. Introduction

The steady increase in population correspondingly increases the number of diseases people are prone to. The early diagnosis of a disease is of paramount importance, which is a major challenge faced by the medical experts. Health information, especially, clinical information increases on a daily basis and is extremely variable and is also complicate to assess. As a result, there is a demand for finding the criteria that can be used to evaluate the quality of hidden information. One of the most important problems of medical diagnosis, in general, is the subjectivity of the specialist. All these factors have resulted in the use of computers to assist the experts in their diagnosis.

Computer assisted information retrieval may assist to support quality decision making and avoid human error. Although human decision-making is often optimal, it is poor when huge amounts of data are involved for classification. Computer Aided Diagnosis (CAD) is a fast growing research field that has set a new horizon in the medical domain. It has increased the quality of current medical imaging technologies by bringing in new developments in medical imaging technology. CAD has already been successfully implemented for a number of medical problems which includes cancer, fractures etc. Even though CAD software's were developed for uncovering many diseases like microcalcification in mammograms, chest, colon, brain, liver, skeletal and vascular systems, is lacking application to ultrasound obstetrics and gynecology domain.

The human placenta is a fetus's lifeline during gestation, providing nutrients and antibodies, while eliminating waste products via the mother's blood supply. The placenta is an integral part of the child's development, but is generally disposed of, after delivery. The relatively new field of placenta analysis within the field of prenatal pathology investigates

the possibility of learning important health information about the fetus from the placenta. The general opinion on the placenta is its use in the exaction of stem cells. Beyond that the placenta holds vital information that can contribute to clinical practice and the growth of the fetus in the womb. The placenta is connected to the uterine wall and exchanges nutrients and waste through the placental blood barrier. The Figure 1 represents the human placenta [1] during the pregnancy.

Gestational Diabetes or Gestational Diabetes Mellitus (GDM) is a condition in which women without previously diagnosed diabetes exhibit high blood glucose levels during pregnancy.

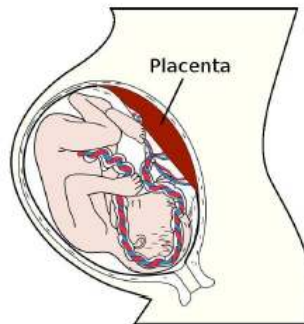

Figure 1. Placenta and fetus during pregnancy

About 80% of the diabetes [2-3] in the world will be present in developing countries like India. India accounts for the largest number of people, about 50.8 million [4] suffering from diabetes in the world, followed by China with about 43.2 million and the United States with 26.8 million, as per the new figures released by the International Diabetes Federation in the year 2009. As per the reports of World Health Organization [5], the number of diabetics throughout the world was 171 million in the year 2000 and expected to reach 350 million by 2030. The diagnosis of GDM is an important public health issue. Gestational diabetes is much more common than pre-existing [6] diabetes as it complicates about 2-5% of pregnancies.

Gestational diabetes is formally defined as “any degree of glucose intolerance with onset or first recognition during pregnancy”. Gestational diabetes is caused when the body of a pregnant women does not secrete excess insulin [7] required during pregnancy leading to increased sugar levels. This definition acknowledges the possibility that patients may have previously undiagnosed diabetes mellitus or may have developed diabetes [8] coincidentally with pregnancy. Babies born to mothers with gestational diabetes are typically at increased risk of problems such as being large for gestational age.

A random survey by a team of doctors under Dr.V.Seshiah (Diabetes Care and Research Institute) showed [9] a statistics (2002) that about 16.2% of pregnant women in Chennai were found to have GDM.

Screening examinations during pregnancy are an essential part of prenatal care. Among the various screening tests that are now offered to pregnant women, ultrasound has the broadest diagnostic spectrum. There is no modality that can detect as many abnormalities [10] throughout pregnancy as ultrasound. Another important advantage of ultrasound is its low cost. Besides the early detection of a nonviable pregnancy ultrasound at the end of the first trimester can detect gross fetal anomalies or at least show initial signs that are suggestive of complications. The examination of the placenta appears to be treated with less attention than the fetus or the pregnant uterus. A methodical sonographic evaluation of the placenta plays a foremost role in the assessment of normal and abnormal pregnancies.

There are different ways in which the ultrasound [11] technology can be used in pregnancy related diagnosis.

- Abdominal ultrasound: Abdominal Ultrasound is the most common used in pregnancy related diagnosis. In this ultrasound the sonologists moves the transducer over the abdomen to scan the uterus and examine the development of the baby and several other conditions of the uterus. This research uses ultrasound images of placenta obtained by abdominal scan.
- Vaginal Ultrasound: In vaginal ultrasound, a sterilized probe is gently placed in the vagina but outside the cervix. The probe is covered with a thin plastic sheath. This technique helps sonologists to minutely observe the women's uterus.
- Doppler Ultrasound: Doppler ultrasound is used to examine the blood flow in the vessels. This technique is performed in the same way as abdominal ultrasound.

Placental development is a complex process of various coordinated differentiation steps that are mostly completed at the end of the second trimester. Thereafter, placental growth is predominantly characterized by mass expansion. Thus, development of placenta precedes fetal development and growth, the latter being pronounced in the third trimester. Any increase of the diabetes in maternal environment during the critical period of placental differentiation during the first and second trimester, introduces changes in the placenta morphology which has a profound effect on subsequent fetal growth and this is the focus point of this research. The human placenta undergoes a number of structural [12] changes which ultimately will facilitate the development of the fetus. A novel study [13] conducted in Tamil Nadu by a team of doctors in the year 2012 suggested the screening of pregnant women for gestational diabetes as early as at 16 weeks of gestation.

The number of women affected [14-15] by GDM is 3 to 10% of pregnancies. Certain factors that contribute to placental abruption [16] are women having gestational diabetes and preeclampsia. The miscarriages of 44% and neural tube defects occur thirteen to twenty times more frequently in diabetic [15] pregnancy.

Placental volumes vary in dimensions depending on the ethnic backgrounds of women universally. Taking into consideration of this vital factor, the present study focuses on the Dravidian race, a sub-division of the great Negroid race. The Caucasian, Mongoloid and Australoid races exhibit different qualities of placental characteristics and are beyond the scope of the present research.

The need of this study is to evaluate the effect of GDM on the development of placental growth. Diabetic pregnancy shows increase in the size of the placenta. This affects the growth of the fetus, which may even lead to death if untreated. The evaluation of the volume of placenta at fifteen to twenty weeks of gestation can identify placenta complicated by diabetes mellitus. This would help to diagnose complications at the earliest, which would minimize the loss, birth defects and placenta abruption. Considering the placenta, size alone may be sufficient to identify a subset of women at a higher risk in the initial ultrasound examination. An increase or decrease in the size of the placenta is a strong indication to an approaching complication in the placenta. The gestational age can be prolonged only if the problem in the placenta is identified in the initial phases of pregnancy.

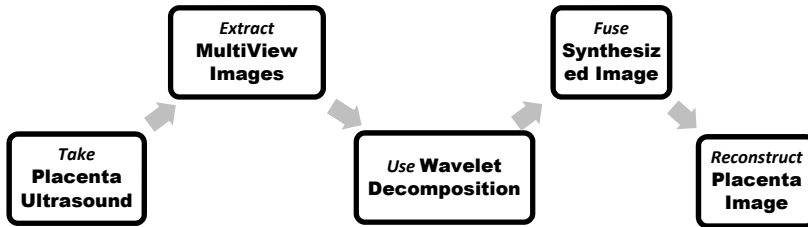


Figure 2. Approach to Decompose and Reconstruct the Fused Ultrasound Placenta from Multi-View Image Fusion

The ultrasound images of placenta obtained from the B-mode ultrasound scanner is usually low in resolution. The characteristic feature of the placenta, which plays an important role in classification, is lost because of poor resolution. There is a need for a technique to retain the finer details of the placenta in the ultrasound. In this research, the multi-view placenta images (transverse scans of placenta ultrasound images captured at the right and left of the monitor) are subjected to wavelet decomposition. The essential attribute of the ultrasound placenta is retained, when wavelet-decomposition is employed, since it is an efficient tool to extract the features of an image. When an ultrasound placenta is subjected to wavelet decomposition, the image is decomposed into different frequencies. The prominent features in these frequencies are fused into a synthesized image.

2. Why prefer wavelet?

Any decomposition of an image into wavelets involves a pair of waveforms. These represent the high frequencies corresponding to the detailed parts of an image called as wavelet function. The other represent low frequencies or smooth parts of an image called scaling function. The principle of the wavelet decomposition is to transform the original raw image into several components with single low-resolution component called “approximation” and the other components called “details” as shown in Figure 3. The approximation component is obtained after applying bi-orthogonal low-pass wavelet in each direction i.e. horizontal and vertical followed by a sub-sampling of each image by a factor of two for each dimension

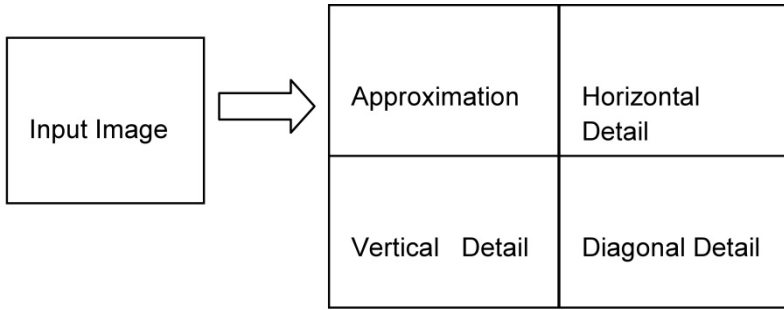


Figure 3. Wavelet Decomposition of a 2D Image

The details are obtained with the application of low-pass filter in one direction and a high-pass in the other or a high-pass in both the directions. The noise is mainly present in the details components. A higher level of decomposition is obtained by repeating the same operations on the approximation. For small details it is not obvious to a non-expert in the diagnosis of ultrasound images to know what is needed to eliminate or to preserve and enhance.

The horizontal edges of the original image are present in the horizontal detail coefficients of the upper-right quadrant. The vertical edges of the image can be similarly identified in the vertical detail coefficients of the lower-left quadrant. To combine this information into a single edge image, we simply zero the approximation coefficients of the generated transform. Compute the inverse of it and obtain the absolute value.

The images are considered to be matrices with N rows and M columns. At every level of decomposition the horizontal data is filtered, and then the approximation and details produced from this are filtered on columns. At every level, four sub images are obtained, the approximation, the vertical detail, the horizontal detail and the diagonal detail. The next level of decomposition can be obtained by the decomposition of approximation sub-image. The multilevel decomposition of an image is given in Figure 4.

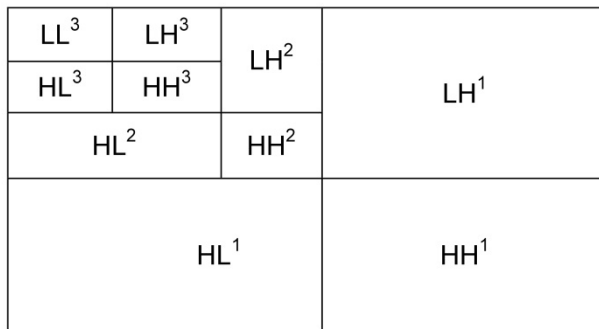


Figure 4. Multilevel Wavelet Decomposition of an Image

2.1. Choice of mother wavelet

The choice of wavelet bases depends on the signal. Signals coming from different sources have different characteristics. The wavelet basis functions are obtained from a single mother wavelet by translation and scaling. However, there is no single or universal mother wavelet function. The mother wavelet must simply satisfy a small set of conditions and is typically selected based on the domain of the signal or image processing problem. The best choices of wavelet bases are not clear for ultrasound placenta images. The problem is to represent typical signals with a small number of convenient computable functions. An investigation to choose the best wavelet for ultrasound images was performed on ultrasound placenta image. The majority of the wavelet bases which exist in the Matlab 7 version software were tested. The Haar wavelet is chosen for the decomposition of ultrasound placenta images. Higher levels of decomposition showed promising diagnostic features of the ultrasound placenta image.

2.2. Haar wavelet decomposition of ultrasound placenta

Haar wavelet basis can be used to represent an image by computing a wavelet transform. The pixel is averaged together pair-wise and is calculated to obtain the new resolution image with pixel values. Some information may be lost in the averaging process. The Haar wavelet transform is used to analyze images effectively and efficiently at various resolutions. It is used to get the approximation coefficients and detail coefficients at various levels.

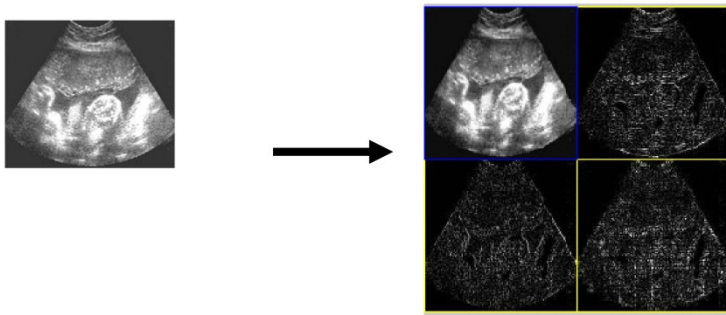


Figure 5. Level-1 Haar Wavelet Decomposition of an ultrasound placenta image

The ultrasound images of placenta with various gestational ages like 10 weeks, 12 weeks, 15 weeks, 17 weeks, and greater than 20 weeks are obtained from Chennai based Diagnostic Scan Centers. The placenta images thus obtained are demarcated into a normal placenta and GDM complicated placenta with the help of the sonologists. These images are then subjected to different levels of wavelet decomposition using different wavelets. The transverse scans of placenta are captured with differences of few seconds from the same mother. The multi-view ultrasound placenta is subjected to various levels (1, 2, 3 and 4) of wavelet decomposition. The synthesized image of the input image is obtained as a result. This synthesized image only forms the basis to image fusion in the sections that follows. The

decomposition is done to extract the useful features from the multiview placenta. Still, these images cannot be used unless a quality assessment is done. To ensure the diagnostic accuracy of the images, quality evaluation metrics are used to evaluate the performance of the wavelets. The following Figure 5 is the representation of level-1 decomposition of ultrasound placenta using Haar.

Each of the transverse and longitudinal scans of the ultrasound placenta image is decomposed into approximate, horizontal, vertical and diagonal details. N levels of decomposition can be done. Here, 4-levels of decomposition are used. The multilevel decomposition of ultrasound placenta using Haar Wavelet is represented in the Figure 6. After that, quantization is done on the decomposed image where different quantization may be done on different components thus maximizing the amount of required details and ignoring the redundant details. In order to decide the most appropriate wavelet function for the ultrasound placenta, the image is decomposed using various wavelet functions. The wavelet function is chosen based on the results of image fusion quality measures.

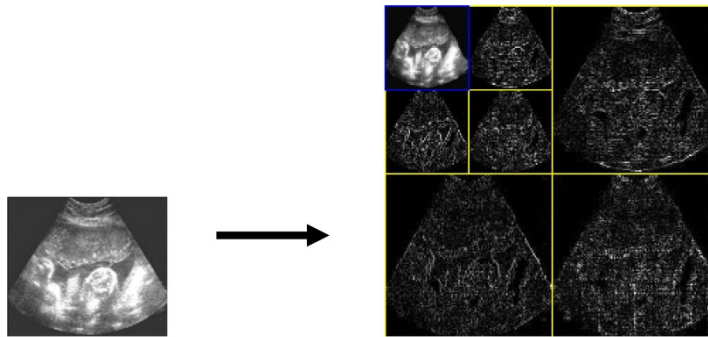


Figure 6. Multilevel Decomposition of Ultrasound Placenta using Haar Wavelet

The Figure 7 gives the synthesized ultrasound images of placenta obtained from Haar, Daubechies and Symlet wavelet decomposition. The Haar wavelet is chosen in this research because of its good entropy and mutual information. However, the fact that they have jump discontinuities in particular in the poorly decaying Haar coefficients of smooth functions and the images reconstructed from subsets of the Haar coefficients.

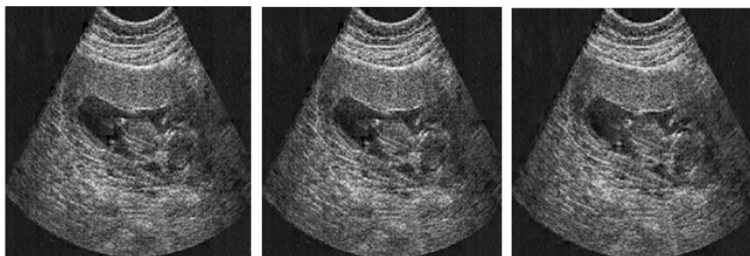

Figure 7. Images from left to right is the synthesized image of placenta obtained from Haar, Daubechies and Symlet Wavelet Decomposition (15 weeks gestational age)

The quality of the image decomposed by different wavelets at various gestational ages is compared in the tables below. The Entropy, Normalized Cross Correlation, Structural Content, Spatial Frequency and Fusion Mutual Information is used as the quality measure in choosing the best wavelet for the characterizing the ultrasound placenta both normal and placenta complicated by GDM. Each has its importance in evaluating the image quality. The entropy of the synthesized image shows an increase in value when, the image is decomposed using Haar Wavelet, compared to the original input images. The measure of structural content of the image is low in the case of Haar. At every level of decomposition, Haar shows good performance in uniquely identifying the features of the placenta. The structural consent is more in the case of Daubechies. The image decomposed using Haar wavelet shows improved quality as the decomposition level increases. In the initial levels, the wavelets, Daubechies, Haar and Symlet show negligible variations in the results. It is also to be noted that placenta with GDM complications are identified by it high entropy when compared to the normal placenta.

The below Table 1 gives the quality evaluation metrics to identify the wavelet, that is suitable for the assessment of ultrasound placenta. Moreover, these metrics shows values with fewer differences between the gestational ages. As the gestational age increases, the metrics also increases.

Wavelet	PSNR	MSE	RMSE	STD	MEAN	Entropy	Class
Haar	33.5101	28.9784	5.3832	43.1958	112.3084	7.4205	Normal
Daubechies	33.4174	29.6035	5.4409	43.054	112.2816	7.3155	
Symlet	33.2889	30.4926	5.522	42.1112	106.5676	7.382	
Haar	33.5476	28.729	5.3599	42.4914	106.5915	7.4491	GDM
Daubechies	34.4057	23.5781	4.8557	42.4914	106.6384	7.3894	
Symlet	33.4628	29.2956	5.4125	44.1209	111.89	7.3894	

The values of PSNR, MSE, RMSE, STD, MEAN, ENTROPY which is recorded in the Table 1, Table 2, Table 3, Table 4 and Table 5 is obtained.

Table 1. Quality Evaluation Metrics to evaluate the performance of Wavelets on normal vs. GDM Ultrasound placenta at 10 weeks of Gestational Age

Wavelet	PSNR	MSE	RMSE	STD	MEAN	Entropy	Class
Haar	33.7862	27.1932	5.2147	63.8662	121.8244	7.4258	Normal
Daubechies	33.6108	28.314	5.3211	63.8403	121.89	7.43	
Symlet	33.5692	28.5864	5.3466	63.803	124.0667	7.4248	
Haar	34.7943	21.5602	4.6433	73.4038	135.7681	7.5319	GDM
Daubechies	34.3782	23.7282	4.8712	73.4146	135.752	7.4496	
Symlet	34.5592	22.7595	4.7707	73.3531	135.7031	7.5122	

Table 2. Quality Evaluation Metrics to evaluate the performance of Wavelets on normal vs. GDM Ultrasound placenta at 12 weeks of Gestational Age

As per the results of the Table 1 and Table 2, the values shows only feeble difference between the normal and the placenta complicated by GDM and also between the Wavelets. At the higher gestational ages as referred in Table 3 and Table 4, there is a distinct demarcation between normal and GDM complication placenta images. Of all these wavelets, Haar shows a remarkable distinction between these features.

The performance of wavelet decomposition of placenta images taken at 15 weeks of gestational Age is shown in Table 3. This gives the metrics that is used to evaluate the normal and GDM Ultrasound placenta.

Wavelet	PSNR	MSE	RMSE	STD	MEAN	Entropy	Class
Haar	34.2999	24.1594	4.9152	34.3881	52.8156	6.5333	Normal
Daubechies	34.0404	25.647	5.0643	34.415	52.9848	6.5404	
Symlet	34.1473	25.0236	5.0024	34.3965	52.7567	6.5357	
Haar	35.6885	17.5481	4.189	32.974	52.3329	6.8749	GDM
Daubechies	35.167	19.7872	4.4483	34.9113	51.5043	6.8435	
Symlet	34.8374	21.3474	4.6203	34.9392	51.4704	6.8632	

The placenta complicated by GDM records higher values when compared to normal. This is clearly indicated in Tables 2, 3, 4 and 5.

Table 3. Quality Evaluation Metrics to evaluate the performance of Wavelets on normal vs. GDM Ultrasound placenta at 15 weeks of Gestational Age

Wavelet	PSNR	MSE	RMSE	STD	MEAN	Entropy	Class
Haar	36.33	15.1383	3.8908	22.5818	45.9544	6.0968	Normal
Daubechies	35.8815	16.7853	4.097	24.6532	55.2264	6.0799	
Symlet	36.115	15.9067	3.9883	24.6608	55.0351	6.0962	
Haar	36.6246	14.1456	3.7611	24.6962	55.074	6.4061	GDM
Daubechies	36.1327	15.8419	3.9802	22.5477	46.0005	6.4017	
Symlet	36.3917	14.9249	3.8633	22.4784	46.2704	6.4053	

Table 4. Quality Evaluation Metrics to evaluate the performance of Wavelets on normal vs. GDM Ultrasound placenta at 17 weeks of Gestational Age

Wavelet	PSNR	MSE	RMSE	STD	MEAN	Entropy	Class
Haar	37.0174	12.9222	3.5948	62.3357	93.3318	6.5345	Normal
Daubechies	35.895	16.7333	4.0906	62.3794	94.6397	6.6267	
Symlet	35.5165	18.2571	4.2728	62.4018	94.7556	6.6428	
Haar	40.2942	6.0766	2.4651	59.9116	94.1953	6.5826	GDM
Daubechies	39.7736	6.8505	2.6173	59.918	94.2794	6.5709	
Symlet	38.8101	8.5521	2.9244	60.005	94.0674	6.6186	

Table 5. Quality Evaluation Metrics to evaluate the performance of Wavelets on normal vs. GDM Ultrasound placenta greater than 20 weeks of Gestational Age

It is clear from the numbers in Table 1 and that the image obtained from Haar Wavelet decomposition performs better than the Daubechies and Symlet decomposition. However, the quality of the input image remains the same irrespective of the decomposition techniques. The high entropy is the indication of the good quality of the image. From the values in Table 6 it can be seen that the wavelet decomposition using Haar dominated the Daubechies and Symlet as indicated by high PSNR of multiview image.

Table 6 suggests that at the higher level of decomposition Haar wavelet gives best results. As the decomposition levels increase the performance of Daubechies and Symlet also increase. It has more or less showed similar results at the first level of decomposition. The entropy of the image considerably increased as the levels improved as in Table 7. At the highest level of decomposition Haar performs better that the other wavelets.

Levels of Decomposition	Haar	Daubechies	Symlet
Level 1	34.4689	33.4174	33.2889
Level 2	36.6246	35.8815	35.6885
Level 3	39.7736	37.0174	36.1357
Level 4	40.3112	39.8702	38.8101

Table 6. PSNR of the different wavelet fused Image at various decomposition levels

Levels of Decomposition	Haar	Daubechies	Symlet
Level 1	6.0799	6.0594	6.0321
Level 2	6.5709	6.4017	6.6267
Level 3	6.6428	6.4674	6.4016
Level 4	7.4491	6.5709	6.5345

Table 7. Entropy of the different wavelet fused Image at various decomposition levels

The results clearly imply that Haar Wavelet yields good quality image at the higher levels of decomposition. The ultrasound images of placenta are then reconstructed using image fusion and it is used to study the complications rendered by GDM on the growth of the placenta.

The low frequency coefficients reflect the approximate feature of the image. It contains the main outline information of the image. It is an approximate image of the original image at certain dimensions. Most of the information and energy of the image is included in this. The high frequency coefficients reflect the detail of the luminance change which corresponds to the edge information of an image. It is important to keep the edge information and the outline information of the input image in the fused image. The fusion should preserve the detail information like high frequency and give prominence to the outline information in the target image. The two images must be of the same size and color map.

3. Wavelet image fusion by max approximation and mean detail

The images decomposed using wavelet techniques are then fused with the original image using min, max and mean fusion techniques. After the fused image is generated, it is processed further and some features of interest are extracted.

In wavelet image fusion scheme, the source images $I_1(x, y)$ and $I_2(x, y)$ are decomposed into approximation and detailed coefficients at required level using Haar Wavelet. The approximation and detailed coefficients of both images are combined using fusion rule. The fused image $I_f(x, y)$ is obtained by taking the inverse wavelet transform. The fusion rule used in this research obtains the maximum of the approximation coefficients and finds the mean of the detailed coefficient in each sub-band with the largest magnitude. Thus using different techniques like mean, max, min approximation and details, fused image is obtained. The inverse 2D wavelet transform is used to reconstruct the image from sub images $I_{LL}(x, y), I_{LH}(x, y), I_{HL}(x, y)$ and $I_{HH}(x, y)$. The Figure 9 show the images fused using the fusion rule (a)Max Max (b) Max Min (c) Max Mean (d) Min Max (e) Min Min (f)Min Mean (g) Mean Max (h) Mean Min (i) Mean Mean approximation and detail of a fetus with the Gestational Age as 15 weeks.

$$I_f(x, y) = \text{fusion rule} \{WT(I_1(x, y)), WT(I_2(x, y))\}$$

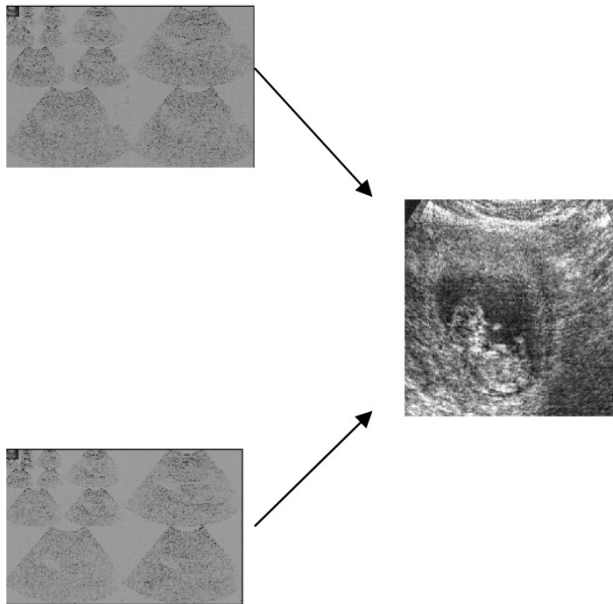


Figure 8. Image Fusion of Wavelet Decomposed Ultrasound Placenta using Max Approximation and Mean Detail

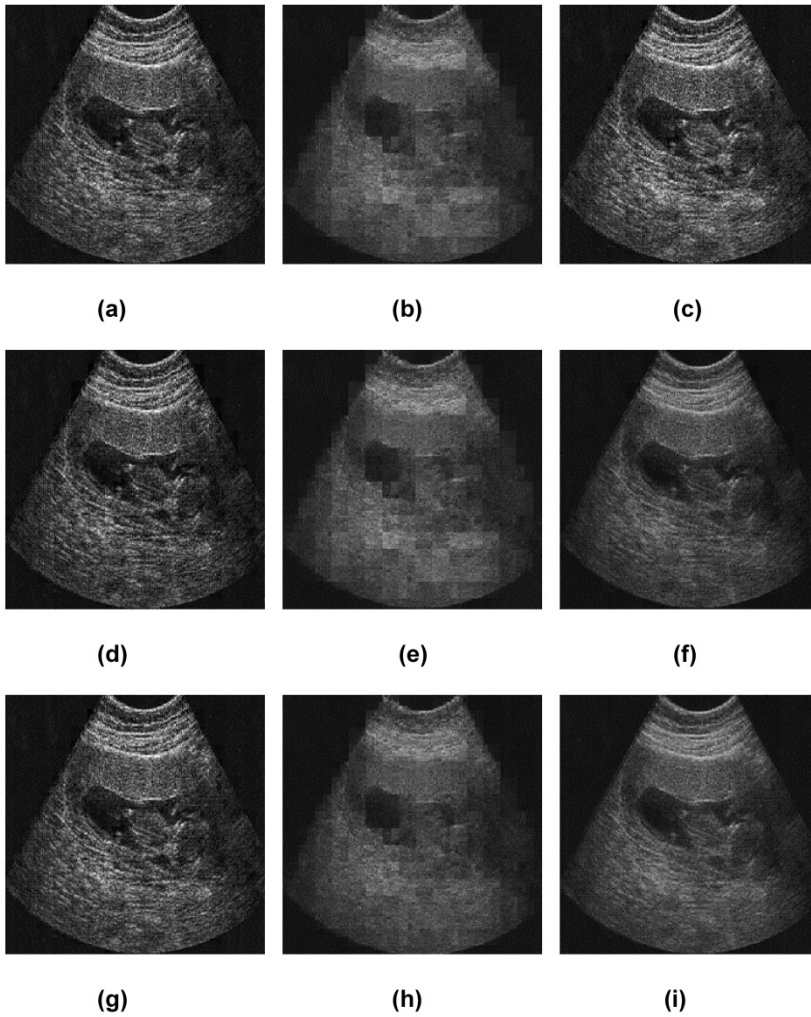


Figure 9. Image fused using the fusion rule (a) Max Max (b) Max Min (c) Max Mean (d) Min Max (e) Min Min (f) Min Mean (g) Mean Max (h) Mean Min (i) Mean Mean approximation and detail of 15 weeks of Gestational Age

4. Diagnostic accuracy evaluation of fused ultrasound placenta

In the case of medical images, it is important to reproduce the image close to the original image so that the smallest of the details are readable.

This research used image quality measures like Entropy, Mean, Standard Deviation, Fusion Mutual Information, Normalized Cross Correlation, Root Mean Square Error, Structural content, Normalized Absolute Error and Absolute Difference to analyze on the fused image.

Though the fusion methods produced varieties of images, few fusion rules only produced images suitable for diagnostic accuracy. A useful image is identified on the execution of quality measures on these images. The quality measures obtained for the images fused with different fusion rules is recorded in Table 8 and Table 9. The values for PSNR, RMSE, NAE, NCC, SC, FMI, ENT, MEAN, STD and AD recorded in Tables 8 and 9 are obtained. The PSNR value obtained for Max Mean Fusion Rule performed well compared to other fusion rule followed by Min Mean. The recording to the table 8 and 9 shows Max Mean with lower RMSE value indicating the closeness of the fused image to the original image. Similar is the NAE results. The quality measure NCC shows good performance of Mean Max followed by Max Max. The structural Content ranks Max Max as good fusion rule followed by Max Min, Min Mean and then Max Mean. The values depicted in Tables 8 and 9 shows that Max Mean as the best quality image which shows high FMI and Entropy. These indicate the richness of information. The Mean and STD play only a less role in the selection of fusion rule for the fused ultrasound placenta image. Again AD shows Max Mean fused image to be cleaner than the other rules. It clearly shows that the wavelet decomposed images when subjected to image fusion increases the quality of information in an image. Thus the essential features, that characterizes the placenta can be extracted. It preserves boundary information and structural details without introducing any other inconsistencies to the image. This work suggests that Max Approximation and Mean Detail fusion rule produces good quality ultrasound placenta complicated by GDM followed by Max Approximation and Max Detail fusion rule.

Fusion Rule		PSNR	RMSE	NAE	NCC	SC
Approximation	Detail					
Max	Max	38.2766	3.1096	0.121	1.008	0.9548
Max	Min	39.5058	2.6993	0.0893	1.0065	0.9702
Max	Mean	40.9709	2.2803	0.0637	1.0066	0.9782
Min	Max	39.3109	2.7605	0.0951	0.9941	0.9923
Min	Min	39.7844	2.6141	0.0819	0.991	1.0023
Min	Mean	40.5563	2.3918	0.071	0.9914	1.0062
Mean	Max	38.9197	2.8877	0.1013	1.0083	0.9616
Mean	Min	39.5153	2.6964	0.089	0.9991	0.9842
Mean	Mean	40.253	2.4768	0.0747	1.0052	0.9774

Table 8. Evaluation of fusion rules based on Image Quality Measures PSNR, RMSE, NAE, NCC and SC

The pelvic ultrasound image taken during the first and second trimester of pregnancy shows the fetus, placenta and the cervix. It is essential to segment the region of interest, which is the placenta, from the ultrasound. The wavelet decomposed placenta ultrasound is segmented to extract the area of focus, placenta. The statistical measures to estimate the volume of the placenta, are obtained from this segmented placenta ultrasound. The relevant image features are then extracted from the segmented placenta. Neural Network is an efficient tool that can capture and represent complex input and output relationship. The reconstructed placenta ultrasound is later classified as either normal placenta or abnormal placenta, using the extracted features.

Fusion Rule		FMI	ENT	MEAN	STD	AD
Approximation	Detail					
Max	Max	38.2766	3.1096	0.121	1.008	-0.5526
Max	Min	39.5058	2.6993	0.0893	1.0065	-0.4963
Max	Mean	40.9709	2.2803	0.0637	1.0066	-0.8875
Min	Max	39.3109	2.7605	0.0951	0.9941	0.0208
Min	Min	39.7844	2.6141	0.0819	0.991	-0.3151
Min	Mean	40.5563	2.3918	0.071	0.9914	0.0022
Mean	Max	38.9197	2.8877	0.1013	1.0083	-0.4466

Table 9. Evaluation of fusion rules based on Image Quality Measures FMI, ENT, MEAN and STD

The present research also evaluates the influence of GDM on adverse outcomes of pregnancy by an estimation of volume of the placenta during the early stages of pregnancy. During the course of pregnancy, ultrasound screenings are done in early pregnancy which is from six to fourteen weeks of gestation. The mid pregnancy is from fourteen to twenty six weeks of gestation. The late pregnancy is from twenty six to forty weeks of gestation. In the later stages of gestation, the fetus in the uterus hides the placenta and therefore makes it difficult to get it captured in the ultrasound. The focus of this research is the ultrasound placenta with 10 weeks, 15 weeks, 17 weeks and more than 20 weeks as the gestational age. The placenta needs to be screened in the initial stages, which can avoid miscarriages due to GDM. The standard common obstetric diagnostic mode is 2D scanning. The estimation of placental volume is not a regular practice in the case of 2D ultrasound. The results of the work have effectively identified the changes in the ultrasound placenta under diabetic conditions.

The findings of the research are that the Haralick features extraction showed significant characteristics of abnormal placenta. Energy, entropy, contrast, homogeneity and correlation features are often used among the 14 Haralick texture features to reveal certain properties about the spatial distribution of the texture image. Since real textures usually have so many different dimensions, these texture properties are not independent of each other. For instance, the energy measure generated from gray level co-occurrence matrix is also known as homogeneity and variance is a measure of contrast in images. Therefore, when choosing a subset of meaningful features from gray level co-occurrence matrix for a particular application, features do not have to be independent because a subset of fully independent features is usually hard to find. These features played an important role in the identification of abnormal placenta. It is found that there is an increase in classification accuracy when placenta ultrasound is subjected to wavelet decomposition and image fusion.

The Haralick features which are obtained from the ultrasound images are recorded in the following Table 10. This table shows the discriminating features that aid in the classification of normal placenta and placenta complicated by gestational diabetes mellitus. The features Mean, Contrast, Correlation, Entropy recorded in the Table 10

Images	Mean	Contrast	Correlation	Entropy	Sum of squares	Class
Img1	1.635 e4	1310473767	7.922339e5	8.944150e4	7.2	AN
Img2	1.832 e4	1614852030	2.978678e6	1.047565e5	1.1	AN
Img3	1.454 e4	1434646325	1.911394e5	9.609855e4	5.6	AN(GDM)
Img4	1.455 e4	1436691775	1.915322e5	9.670916e4	1.0	AN
Img5	1.222 e4	1077321331	1.055089e5	7.347292e4	1.2	N
Img6	1.832 e4	1614852030	2.978678e6	1.047565e5	2.5	AN
Img7	1.854 e4	1647605895	9.059511e5	7.575653e4	1.7	AN
Img8	1.749 e4	1531849951	7.756140e5	9.824614e4	2.15	AN
Img9	1.263 e4	1083142018	1.065980e5	7.3943192e4	1.2	N
Img10	1.280 e4	1067278301	1.059341e5	7.367722e4	1.14	N

Table 10. Haralick Features for Ultrasound Placenta Images for sample images

The Haralick features that were extracted from the wavelet fused ultrasound placenta, highlights on the characteristic features of the input image. These features form the basis for effective classification of placenta whether it is normal or complicated by gestational diabetes mellitus.

Image segmentation refers to the process of partitioning of an image into groups of pixels which are homogeneous with respect to some criterion. Segmentation algorithms have a limited application in ultrasound image. The presence of high levels of speckling in ultrasound images makes accurate segmentation difficult. The region of interest is typically obtained through manual interaction. The original gray-scale image is first converted to binary image using optimal global image threshold. Next the image complement is defined. Image transform using the watershed method should be applied to a matrix after its proper preprocessing to obtain the best image objects contours. The segmented image is obtained using the watershed segmentation method. It starts with a pixel or a group of pixels called seeds that belong to the structure of interest. Seeds are chosen by the operator.

The watershed segmentation algorithm is applied on the synthesized placenta image which gives the segmentation of the placenta from the ultrasound as given in the Figure 10 below.

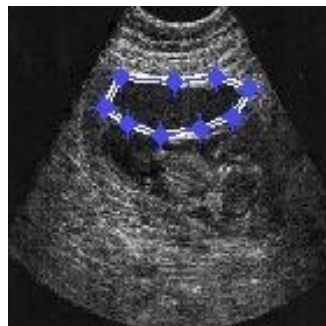

Figure 10. Watershed Segmentation of Ultrasound Placenta

The contour is traced for the segmented placenta which is marked in the Figure 10 as dotted lines. The contour extracted ultrasound placenta is displayed below.



Figure 11. Contour Extracted Ultrasound Placenta

The segmented binary image of the placenta is displayed in the Figure 12 which is used to generate the parameters required for volume estimation.

5. Statistical measurement of segmented region

The statistical measures often give characteristic parameters on the interested image. There is a need for the measurement of major axis length. The complications in placenta that occur during pregnancy show some variations in the size of the placenta. There arise the need for the measurement of major axis length and minor axis length of the segmented placenta. With these statistical values one can obtain the area and perimeter of the segmented image. These values are then recorded to delineate the normal placenta and the placenta complicated by gestational diabetes mellitus. The distance measure tool is used to obtain the thickness of the placenta.



Figure 12. Segmented Binary Image of Ultrasound Placenta

Images	Area	Perimeter	Class
Image1	3.2167	6.7019	AN
Image2	6.0015	11.7823	AN
Image3	10.2083	14.8600	AN (GDM)
Image4	6.8913	9.9025	AN
Image5	7.3428	10.3109	N

Table 11. Statistical Measurement of Area, Perimeter of the Segmented Ultrasound Placenta

The limitation in the ultrasound scanning prevents monitoring the growth of the placenta. Placental volume assessment is uncommon in routine obstetric practice, a lack that prevents obstetricians from identifying their patients with extremely small or large placentas.

6. Convex concave shell model

A new method to determine the volume of the two dimensional ultrasound placentas using a mathematical model is proposed. The aim of the work is to correlate the height, width and thickness of the ultrasound placenta in measuring the placental volume.

The shape of the placenta in general is a round or oval. Using this as reference, the major axis length (l) and minor axis length (b) of the ultrasound placenta of a segmented image is obtained using '*regionprops*' in Matlab 7.0. The thickness (h) of the placenta was obtained from the point of chord insertion. This was obtained using the measure tool in Matlab 7.0. The mathematical representation of the segmented placenta is shown in Figure 13. The feasibility for classifying the ultrasound images of placenta with complicating diabetes based on placenta thickness using statistical textural features was analyzed.

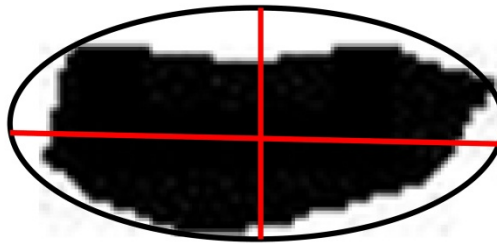


Figure 13. Measurement of Major Axis Length and Minor Axis Length to calculate Area and Perimeter

The concave-convex shell formula

$$V = \left(\left(\frac{\pi h}{6} \right) * [4b(l - h) + l(l - 4h) + 4h^2] \right) \quad (1)$$

Where,

h=Thickness, b=Minor Axis Length, l=Major Axis Length

The high values of major axis length and minor axis length strongly indicate placenta complicated by gestational diabetes mellitus.

The Figure 14 represents the mathematical model of volume estimation from the ultrasound images of placenta. The volume estimated by measuring the length (black marker) of the placenta, height of the placenta (green marker) as seen in ultrasound and the thickness (red marker) measured from point of chord insertion.




Figure 14. Concave-Convex Shell Representation of Ultrasound Placenta

Img Id	Major Axis Length (l)	Minor Axis Length (b)	Height (h)	Volume (V)	Class
Img1	7.482	3.79	2.31	104.689004	1
Img2	13.72	4.63	3.6	433.1933952	2
Img3	5.76	4.13	0.98	47.90461872	0
Img4	7.9	3.71	1.54	94.78968781	1
Img5	6.95	3.51	1.9	80.3664945	1
Img6	7.482	3.79	2.31	104.689004	1
Img7	14.78	4.01	4.78	469.4087275	2
Img8	5.23	2.1	1.98	29.95954698	0

Table 12. Volume Estimation from Statistical Parameters

7. Conclusion

The study concludes that the application of wavelet decomposition reduces the speckle in the ultrasound placenta. The fusion of such decomposed wavelet improves the characteristics of the essential features which in turn, enhances the classification accuracy. The Haralick features obtained for the ultrasound image of placenta plays a significant role in the classification process. There is also an increase in the contrast of ultrasound placenta which is complicated by GDM. The outcome of the research is that, multi-view scans can be fused to identify the influence of GDM on the early stage of placental growth by employing wavelet decomposition and image fusion technique. This research also suggests that, the evaluation of the volume of placenta during the routine ultrasound screening at fifteen to twenty weeks of gestation using wavelet fusion of multi-view of the ultrasound placenta can identify the influence of diabetes mellitus which otherwise can lead to the severe risk of fetal demise.

Author details

G. Malathi

*School of Computer Science and Engineering, VIT University-Chennai Campus
Chennai, India*

V. Shanthy

*Department of MCA, St. Joseph's College of Engineering, Affiliated to Anna University,
Chennai, India*

8. References

- [1] <http://en.wikipedia.org/wiki/Placenta> (Archived from the original on 6 January 2008)
- [2] Sicree R. Shaw J. Zimmet P. Diabetes and impaired glucose tolerance. In: Diabetes Atlas. International Diabetes Federation.(ed). Belgium: International Diabetes Federation; 2006. p.15-103.
- [3] http://en.wikipedia.org/wiki/Computer-aided_diagnosis (Accessed 12 September 2009).
- [4] India has largest number of diabetes patients – Report.
www.indianexpress.com/news/india-has-largest-number-of-diabetes-patient /531240/ (Accessed 21 October 2009).
- [5] www.fortishospitals.com/associate-specialities/
- [6] [diabetology_and_endocrinology.html](http://www.fortishospitals.com/associate-specialities/diabetology_and_endocrinology.html) (Accessed 10 February 2011)
- [7] Muhammad Ashfaq, Muhammad ZahoorJanjua, Muhammad Aslam Channa. Effect of gestational diabetes and maternal hypertension on gross morphology of placenta. Journal of Ayub Medical College; <http://www.ayubmed.edu.pk/JAMC/PAST/17-1/Ashfaq.htm> (Accessed 13 October 2011)
- [8] Metzger BE, Coustan DR(Eds). Gestational Diabetes Mellitus. Diabetes Care: 4th International Workshop – Conference Proceedings. Vol. 21(Suppl. 2). p. B1-B167; 1998.
- [9] Gestational Diabetes Mellitus. American Diabetes Association, Diabetes Care. vol. 27. p. 88-90; 2004.
- [10] Seshiah V. Prevalence of Gestational Diabetes Mellitus in South India (Tamil Nadu) – A Community Based Study. JAPI. vol.56; 2008.
- [11] EberhardMerz F. Bahlmann. Ultrasound in Obstetrics and Gynecology. vol.1. Thieme; 2005.
- [12] <http://www.pregnancycheck.com/pregnancy-ultrasound.html> (Accessed 29 August 2011).
- [13] JosipDjelmis. GernotDesoye. Marina Ivanisevic. Diabetology of pregnancy: Karger.
- [14] Novel study in TN to know gestational diabetes effects. The Hindu. Health – Medicine & Research. (Accessed on 8 March 2012).
- [15] BhanuPrakash K.N. et al. Lung Maturity Analysis Using Ultrasound Image Features. IEEE Transactions on Information Technology in Biomedicine 2002;6(1) 38-45.

- [16] Thomose R. Moore et al. Diabetes Mellitus and Pregnancy. eMedicine. <http://emedicine.medscape.com/article/127547-overview> (Accessed 3 February 2012)
- [17] www.pregnancy-info.net/placental_abruption.html (Accessed 23 May 2010)