

What Are The Effects of Silibinin on Testicular Tissue of Mice?

Hayder G. Oufi*, Nada N. Al-Shawi and Saad AR. Hussain

*Department of Pharmacology and Toxicology, College of Pharmacy, University of Baghdad, Baghdad-Iraq.

ARTICLE INFO

Article history:

Received on: 28/10/2012

Accepted on: 14/11/2012

Available online: 28/11/2012

Key words:

Silibinin,
Silymarin,
Testosterone,
Leydig cell,
Testicular tissue.

ABSTRACT

Silibinin (silybin) is one of the structural isomers of the flavonoid silymarin, and it has wide variety of phytotherapeutic applications and the aim of this study was to investigate the effects of different doses of silibinin on testicular tissue of mice. Twenty male Swiss albino mice were divided into four groups. Each group consist of five animal, (Group 1) (negative control) animals were administered single intraperitoneal (IP) daily dose of phosphate buffer for 5 days, Groups (2, 3, and 4) were given a single IP daily dose of either (50, 100 or 150 mg/kg B.wt.) of silibinin respectively for 5 days. Microscopic examinations of sperms, histological examinations of testes and serum testosterone level had been measured. It was found that silibinin in doses of (100 or 150) mg/Kg produced a significant increase ($P<0.05$) in the level of testosterone in comparison with group 1. Also, silibinin in dose of 100 mg/Kg showed a significant increase in the diameter of spermatide, and significant increase was observed in group of animals treated with 150 mg/kg of silibinin concerning the diameter of primary spermatocyte and diameter of spermatide. The results indicate that silibinin can improve some testicular parameters as well as testosterone levels.

INTRODUCTION

Silibinin (silybin), is a water-soluble form of one of the structural isomers of the flavonoid silymarin and it is the most biologically active, which can be extracted from the milk thistle (*Silybum marianum* L. Gaert., Asteraceae) (Salmi *et al.*, 1982), (DerMarderosian 2001).

Silibinin has wide variety of phytotherapeutic applications, where it acts as an antioxidant (Borsari *et al.*, 2001); also it has an effective measure against liver damage (Vogel *et al.*, 1984). Furthermore, silibinin shows anti-inflammatory action, where it hinders inflammatory process, as well as inhibits the formation of inflammatory mediators and it inhibits NF- κ B activation and translocation (Fiebrich *et al.*, 1979; Yoo *et al.*, 2004). It was found that in cancer cells, silibinin alters cell cycle regulators and induces apoptosis, both through antioxidant and anti-inflammatory properties (Mokhtari *et al.*, 2008; Raina *et al.*, 2008; Verschoyle *et al.*, 2008; Lah *et al.*, 2007). In viral infection, silibinin strongly inhibits growth of both HepG2 (hepatitis B virus negative; p53 intact) and Hep3B (hepatitis B virus positive; p53 matured) cells which is associated with induction of apoptosis (Das *et al.*, 2008).

Additionally, silibinin exerts hypoglycemic action and improves insulin sensitivity (Velussi *et al.*, 1997). Because of the diversity in actions of silibinin and its multiple biological and metabolic functions, this study was carried out to evaluate the effects of different doses of silibinin on highly proliferative tissue, testicular tissue of mice.

MATERIALS AND METHODS

Chemicals

Silibinin, as silibinin hemisuccinates, was purchased from Tolbiac S.R.L. Buenos Aires – Argentina, potassium dihydrogen phosphate manufacture by Gainland Chemical Company (GCC) - UK, and disodium phosphate manufacture by Riedel Hannover - Germany. Silibinin solution for injection was prepared by dissolving silibinin hemisuccinates powder in phosphate buffer (pH 8), with solubility of 13 mg/ml, and the volume of each treatment was maintained uniformly to 1.16 ml/100 g body weight of mice by diluting the solution accordingly.

Animals

Twenty male Swiss albino mice (8–10weeks old) weighing 28-32g were used in the present investigation. The animals were obtained from the Animals House of the College of pharmacy, University of Baghdad. They were housed in cages in a temperature controlled ($20\pm 5^{\circ}\text{C}$) with 12h dark/light cycle. They were provided with standard diet pellets and water *ad libitum*.

* Corresponding Author

Hayder Gaeed Oufi

Iraq-Baghdad-Almansoor,

Mobile: +964 780 102 4311

Experimental protocol and groups

The experiment was performed on four groups of mice each consisting of 5 animals; as follows: Group 1 animals were administered single intraperitoneal (IP) daily dose of phosphate buffer pH 8 (used as vehicle for silibinin) for 5 days. This group was served as negative control. (Group 2), (Group 3) and (Group 4) were given a single IP daily dose of either (50 mg/kg B.wt.) or (100 mg/kg B.wt.) or (150 mg/kg B.wt.) of silibinin for 5 days.

Animals were sacrificed by cervical dislocation, 6 weeks after the last day of treatment (Olsen *et al.*, 2005; Peirce *et al.*, 2001; Aragon *et al.*, 2005).

Microscopic examinations of sperms

Sperms were assessed according to (WHO 1992) Laboratory manual for motility, percentage of dead/live sperm and abnormalities; where, the spermatozoa were obtained by making small cut in cauda epididymis placed in 1ml of pre-warmed phosphate buffer saline (pH 7.4). Sperm motility was assessed by standard subjective ranking method where percent progressive motility was estimated to the nearest 10%. The motility was determined by placing 10 μ l of the sperm sample on a clean pre-warmed microscopic slide, covered with a cover-slip and examined using a light microscope (Moetic).

Histological examination of testes

The perfuse-fixed testes placed in Bouin fluid overnight, and processed for routine paraffin embedding. The testes were cut (using Lecia) into 5- μ m sections. Three serial sections per testes were mounted on slides, deparaffinized, rehydrated, and stained with hematoxyline - eosin stain (Bancroft, 1982). Sections of the testes were examined by light microscope at 10, 40 and 100 \times magnification, seminiferous tubules, interstitial spaces between seminiferous tubules, primary spermatocytes and spermatids diameters were assessed in each testis using previously calibrated micrometers (Ocular micrometer, Stage micrometer). The diameter of 25 seminiferous tubules was measured in 5 fields (5 seminiferous tubules per field). In similar manner diameter of primary spermatocytes, spermatids, Leydig cells were measured in 5 fields and the mean value of each was calculated.

Measurement of Serum Testosterone Level

Blood samples have been obtained from the heart by intracardiac puncture, and then centrifuged at 2000 rpm/minute for

15 minute to obtain serum, which was utilized for the assessment of testosterone level using Bio merieux (Italia S.P.) a vidia campigliano, 58 50015-point A EMA (F₁) Italia miniVIDAS, following the manufacturer's recommendations.

Statistical analysis

Data were analyzed using SPSS version 16 and Microsoft Office Excel 2007. Numeric data were expressed as mean \pm S.D. ANOVA was used to test the difference in mean among treated groups with LSD multiple comparison test. Pearson's correlation coefficient was used to study correlation between diameter of Leydig cell and serum testosterone level. P-value was considered significant when it is <0.05.

This work had been approved by ethical committee in college of pharmacy-Baghdad University.

RESULTS

Silibinin in doses of 50 or 100 or 150 mg/Kg B.wt. (group 2, 3 or 4), respectively had no significant ($P > 0.05$) effects on the percent of motile sperms, dead/live sperms and abnormal sperms in comparison with group 1 (negative control) (Figure 1). Moreover, silibinin in dose of 100 mg/Kg B.wt. (Group 3) or 150mg/Kg B.wt. (Group 4) produced a significant increase ($P < 0.05$) in the level of testosterone (Figure 2) and the levels being (2.39 ± 0.44 and 2.40 ± 0.39), respectively in comparison with group 1 (1.87 ± 0.34).

Concerning testicular histology (Figure 3), silibinin in dose of 100 mg/Kg B.wt. (group 3) showed a significant increase ($P < 0.05$) in the diameter of spermatide. Also significant differences ($P < 0.05$) were observed in group of animals treated with 150 mg/kg silibinin (group 4) concerning the diameter of primary spermatocyte and diameter of spermatide in comparison with group 1 (Table 1).

Correlation coefficient between the diameter of Leydig cells and serum testosterone

Pearson correlation coefficient was performed to correlate between the diameter of Leydig cell and serum testosterone.

As shown in (table 2) there was positive correlations in groups (1- 4) but statistically not significant except in group 4 where there was a significant positive correlation was observed ($p < 0.05$).

Table 1: Effects of different doses of silibinin (50, 100 or 150 mg/Kg B.wt.) compared to negative control (group 1).

Parameter	Group 1	Group 3	Group 4	Group 5
	(negative control)	50mg/kg silibinin	100mg/kg silibinin	150mg/kg silibinin
Diameter of seminiferous tubules (μ m)	210.00 \pm 2.24	212.80 \pm 6.42	212.00 \pm 7.35	217.60 \pm 2.30
Interstitial space (μ m)	20.40 \pm 1.82	19.60 \pm 2.30	19.20 \pm 2.17	19.20 \pm 2.17
Diameter of primary spermatocyte (μ m)	7.28 \pm 0.40	7.32 \pm 0.23	7.48 \pm 0.41	7.62 \pm 0.22*
Diameter of spermatide (μ m)	4.50 \pm 0.29	4.84 \pm 0.22	4.98 \pm 0.32*	5.52 \pm 0.50*
Diameter of Leydig cell (μ m)	5.78 \pm 0.29	6.04 \pm 0.62	6.28 \pm 0.73	6.24 \pm 0.68

- Data are expressed as mean \pm S.D.

- *Results were significant at $P < 0.05$ compared to negative control (group 1).

- n=5 animals in each group.

Table. 2: Pearson correlation coefficient between diameter of Leydig cell and serum testosterone level among groups (1-4).

	Group 1	Group 2	Group 3	Group 4
r	0.778	0.294	0.006	0.955*
P	0.121	0.632	0.993	0.011

- r* was statistically significant when P<0.05.

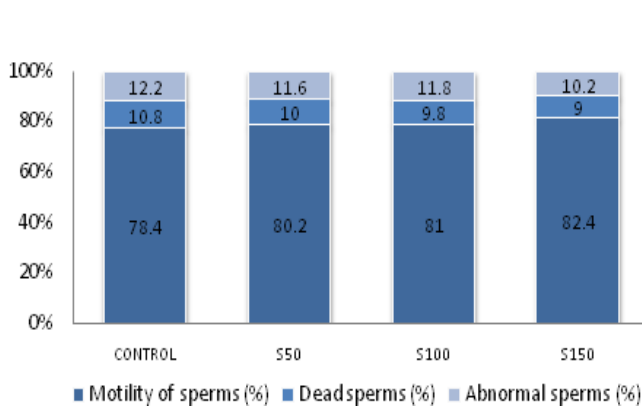


Fig. 1: shows motility, dead and abnormal sperms among groups (1-4) of mice. S50=Group 2, S100=Group 3, S150=Group 4

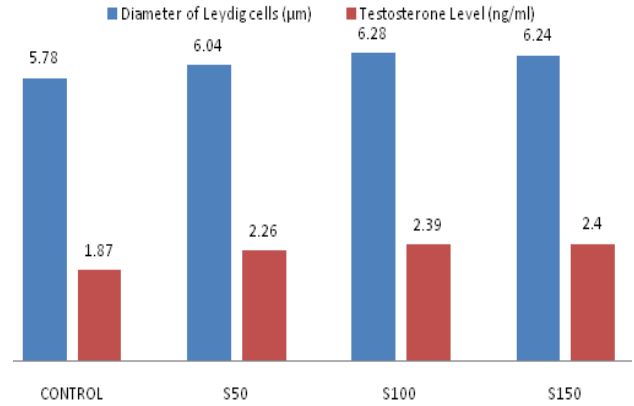


Fig. 2: shows diameter of Leydig cells and serum testosterone levels among groups (1-4) of mice. S50=Group 2, S100=Group 3, S150=Group 4

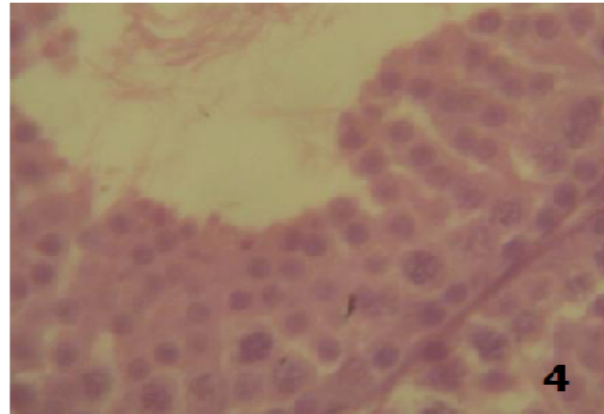
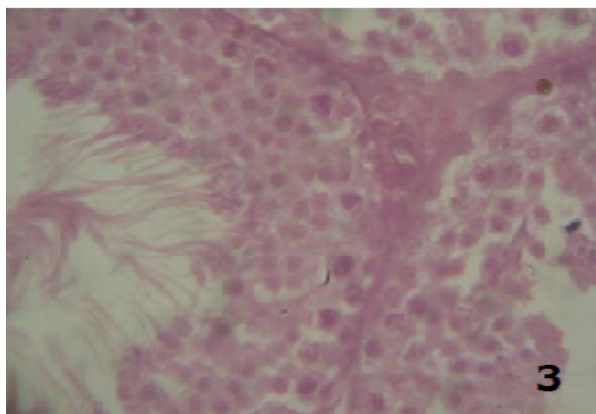
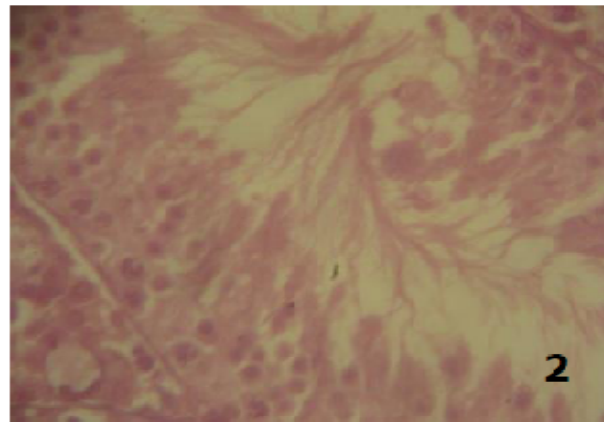
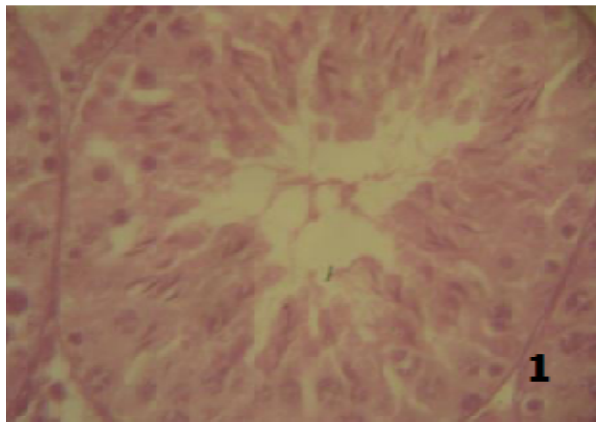


Fig. 3: Photomicrographs of H&E stained histological slides of testis; Photos (1-4) represent groups (1- 4) with magnification 100×; showing the change in diameter of spermatide and diameter of primary spermatocyte among the groups. **1:** buffer (negative control group); **2:** 50mg/kg silibinin-treated group; **3:**100mg/kg silibinin-treated group; **4:**150mg/kg silibinin - treated group.

DISCUSSION

In groups of mice treated with either (50 or 100 or 150) mg/kg/day silibinin for five days, there were a dose dependent improvement in the motility of sperms with a decrease in the percent of dead sperms, but this was statistically non-significant when compared to the negative control animals (group 1). It has been shown that silibinin has an antioxidant property where it inhibits radical formation, binds some radical species, interferes with lipid peroxidation of membranes, and increases the intracellular content of scavengers (Verschoyle *et al.*, 2008); therefore it may have further significant effects on the quality of sperms if the dose and/or the duration of exposure changed.

Mammalian spermatozoa membrane is rich in polyunsaturated fatty acids. This makes them very susceptible to oxygen-induced damage, which is mediated by lipid peroxidation. In a normal situation, the antioxidant mechanisms present in the reproductive tissues are likely to quench these reactive oxygen species (ROS) and protect gonadal cells and mature spermatozoa from oxidative damage (Sikka 2001).

Oxidative stress (OS), results from accumulation of excessive reactive oxygen species (ROs) during spermatogenesis epididymal sperm maturation as well as from exposure of toxic chemicals, environmental pollutants etc... ROSs change lipid/protein ratio of membranes by affecting polyunsaturated fatty acids and lipid peroxidation causes functional irregularities of several cellular organelles (Agarwal *et al.*, 2005; Tremellen 2008). Regarding hormonal analysis, the data obtained from this work revealed that there was a dose dependent increase in testosterone level among the groups (2-4). In group 3, silibinin produced a 20.85% increase in serum testosterone level compared to the corresponding level of negative control group but such increase was statistically not significant ($P > 0.05$). While in groups 4 and 5, serum testosterone levels were increased significantly ($P < 0.05$) by 27.80% and 28.34%, respectively compared to negative control group.

Testicular function has been found to be influenced by endocrine and paracrine factors. The hypothalamic-pituitary-testicular axis plays a central and critical role in the male reproductive system (Moudgal *et al.*, 1998). The hypothalamus controls gonadotropin release in the pituitary gland by secreting gonadotropin-releasing hormone (GnRH) that releases glycoprotein gonadotropins, luteinizing hormone (LH) and follicle-stimulating hormone (FSH) which in turns, travel to the testes by blood stream and exert their effects directly on testicular somatic cells. LH receptor is expressed by Leydig cells in the testicular interstitial tissue (Zhang *et al.*, 1994), whereas Sertoli cells bind FSH (Heckert *et al.*, 1991; 1993). LH stimulates testosterone production from cholesterol in Leydig cells (Moyle *et al.*, 1970). In the current work, treatment with either 100 or 150 mg/kg silibinin produced an increase in serum testosterone level and its effect may be exerted either centrally (at pituitary and hypothalamus) or directly (Leydig cells) or peripherally (aromatase inhibitor) or by interfering with testosterone

biosynthesis. It was reported that treatment of male rats with silymarin for one month resulted in a significant increase of serum testosterone and LH levels while estradiol level did not change (Khalil 2002). Besides, Hodek *et al.* (2002) noticed that flavones and flavonone have higher aromatase inhibitory activity and it has been observed that silymarin has as an aromatase inhibitor property (Khalil 2002) and this could explain the increasing in testosterone level. Concerning testicular histology, the results of the current study revealed that the diameter of spermatide in group of mice treated with 100mg/kg silibinin (group 3) was significantly increased ($P < 0.05$) by 10.66% with non-significant difference ($P < 0.05$) in the diameter of primary spermatocyte compared to negative controls (group 1); While in mice treated with 150mg/kg silibinin (group 4), results showed a significant increase ($P < 0.05$) in both the diameter of primary spermatocyte and the diameter of spermatide by 4.67% and 22.66%, respectively. This indicates that silibinin may improve the testicular cell function and spermatogenesis through prevention of the oxidative stress (Borsari *et al.*, 2001) and/or due to its anti-inflammatory effect (Fiebrich *et al.*, 1979).

Furthermore, data obtained from this study revealed that 150mg/kg silibinin injected IP to mice has a significant positive correlation of testosterone level in correlation with the diameter of Leydig cell ($r = 0.955$ when $p < 0.05$) and this may be due to the direct effect of silibinin on Leydig cell by enhancing the ability of Leydig cells for testosterone production.

CONCLUSION

In conclusion, the data obtained from this study demonstrated that silibinin can improve some testicular parameters as well as testosterone levels, and accordingly, it can be utilized as supplementation to enhance male reproductive function, specifically spermatogenesis.

ACKNOWLEDGEMENTS

This work was supported by College of pharmacy/Baghdad University in cooperation with Biotechnology Research Center / Al -Nahrain University.

REFERENCES

- Agarwal A. and Said MT. Oxidative stress DNA damage and apoptosis in male infertility: a clinical approach. *BJU International*. 2005; 95: 503-507.
- Aragon M.A., Ayala M.E., Fortoul T.I., Bizarro P. and Altamirano-Lozano M. Vanadium induced ultrastructural changes and apoptosis in male germ cells, *Reprod. Toxicol*. 2005; 20:127-134.
- Bancroft J. *Enzyme Histochemistry*. In: *Theory and Practice of Histological Techniques Bancroft and Stevens A (eds.) 2nd edition*. Churchill living stone, London (1982) 3374-405.
- Borsari M., Gabbi C., Ghelfi F., Grandi R., Saladini M., Severi S., Borella F. Silybin, a new iron-chelating agent. *J InorgBiochem*. 2001; 85: 123-129.
- Das S.K., Mukherjee S. and Vasudevan D.M. Medicinal properties of milk thistle with special reference to silymarin: An overview. *Nat. Prod. Rad*. 2008; 7: 182-192.

DerMarderosian A. The Reviews of natural products. 1st ed. Facts and Comparisons: St. Louis, Missouri (2001).

Fiebrich F. and Koch H. Silymarin, an inhibitor of lipoxigenase. *Experientia*. 1979; 35: 150-152.

Heckert L. and Griswold M.D. Expression of follicle stimulating hormone receptor mRNA in rat testes and Sertoli cells *Mol. Endocrinol*. 1991; 5: 670-677.

Heckert L. and Griswold M.D. Expression of the FSH receptor in the testis *Recent Prog. Horm. Res.*1993; 48: 61-77.

Hodek P., Trefil P. and Stiborova M. Flavonoids-potent and versatile biologically active compounds interacting with cytochromes P450. *Chemico-Biological Interactions*. 2002: 139.

Khalil E.A. Hormonal Profile and Histopathological Study On The Influence Of Silymarin On Both Female And Male Albino Rats, *The Egyptian Journal of Hospital Medicine*. 2002; 13: 112 – 122.

Lah JJ., Cui W. and Hu KQ. Effects and mechanisms of silibinin on human hepatoma cell lines. *World J Gastroenterol*. 2007; 13: 5299-5305.

Mokhtari MJ., Motamed N., Shokrgozar MA. Evaluation of silibinin on the viability, migration and adhesion of the human prostate adenocarcinoma (PC-3) cell line. *Cell BiolInt*. 2008; 32: 888-892.

Moudgal N.R. and Sairam M.R. Is there a true requirement for follicle stimulating hormone in promoting spermatogenesis and fertility in primates? *Hum Reprod*. 1998; 13:916–919.

Moyle W.R. and Armstrong D.T. Stimulation of testosterone biosynthesis by luteinizing hormone in transplantable mouse Leydig cell tumors *Steroids*. 1970; 15: 681-693.

Olsen A.K., Lindeman B., Wiger R., Duale N. and Brunborg G. How do male germ cells handle DNA damage? *Toxicol. Appl. Pharmacol*. 2005; 207: 521–531.

Peirce E.J. and Breed W.G. A comparative study of sperm production in two species of Australian arid zone rodents (*Pseudomys australis*, *Notomys alexis*) with marked differences in testis size, *Reproduction*. 2001; 121: 239–247.

Raina K., Rajamanickam S., Singh RP., Deep G., Chittechath M., Agarwal R. Stage-specific inhibitory effects and associated mechanisms of silibinin on tumor progression and metastasis in transgenic adenocarcinoma of the mouse prostate model. *Cancer Res*. 2008; 68: 6822-6830.

Salmi H. A., Sarna S. Effect of silymarin on chemical, functional and morphological alterations of the liver. *Scand. J. Gastroenterol*. 1982; **17**: 517–521.

Sikka SC. Relative impact of oxidative stress on male reproductive function. *Current Medicinal Chemistry*. 2001; 8: 851-862.

Tremellen K. Oxidative stress and male infertility - a clinical perspective *Human Reproduction Update*. 2008; 14: 243-258.

Velussi M., Cernigoi A.M., De Monte A., Dapas F., Caffau C. and Zilli M. Long-term (12 months) treatment with an anti-oxidant drug (silymarin) is effective on hyperinsulinemia, exogenous insulin need and malondialdehyde levels in cirrhotic diabetic patients, *J. Hepatol*. 1997; 26: 871–879.

Verschoye RD., Greaves P., Patel K., Marsden DA., Brown K., Steward WP. and Gescher AJ. Evaluation of the cancer chemopreventive efficacy of silibinin in genetic mouse models of prostate and intestinal carcinogenesis: relationship with silibinin levels. *Eur J Cancer*. 2008; 44: 898-906.

Vogel G., Tuchweber B., Trost W., Mengs U. Protection by silibinin against *Amanita phalloides* intoxication in beagles. *Toxicol. Appl. Pharmacol*. 1984; 73:355-362.

WHO Laboratory manual for the examination of human semen and sperm – cervical mucus interaction. Third Edition. Cambridge University press (1992).

Yoo HG., Jung SN., Hwang YS., Park JS., Kim MH., Jeong M., Ahn SJ., Ahn BW., Shin BA., Park RK., Jung YD. Involvement of NF-kappaB and caspases in silibinin-induced apoptosis of endothelial cells. *Int J Mol Med*. 2004; 13: 81-86.

Zhang F.P., Hämäläinen T., Kaipia A., Pakarinen P. and Huhtaniemi I. Ontogeny of luteinizing hormone receptor gene expression in the rat testis *Endocrinology*. 1994; 134: 2206-2213.

How to cite this article:

Hayder G. Oufi, Nada N. Al-Shawi and Saad AR. Hussain., What Are The Effects of Silibinin on Testicular Tissue of Mice?. *J App Pharm Sci*. 2012; 2 (11): 009-013.