

# What We Know (and Do not Know) Regarding the Pathogenesis of Pulmonary Thrombosis in COVID-19

Giuseppe Lippi, MD<sup>1</sup> Emmanuel J. Favaloro, PhD, FFSc (RCPA)<sup>2,3,4</sup>

<sup>1</sup>Section of Clinical Biochemistry, University of Verona, Verona, Italy

<sup>2</sup>Department of Haematology, Institute of Clinical Pathology and Medical Research (ICPMR), NSW Health Pathology, Westmead Hospital, Westmead, NSW, Australia

<sup>3</sup>Sydney Centres for Thrombosis and Haemostasis, Westmead, NSW, Australia

<sup>4</sup>Faculty of Science and Health, Charles Sturt University, Wagga Wagga, NSW, Australia

Address for correspondence Giuseppe Lippi, MD, Section of Clinical Biochemistry, University Hospital of Verona, Piazzale L. A. Scuro, 10, 37134 Verona, Italy (e-mail: giuseppe.lippi@univr.it).

Semin Thromb Hemost 2023;49:27–33.

## Abstract

The clinical course of coronavirus disease 2019 (COVID-19) is often complicated by the onset of venous thrombosis and thromboembolism (VTE), encompassing also pulmonary thrombosis. Recent statistics attest that the cumulative frequency of VTE can be as high as 30% in COVID-19 hospitalized patients, increasing to nearly 40 to 70% (depending on systematic screening) in those with severe illness, mechanical ventilation, or intensive care unit admission. The risk of venous thrombosis seems mostly limited to the active phase of disease, and is directly associated with some genetic (i.e., inherited prothrombotic predisposition) and demographical factors (male sex, overweight/obesity), disease severity (risk increasing progressively from hospitalization to development of severe illness, being the highest in patients needing mechanical ventilation and/or intensive care), presence and extent of pulmonary disease, coexistence of multiple risk factors (immobilization, mechanical ventilation, co- or superinfections), along with increased values of inflammatory and thrombotic biomarkers. At least three different phenotypes of pulmonary thrombosis may develop in COVID-19 patients, one caused by typical embolization from peripheral venous thrombosis (e.g., deep vein thrombosis), a second type triggered by local inflammation of nearby pulmonary tissue, and a third one mostly attributable to the prothrombotic state consequent to the pronounced systemic inflammatory response (i.e., the so-called cytokine storm) that is frequently observed in COVID-19. Although the pathogenesis of these three conditions has different features, their discrimination is essential for diagnostic and therapeutic purposes. The prognosis of COVID-19 patients who develop pulmonary thrombosis is also considerably worse than those who do not, thus probably needing frequent monitoring and more aggressive therapeutic management.

## Keywords

- ▶ COVID-19
- ▶ SARS-CoV-2
- ▶ thrombosis
- ▶ venous thromboembolism

Coronavirus disease 2019 (COVID-19), an infectious respiratory disease sustained by the  $\beta$  coronavirus called severe acute respiratory syndrome coronavirus 2 (SARS-CoV-2), was originally identified in the Chinese town of Wuhan

(Hubei province) at the end of the 2019.<sup>1</sup> The infection, which started as a local outbreak, then progressively spread all around the world, assuming the final connotation of a pandemic, causing already over 5.4 million deaths up to the

article published online  
January 12, 2022

Issue Theme Maintaining Hemostasis and Preventing Thrombosis in COVID-19—Part IV; Guest Editors: Emmanuel J. Favaloro, PhD, FFSc (RCPA), Leonardo Pasalic, FRCPA, FRACP, PhD, and Giuseppe Lippi, MD

© 2022. Thieme. All rights reserved.  
Thieme Medical Publishers, Inc.,  
333 Seventh Avenue, 18th Floor,  
New York, NY 10001, USA

DOI <https://doi.org/10.1055/s-0041-1742091>  
ISSN 0094-6176.

end of December 2021 according to the official statistics of the John Hopkins University.<sup>2</sup>

What has now become rather clear after 2 years of COVID-19 and research into the pathogenesis of this severe infectious disease, is that SARS-CoV-2, unlike its predecessors SARS-CoV-1 and Middle-East respiratory syndrome coronavirus (MERS-CoV), is highly infective (the effective reproduction number of novel variants is up to 5, meaning that one single infected person can infect up to 5 healthy people),<sup>3</sup> can also be spread from asymptomatic and presymptomatic people,<sup>4</sup> and, even more importantly, may progress far beyond the upper and lower respiratory tracts, thus becoming a life-threatening systemic disorder.<sup>5</sup>

Among the various biologic and metabolic pathways that can be progressively disrupted and impaired by SARS-CoV-2, direct cytopathic cell injury and sustained inflammation are the main drivers of most COVID-19 complications.<sup>6</sup> A secondary aspect of COVID-19 is that important evidence has accumulated that SARS-CoV-2 may be responsible for a specific form of immunothrombosis (and/or thromboinflammation), which can be defined as active involvement of the innate immune system in fostering thrombus generation through different and almost distinct cellular and molecular pathways, originally triggered by recognition of pathogens and damaged cells,<sup>7</sup> whose pathogenesis has been comprehensively described elsewhere.<sup>8–10</sup> This peculiar immune response may be clearly regarded as a kind of “Janus Bifrons,” since it works well as conserved evolutionary defense for preventing or attenuating pathogen dissemination (mostly by entrapping the virus inside blood clots),<sup>11</sup> while can also be responsible for a kaleidoscope of thrombotic events within human blood vessels.<sup>12</sup>

## Frequency of Venous Thromboembolism in COVID-19

Systemic venous thromboembolism (VTE) is rather frequent in patients with SARS-CoV-2 infection. A series of systematic literature reviews and meta-analyses have estimated that thrombotic episodes can be observed with especially high frequency in COVID-19 patients with severe illness. Di Minno et al originally estimated that the cumulative frequency of VTE in all COVID-19 patients was 31.3%, that of deep vein thrombosis (DVT) was 19.8% and that of pulmonary embolism (PE) was 18.9%, respectively.<sup>13</sup> In a subsequent meta-analysis, Liu et al concluded that the cumulative incidence of VTE in hospitalized COVID-19 patients was 28%, increasing to 38% in those with severe illness, with cumulative frequency of DVT and PE of 18.3 and 17.6%, respectively, in all COVID-19 patients, increasing to around 22% in those with severe illness.<sup>14</sup> The risk of developing venous thrombosis was found to be dramatically increased in COVID-19 patients needing intensive care unit (ICU) admission and systematically screened for VTE, as shown by Jenner et al, who concluded that the overall VTE prevalence may increase up to 70%, with nearly 56% of all thrombotic episodes attributable to DVT and 18% to PE, respectively.<sup>15</sup> The risk of developing DVT and PE was found

to be especially higher during the first week after receiving a diagnosis of SARS-CoV-2 infection according to the nationwide Scottish analysis published by Ho et al.<sup>16</sup> In this article, the risk of both DVT and PE was confirmed to be considerably enhanced (by 13- to 35-fold) in COVID-19 patients who required hospitalization than in those who did not. As predictable, the outcome of COVID-19 patients with VTE can be worse than that of those without, as evidence by the meta-analysis of Kollias et al (odds ratio [OR] for death: 2.1; 95% confidence interval [95% CI], 1.2–3.6).<sup>17</sup> As specifically concerns patients admitted to the emergency department (ED), Miró et al performed a comprehensive multicenter study involving 62 Spanish EDs,<sup>18</sup> and reported that the standardized incidence of PE patients diagnosed with SARS-CoV-2 infection was nearly ninefold higher compared with the non-COVID-19 population (310 vs. 35 cases per 100,000 person-years; OR, 8.95 and 95% CI, 8.51–9.41).

In an interesting population study performed in Northern California by Roubinian et al,<sup>19</sup> the authors compared the frequency of VTE in COVID-19 patients and in the general population, concluding that the cumulative risk of thrombosis was 47% higher in patients with COVID-19, and such risk was mostly seen during hospitalization, but then decreased after hospital discharge. Cumulatively, the 30-day incidence of VTE was found to be almost threefold higher in patients with SARS-CoV-2 infection than in those without (i.e., 4.7 vs. 1.6 VTE episodes per 1,000 individuals). Even comparing the incidence of VTE episodes in patients hospitalized for COVID-19 or for influenza, the cumulative risk of thrombotic events is substantially magnified in those with the former. For example, Stals et al reported that the risk of VTE was between two- and threefold higher in patients with SARS-CoV-2 infection compared with those with influenza virus infection, further increasing to 4.4- to 8.4-fold in those staying in the ICU.<sup>20</sup> It is also important to mention here that the risk of venous thrombosis seems to be mostly limited to the active phase of disease. In the study of Engelen et al,<sup>21</sup> 485 patients hospitalized for COVID-19 were followed-up for 6 weeks. Although elevated D-dimer values were noted in nearly one-third of all patients after hospital discharge (42% in those discharged from the ICU), the prevalence of DVT and PE was 1.4% (0.7% for both DVT and PE).<sup>21</sup> This is in keeping with findings published by Ramos-Martínez et al,<sup>22</sup> who reported that VTE contributed only around 5% of all hospital readmissions after recovering from COVID-19, far behind the two other most frequent causes (~54% pneumonia and ~12% bacterial infection, respectively). Li et al performed also a large cohort study, including 2,832 adult patients with COVID-19 who were followed up for 3 months after hospital discharge.<sup>23</sup> Overall, 36 of such patients (1.3%) developed VTE episodes on follow-up (16 PE, 18 DVT, and 2 portal vein thrombosis, respectively). The likelihood of developing VTE decreased over time, while significant predictors of postdischarge thrombosis were a positive history for venous thrombosis (OR, 3.24; 95% CI, 1.34–7.86), persistently elevated D-dimer values (> 3 g/L: OR, 3.76; 95% CI, 1.86–7.57), and increased predischARGE concentration of C-reactive protein (> 10 mg/dL: OR, 3.02; 95% CI, 1.45–6.29), while therapeutic anticoagulation at

discharge was associated with nearly 80% lower risk of developing VTE (OR, 0.18; 95% CI, 0.04–0.75).

The rate of VTE episodes seems also exceptionally high in children and adolescent diagnosed with COVID-19. In the study of Whitworth et al,<sup>24</sup> including over 800 children and adolescents with asymptomatic SARS-CoV-2 infection, symptomatic COVID-19, and multisystem inflammatory syndrome in children, the rate of thrombosis was as high as 6.5% in the latter cohort, but was also slightly higher than 2% in children with symptomatic SARS-CoV-2 infection as opposed to 0.7% in those with asymptomatic infection. Major predictors of thrombosis were age > 12 years, presence of active cancer, central venous catheters, and high D-dimer values.

A direct and strong support to this epidemiological data emerges from postmortem studies, which investigated the burden of pulmonary thrombosis in patients who died with (or for) SARS-CoV-2 infection. The most important of such investigations has been performed by Carsana et al, at the beginning of the COVID-19 outbreaks in Northern Italy.<sup>25</sup> The analysis of lung tissues collected from 38 deceased COVID-19 patients revealed the presence of platelet-fibrin thrombi in the vast majority (i.e., 87%), frequently associated with inflammatory infiltrates, presence of megakaryocytes in lung capillaries, and mural fibrosis. Lung histopathology studies performed by Wichmann et al in 12 patients who died of COVID-19 also revealed that thromboembolic complications were rather frequent (present in up to 60% of cases), with isolated DVT and massive PE present in 25 and 33% of all patients.<sup>26</sup> Bussani et al also published a systematic postmortem analysis of 41 patients who died of COVID-19,<sup>27</sup> emphasizing that the extensive alveolar damage present in all patients was accompanied in the vast majority of cases (over 70%) by micro- and macrovascular thrombosis. Notably, blood clots appeared in different organizational stages within the pulmonary vessels, consistent with the hypothesis of local origin and growth. Important evidence that COVID-19 is a vascular disease also emerged from the study of Ackermann et al,<sup>28</sup> where lungs of seven patients who died of COVID-19 were autopsied and compared with those of patients who deceased for acute respiratory distress syndrome (ARDS) secondary to H1N1 Influenza virus infection. The main histopathological features in COVID-19 lungs were suggestive for the presence of vascular disease, including endothelial injury associated with intracellular virus, disrupted cell membranes, as well as widespread thrombosis with microangiopathy. Notably, the rate of alveolar capillary microthrombi was ninefold higher in COVID-19 than in H1N1 influenza tissues. Lungs of patients who died of COVID-19 also showed an amount of new vessel growth—mainly through a mechanism of angiogenesis—that was found to be nearly threefold higher than in the lungs of patients who died of influenza.

### Predisposing Factors of VTE in COVID-19

Another important aspect that needs to be highlighted, is that not only the onset of VTE is relatively high in patients

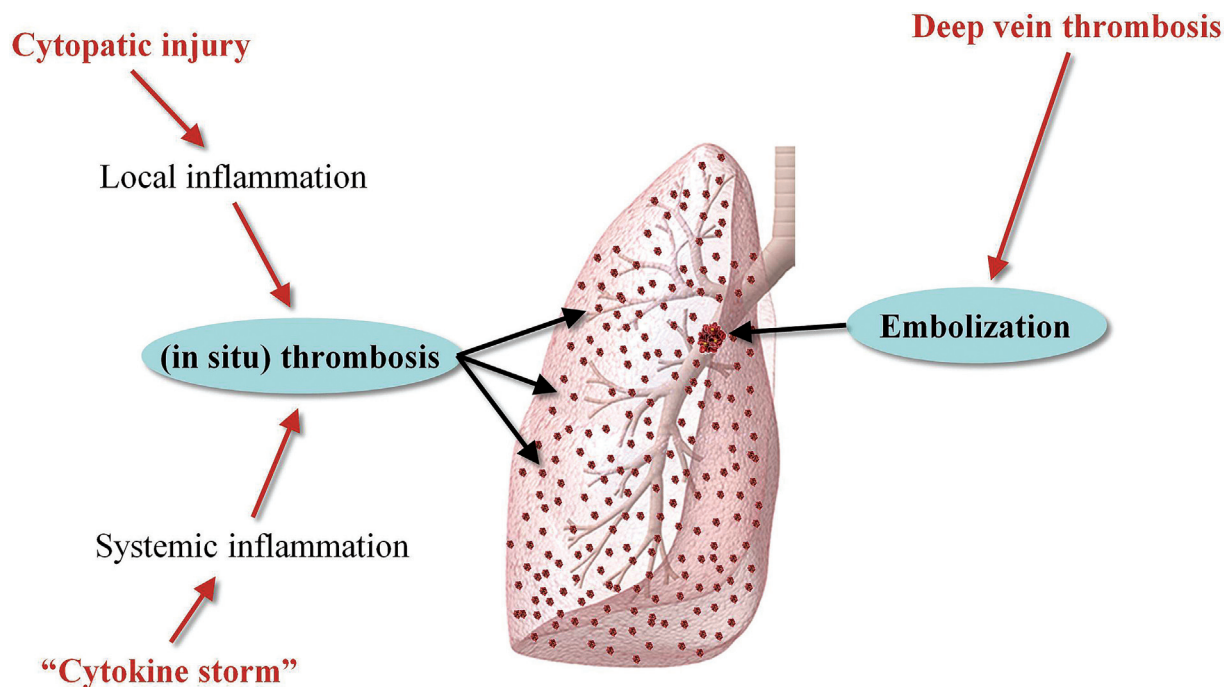
with SARS-CoV-2 infection, and is then associated with adverse outcome, but also a personal history of venous thrombosis was found to be a significant predictor of VTE in the large population study (over 300,000 participants) of Anderson et al.<sup>29</sup> The evidence that a positive history of venous thrombosis may influence the clinical outcome of COVID-19 is reinforced by data emerged from a genome-wide association study performed by Pathak et al,<sup>30</sup> which identified as many as 27 genes potentially associated with hospitalization of patients with SARS-CoV-2 infection, many of these related to coagulation pathways or inflammation and, most notably, associated with coagulation factor VIII (FVIII) and clinical phenotypes of VTE (e.g., *ABO*, *IFNAR2*, and *CCR1*).

The possible contribution of other conditions to increase the risk of PE in patients with SARS-CoV-2 infection has been also explored in the study of Gómez et al,<sup>31</sup> which concluded that such risk was nearly 60% higher in males, nearly fourfold higher in patients needing mechanical ventilation, and threefold higher in those admitted to the ICU. These findings were confirmed in another meta-analysis, which found that sex (male sex: OR, 1.49; 95% CI, 1.26–1.76), elevated body mass index (> 30: OR, 1.37; 95% CI, 1.03–1.82), use of mechanical ventilation (OR, 3.34; 95% CI, 1.90–5.86), ICU admission (OR, 2.65; 95% CI, 1.48–4.74), along with presence of severe parenchymal abnormalities (OR, 1.92; 95% CI, 1.43–2.58) were predictive factors of developing PE.<sup>32</sup> The presence and extent of pulmonary disease was confirmed to be an important factor in enhancing the risk of developing pulmonary thrombosis in the recent work of Elmokadem et al,<sup>33</sup> who showed that higher pulmonary severity score (based on assessment of interstitial opacity and air trapping) was associated with substantially enhanced risk of developing thromboembolic complications (OR, 2.6; 95% CI, 1.3–5.3).

### Pulmonary (In Situ) Thrombosis, Pulmonary Embolism, or Both?

Beside the evidence emerged from postmortem studies, which has already been discussed in an earlier part of this article, the considerable burden of thrombosis within the lung tissue of patients with severe SARS-CoV-2 infection has been underpinned in the study of Morris et al,<sup>34</sup> where the authors found a significant reduction in the percentage of blood vessels with cross-sectional area (between 1.25 and 5 mm<sup>2</sup>) in patients with COVID-19. Such reduction, which reflects the presence of severe microcirculatory disruption, was associated with significantly higher odds of intubation (OR, 3.20; 95% CI, 1.55–6.63), death (OR, 5.58; 95% CI 1.54–20.1), or both (OR, 2.54; 95% CI, 1.15–5.60).

These findings lead the way to important reflections on the pathogenesis of COVID-19, which specifically concerns the origin and type of thrombosis observed in the lung of patients with (especially) severe SARS-CoV-2 infection. The so-called “in situ” pulmonary thrombosis has been for long considered a rare, almost ephemeral phenomenon, whereby the vast majority of thrombotic pulmonary episodes have been attributed to embolization of thrombi generated in other venous districts (especially the lower limbs).<sup>35</sup>



**Fig. 1** Pathogenesis of pulmonary thrombosis in coronavirus disease 2019 (COVID-19).

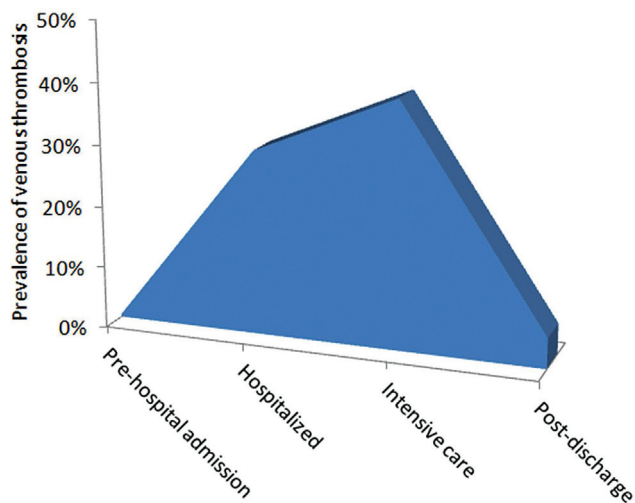
However, already in the pre-COVID era it has been hypothesized that a certain number of pulmonary thrombotic episodes may occur primarily “in situ,” as consequence of abnormalities in lung structures and/or pulmonary injuries leading to local inflammation and vascular dysfunction (e.g., pulmonary trauma, radiation therapy, lung blast injury, pulmonary infections, Behcet’s disease, among others).<sup>36</sup>

Several lines of evidence garnered from studies on the pathogenesis of SARS-CoV-2 infection converge now to unmask intriguing scenarios in the pathogenesis of pulmonary thrombosis, where development of blood clots may also occur primarily within the lung vasculature. It is now almost undeniable that the strong inflammatory state triggered and sustained by the viral infection and the consequent host immune response are important triggers of hemostasis activation, involving both primary and secondary hemostasis.<sup>37</sup> This is not really unexpected or unpredictable, as megakaryocytes are normally present in the lung tissue, and their number and activity seem both increased in patients with ARDS, thus actively contributing to the pathogenesis of COVID-related lung injury.<sup>38</sup> Evidence that SARS-CoV-2 infection may also directly cause microvascular disease has been clearly confirmed by laboratory and imaging studies, revealing that the von Willebrand factor/ADAMTS-13 (a disintegrin and metalloproteinase with thrombospondin type 1 motif) balance is often impaired in patients with severe COVID-19 illness,<sup>39</sup> and that “visible” pulmonary arterial thrombosis is often absent at pulmonary dual-energy computed tomography angiography evaluation.<sup>40</sup>

Importantly, Wang et al have recently shown that many thrombotic lesions in patients with COVID-19 originate in vessels around which the local inflammation is sustained and severe.<sup>41</sup> Nonetheless, segmental or subsegmental thrombosis could also be observed in nonconsolidation areas of the

lung, whose formation is thus perhaps attributable to hypercoagulability triggered by systemic rather than local inflammation. It can hence be concluded that at least three different phenotypes of pulmonary thrombosis may develop in COVID-19 patients, one due to classical embolization from peripheral venous thrombosis (e.g., DVT), a second type directly triggered by local inflammation of nearby infected pulmonary tissue, and a third one mostly attributable to the prothrombotic state consequent to pronounced systemic inflammatory response and noninfective cellular stress (i.e., the so-called cytokine storm) even outside pulmonary areas with active viral replication (► **Fig. 1**). This last type of thrombi is not exclusively found in the lungs, but may also be frequently observed in extrapulmonary tissues of patients who died of COVID-19, especially in the heart, brain, liver, spleen, and kidneys.<sup>42</sup> Although the pathogenesis of these three types of blood clots is seemingly different (► **Fig. 1**), their differentiation is essential since the diagnostic and therapeutic approaches will be considerably different. For example, in situ pulmonary thrombosis does not associate with DVT (except when both conditions independently coexist), so that lower limb ultrasonography would be most often inconclusive. Moreover, it cannot be discounted that hemodynamic deterioration may also be partially driven by mechanical ventilation.<sup>43</sup> The risk of developing lung injury in patients with SARS-CoV-2 infection undergoing mechanical ventilation has been recently summarized in the meta-analysis of Belletti et al,<sup>44</sup> who estimated that the frequency of barotrauma was as high as 15%, with over 60% associated mortality. Since this type of diffuse lung injury fosters the release of many inflammatory mediators, it is hence not surprising that the adoption of lung-protective ventilation strategies may help reduce the risk of developing unfavorable outcomes.<sup>45,46</sup>





**Fig. 2** Relative risk (%) of developing venous thrombosis throughout the course and recovery of coronavirus disease 2019 (COVID-19).

**Table 1** Risk factors for venous thrombosis and/or pulmonary embolism in patients with coronavirus disease 2019 (COVID-19)

Male sex
Obesity/overweight
Predisposition (inherited and/or acquired thrombophilia?)
Presence and extent of pulmonary disease
Hospitalization (and length of hospital stay)
Development of severe/critical illness
Mechanical ventilation
Intensive care unit admission
Increased values of inflammatory and thrombotic biomarkers

## Conclusion

Several lines of evidence now attest that the cumulative frequency of VTE can be as high as 30% in patients hospitalized for COVID-19, increasing to nearly 40 to 70% (depending on systematic screening) in those with severe illness, mechanical ventilation, or ICU admission (► **Fig. 2**). Such risk seems to be almost limited to the active phase of disease, and is directly associated with some genetic (i.e., inherited prothrombotic predisposition) and demographical factors (male sex, overweight/obesity), disease severity (risk increasing progressively from hospitalization to development of severe illness, being the highest in patients needing mechanical ventilation and/or intensive care), presence and extent of pulmonary disease and coexistence of multiple risk factors (immobilization, mechanical ventilation, co- or superinfections), along with increased values of inflammatory and thrombotic biomarkers (► **Table 1**). At least three different phenotypes of pulmonary thrombosis seem to develop in COVID-19, as described in ► **Fig. 1**, displaying different pathogenetic mech-

anisms. The prognosis of COVID-19 patients who develop pulmonary thrombosis is also considerably worse than those who do not, thus probably needing frequent monitoring and more aggressive therapeutic management.

Nonetheless, some gray zones remain, and which would require further scrutiny. These include, for example, which thrombophilic factors may be more strongly associated with the risk of developing venous thrombosis in patients with severe SARS-CoV-2 infection. Preliminary studies, such as that published by de la Morena-Barrio et al, provided inconclusive evidence on this matter.<sup>47</sup> It is now widely known that the local and systemic proinflammatory state found in many COVID-19 patients represent per se such a high prothrombotic condition that additional triggers may be perhaps unnecessary for fostering thrombosis. Nonetheless, it has been suggested that screening for inherited thrombophilia may help identifying patients at higher risk of developing more severe forms of VTE and/or in situ pulmonary thrombosis.<sup>48</sup> Then, the contribution of additional prothrombotic risk factors such as lipoprotein(a),<sup>49</sup> lupus anticoagulant,<sup>50</sup> and antiphospholipid antibodies,<sup>51</sup> would need to be more extensively assessed, since their active participation to the pathogenesis of COVID-19-associated coagulopathy may require specific treatments for reducing the risk of unfavorable outcomes.

The most appropriate anticoagulant and/or antiplatelet therapy throughout the clinical course of COVID-19 (i.e., from symptom onset to ICU admission) is an additional area of uncertainty, since several guidelines have been published, but not always provided overlapping indications.<sup>52–54</sup>

## Conflict of Interest

None declared.

## References

- Lippi G, Sanchis-Gomar F, Henry BM. Coronavirus disease 2019 (COVID-19): the portrait of a perfect storm. *Ann Transl Med* 2020; 8(07):497
- John Hopkins University & Medicine. John Hopkins Coronavirus Resource Center. Accessed November 23, 2021 at: <https://coronavirus.jhu.edu/map.html>
- Liu Y, Rocklöv J. The reproductive number of the Delta variant of SARS-CoV-2 is far higher compared to the ancestral SARS-CoV-2 virus. *J Travel Med* 2021;28(07):124
- Qiu X, Nergiz AI, Maraolo AE, Bogoch II, Low N, Cevik M. The role of asymptomatic and pre-symptomatic infection in SARS-CoV-2 transmission—a living systematic review. *Clin Microbiol Infect* 2021;27(04):511–519
- Lippi G, Sanchis-Gomar F, Henry BM. COVID-19: unravelling the clinical progression of nature's virtually perfect biological weapon. *Ann Transl Med* 2020;8(11):693
- Lippi G, Plebani M. Cytokine “storm”, cytokine “breeze”, or both in COVID-19? *Clin Chem Lab Med* 2020;59(04):637–639
- Jayarangaiah A, Kariyanna PT, Chen X, Jayarangaiah A, Kumar A. COVID-19-associated coagulopathy: an exacerbated immunothrombosis response. *Clin Appl Thromb Hemost* 2020; 26:1076029620943293
- Lippi G, Sanchis-Gomar F, Falavero EJ, Lavie CJ, Henry BM. Coronavirus disease 2019-associated coagulopathy. *Mayo Clin Proc* 2021;96(01):203–217

- 9 Falavero EJ, Lippi G. Maintaining hemostasis and preventing thrombosis in coronavirus disease 2019 (COVID-19): part II. *Semin Thromb Hemost* 2021;47(04):333–337
- 10 Poredos P, Poredos P. Involvement of inflammation in venous thromboembolic disease: an update in the age of COVID-19. *Semin Thromb Hemost* 2022;48(01):93–99
- 11 Antoniak S. The coagulation system in host defense. *Res Pract Thromb Haemost* 2018;2(03):549–557
- 12 Levi M, Thachil J. Coronavirus disease 2019 coagulopathy: disseminated intravascular coagulation and thrombotic microangiopathy—either, neither, or both. *Semin Thromb Hemost* 2020;46(07):781–784
- 13 Di Minno A, Ambrosino P, Calcaterra I, Di Minno MND. COVID-19 and venous thromboembolism: a meta-analysis of literature studies. *Semin Thromb Hemost* 2020;46(07):763–771
- 14 Liu Y, Cai J, Wang C, Jin J, Qu L. A systematic review and meta-analysis of incidence, prognosis, and laboratory indicators of venous thromboembolism in hospitalized patients with coronavirus disease 2019. *J Vasc Surg Venous Lymphat Disord* 2021;9(05):1099–1111.e6
- 15 Jenner WJ, Kanji R, Mirsadraee S, et al. Thrombotic complications in 2928 patients with COVID-19 treated in intensive care: a systematic review. *J Thromb Thrombolysis* 2021;51(03):595–607
- 16 Ho FK, Man KKC, Toshner M, et al. Thromboembolic risk in hospitalized and nonhospitalized COVID-19 patients: a self-controlled case series analysis of a nationwide cohort. *Mayo Clin Proc* 2021;96(10):2587–2597
- 17 Kollias A, Kyriakoulis KG, Lagou S, Kontopantelis E, Stergiou GS, Syrigos K. Venous thromboembolism in COVID-19: a systematic review and meta-analysis. *Vasc Med* 2021;26(04):415–425
- 18 Miró Ò, Jiménez S, Mebazaa A, et al; Spanish Investigators on Emergency Situations TeAm (SIESTA) network. Pulmonary embolism in patients with COVID-19: incidence, risk factors, clinical characteristics, and outcome. *Eur Heart J* 2021;42(33):3127–3142
- 19 Roubinian NH, Dusendang JR, Mark DG, et al. Incidence of 30-day venous thromboembolism in adults tested for SARS-CoV-2 infection in an integrated health care system in Northern California. *JAMA Intern Med* 2021;181(07):997–1000
- 20 Stals M, Grootenboers M, van Guldener C, et al; Dutch COVID, Thrombosis Coalition (DCTC) Risk of thrombotic complications in influenza versus COVID-19 hospitalized patients. *Res Pract Thromb Haemost* 2021;5(03):412–420
- 21 Engelen MM, Vandenbrielle C, Balthazar T, et al. Venous thromboembolism in patients discharged after COVID-19 hospitalization. *Semin Thromb Hemost* 2021;47(04):362–371
- 22 Ramos-Martínez A, Parra-Ramírez LM, Morrás I, et al. Frequency, risk factors, and outcomes of hospital readmissions of COVID-19 patients. *Sci Rep* 2021;11(01):13733
- 23 Li P, Zhao W, Kaatz S, Latack K, Schultz L, Poisson L. Factors associated with risk of postdischarge thrombosis in patients with COVID-19. *JAMA Netw Open* 2021;4(11):e2135397
- 24 Whitworth H, Sartain SE, Kumar R, et al. Rate of thrombosis in children and adolescents hospitalized with COVID-19 or MIS-C. *Blood* 2021;138(02):190–198
- 25 Carsana L, Sonzogni A, Nasr A, et al. Pulmonary post-mortem findings in a series of COVID-19 cases from northern Italy: a two-centre descriptive study. *Lancet Infect Dis* 2020;20(10):1135–1140
- 26 Wichmann D, Sperhake JP, Lütgehetmann M, et al. Autopsy findings and venous thromboembolism in patients with COVID-19: a prospective cohort study. *Ann Intern Med* 2020;173(04):268–277
- 27 Bussani R, Schneider E, Zentilin L, et al. Persistence of viral RNA, pneumocyte syncytia and thrombosis are hallmarks of advanced COVID-19 pathology. *EBioMedicine* 2020;61:103104
- 28 Ackermann M, Verleden SE, Kuehnel M, et al. Pulmonary vascular endothelialitis, thrombosis, and angiogenesis in Covid-19. *N Engl J Med* 2020;383(02):120–128
- 29 Anderson JJ, Ho FK, Niedzwiedz CL, et al. Remote history of VTE is associated with severe COVID-19 in middle and older age: UK Biobank cohort study. *J Thromb Haemost* 2021;19(10):2533–2538
- 30 Pathak GA, Singh K, Miller-Fleming TW, et al. Integrative genomic analyses identify susceptibility genes underlying COVID-19 hospitalization. *Nat Commun* 2021;12(01):4569
- 31 Gómez CA, Sun CK, Tsai IT, et al. Mortality and risk factors associated with pulmonary embolism in coronavirus disease 2019 patients: a systematic review and meta-analysis. *Sci Rep* 2021;11(01):16025
- 32 Cui LY, Cheng WW, Mou ZW, et al. Risk factors for pulmonary embolism in patients with COVID-19: a systemic review and meta-analysis. *Int J Infect Dis* 2021;111:154–163
- 33 Elmokadem AH, Bayoumi D, El-Morsy A, Ehab A, Abo-Hedibah SA. Relationship of the pulmonary disease severity scoring with thromboembolic complications in COVID-19. *Emerg Radiol* 2022;29(01):9–21
- 34 Morris MF, Pershad Y, Kang P, et al. Altered pulmonary blood volume distribution as a biomarker for predicting outcomes in COVID-19 disease. *Eur Respir J* 2021;58(03):2004133
- 35 Lippi G, Franchini M. Pathogenesis of venous thromboembolism: when the cup runneth over. *Semin Thromb Hemost* 2008;34(08):747–761
- 36 Cao Y, Geng C, Li Y, Zhang Y. *In situ* pulmonary artery thrombosis: a previously overlooked disease. *Front Pharmacol* 2021;12:671589
- 37 Thachil J, Srivastava A. SARS-2 coronavirus-associated hemostatic lung abnormality in COVID-19: is it pulmonary thrombosis or pulmonary embolism? *Semin Thromb Hemost* 2020;46(07):777–780
- 38 Thachil J, Lisman T. Pulmonary megakaryocytes in coronavirus disease 2019 (COVID-19): roles in thrombi and fibrosis. *Semin Thromb Hemost* 2020;46(07):831–834
- 39 Falavero EJ, Henry BM, Lippi G. Increased VWF and decreased ADAMTS-13 in COVID-19: creating a milieu for (micro)thrombosis. *Semin Thromb Hemost* 2021;47(04):400–418
- 40 Grillet F, Busse-Coté A, Calame P, Behr J, Delabrousse E, Aubry S. COVID-19 pneumonia: microvascular disease revealed on pulmonary dual-energy computed tomography angiography. *Quant Imaging Med Surg* 2020;10(09):1852–1862
- 41 Wang L, Chen F, Bai L, Yi Q, Peng Y. *In situ* pulmonary thrombosis in patients with COVID-19 pneumonia: different phenotypes may exist. *Thromb Res* 2020;196:541–542
- 42 Satturwar S, Fowkes M, Farver C, et al. Postmortem findings associated with SARS-CoV-2: systematic review and meta-analysis. *Am J Surg Pathol* 2021;45(05):587–603
- 43 Tsolaki V, Zakyntinos GE, Mantzarlis K. Right ventricular dilation: the additive effect of mechanical ventilation on pulmonary embolism in Covid-19 patients. *Thromb Res* 2020;196:25–26
- 44 Belletti A, Todaro G, Valsecchi G, et al. Barotrauma in coronavirus disease 2019 patients undergoing invasive mechanical ventilation: a systematic literature review. *Crit Care Med* 2022;50(03):491–500
- 45 Haitsma JJ, Schultz MJ, Hofstra JJ, et al. Ventilator-induced coagulopathy in experimental *Streptococcus pneumoniae* pneumonia. *Eur Respir J* 2008;32(06):1599–1606
- 46 Rajdev K, Spanel AJ, McMillan S, et al. Pulmonary barotrauma in COVID-19 patients with ARDS on invasive and non-invasive positive pressure ventilation. *J Intensive Care Med* 2021;36(09):1013–1017
- 47 de la Morena-Barrío ME, Bravo-Pérez C, de la Morena-Barrío B, et al. A pilot study on the impact of congenital thrombophilia in COVID-19. *Eur J Clin Invest* 2021;51(05):e13546

- 48 El Hasbani G, Taher AT. Should we screen Eastern Mediterranean COVID-19 patients for inherited thrombophilia? *Med Hypotheses* 2021;152:110621
- 49 Lippi G, Szergyuk I, de Oliveira MHS, et al. The role of lipoprotein (a) in coronavirus disease 2019 (COVID-19) with relation to development of severe acute kidney injury. *J Thromb Thrombolysis* 2021;1–5
- 50 Favaloro EJ, Henry BM, Lippi G. Is lupus anticoagulant a significant feature of COVID-19? A critical appraisal of the literature. *Semin Thromb Hemost* 2022;48(01):55–71
- 51 Favaloro EJ, Henry BM, Lippi G. COVID-19 and antiphospholipid antibodies: time for a reality check? *Semin Thromb Hemost* 2022;48(01):72–92
- 52 Bikdeli B, Madhavan MV, Jimenez D, et al; Global COVID-19 Thrombosis Collaborative Group, Endorsed by the ISTH, NATE, ESVM, and the IUA, Supported by the ESC Working Group on Pulmonary Circulation and Right Ventricular Function. COVID-19 and thrombotic or thromboembolic disease: implications for prevention, antithrombotic therapy, and follow-up: JACC State-of-the-Art Review. *J Am Coll Cardiol* 2020;75(23):2950–2973
- 53 Flaczyk A, Rosovsky RP, Reed CT, Bankhead-Kendall BK, Bittner EA, Chang MG. Comparison of published guidelines for management of coagulopathy and thrombosis in critically ill patients with COVID 19: implications for clinical practice and future investigations. *Crit Care* 2020;24(01):559
- 54 Narasimhan B, Lorente-Ros M, Aguilar-Gallardo JS, et al. Anticoagulation in COVID-19: a review of current literature and guidelines. *Hosp Pract (1995)* 2021;49(05):307–324