

This article is licensed under the Creative Commons Attribution-NonCommercial 4.0 International License (CC BY-NC) (<http://www.karger.com/Services/OpenAccessLicense>). Usage and distribution for commercial purposes requires written permission.

Single Case

When Diarrhea Can Become Deadly: Legionnaires' Disease Complicated by Bowel Obstruction

Wesley Prichard Laurel Fick

Internal Medicine Faculty Department of Internal Medicine, St. Vincent Hospital,
Indianapolis, IN, USA

Keywords

Legionnaires' disease · Legionella · Bowel obstruction · Extrapulmonary *Legionella*

Abstract

Legionnaires' disease may present with a broad spectrum of illnesses and nonspecific extrapulmonary symptoms including diarrhea. To our knowledge, bowel obstruction has not been reported as a manifestation of *Legionella*. We present a unique case of Legionnaires' disease contributing to a small bowel obstruction.

© 2016 The Author(s)
Published by S. Karger AG, Basel

Introduction

Legionella pneumophila is a gram-negative bacillus which can cause atypical pneumonia in human hosts. The pathogen was first discovered in 1976 during an epidemic in Philadelphia among American Legion members, dubbing "Legionnaires' disease" [1–3]. There are many species of *Legionella*, but *L. pneumophila* is thought to cause more severe disease than the more common bacteria contributing to community-acquired pneumonia [2]. An intracellular and facultative pathogen, this bacterium lives within amoebae as a parasite and freely replicates within host macrophages which gives it the ability to survive the harsh environment and allows dissemination throughout the host [1–3]. Incubation time is 2–10 days for

development of the pneumonic form. An estimated 25,000–100,000 persons are affected annually in the United States with this dangerous bacterium [4].

Infection with *Legionella* can be acquired by inhalation or aspiration of a contaminated water source including freshwater ponds and creeks, cooling towers, air conditioning systems, water fountains, respiratory-therapy equipment, and humidifiers – explaining both the community-acquired and nosocomial routes of transmission [2, 3]. Patient risk factors for contraction include smoking, alcohol use, chronic lung disease, end-stage renal disease, diabetes, malignancy, and immunosuppression (i.e. HIV/AIDS) [2, 3, 5]. Community-acquired *Legionella* patients typically have extrapulmonary manifestations initially and seek medical care much later following initial infection [6]. With delayed or inappropriate antibiotic use against *Legionella*, mortality has been reported to be around 60–70%, but appropriate and rapid initiation of treatment decreases mortality to 10–20% [7]. A urinary antigen test for *L. pneumophila* serogroup 1, which accounts for 90% of *Legionella* infections, has a sensitivity of 70% and a specificity of 100% [1]. Treatment with macrolides and fluoroquinolones is considered the first-line therapy for this bacterium [5].

Legionnaires' disease may begin with a broad spectrum of illnesses and nonspecific symptoms: fever, nonproductive cough, malaise, myalgia, anorexia, and headache. This constellation of symptoms can ultimately progress into respiratory and multi-organ failure [1, 8]. The extrapulmonary symptoms include neurologic changes, rhabdomyolysis, acute renal failure, electrolyte abnormalities, and various gastrointestinal manifestations [1, 2, 8, 9]. Multiple gastrointestinal symptoms from *Legionella* have been reported, including nausea, vomiting, elevated transaminases, secretory diarrhea (20–40%), peritonitis, and even hemorrhage secondary to stress ulcers [2, 3, 9]. To our knowledge, this is the first reported case of bowel obstruction attributed to *Legionella* infection.

Case Presentation

A 67-year-old female with osteoporosis, hypothyroidism, and a remote abdominal hysterectomy presented to the emergency department with a chief complaint of 2 days of vomiting, watery diarrhea, confusion, lethargy, and high fever. Her system review was negative for respiratory or other abdominal complaints. Her medications consisted of levothyroxine and vitamin D with calcium supplements. Her social history was benign: she was a non-smoker, nondrinker, and lived independently with her husband. On initial evaluation in the emergency department, she was hemodynamically stable (heart rate 97, blood pressure 163/76), but febrile at 103°F and mildly tachypneic. Her physical examination demonstrated dry mucous membranes and diminished breath sounds at the left base of her lungs but was otherwise nonfocal – including a benign abdominal examination (soft, nontender, non-distended, normal bowel sounds). Her laboratory examinations demonstrated a moderate leukocytosis (14,000 K/cumm) with 9% bands, elevated creatinine (1.28 mg/dL, baseline 0.8 mg/dL) and BUN (22 mg/dL), lactate 3.74 mmol/L, creatinine phosphokinase 15,445 U/L, hyperglycemia 249 mg/dL, and elevated transaminases (ALT 91 U/L, AST 170 U/L, alkaline phosphatase 137 U/L, total bilirubin 2.0 mg/dL with direct bilirubin 1.2 mg/dL) with negative lipase (9 U/L) and albumin 3.0 gm/dL. Urinalysis was significant for occult blood, protein of 100 mg/dL, and urine ketones.

She was admitted for sepsis, dehydration, and rhabdomyolysis, all from presumed viral gastroenteritis. A chest X-ray (Fig. 1) revealed a questionable left lower lobe pulmonary opacity. After a right upper quadrant ultrasound demonstrated no significant hepatobiliary

pathology, she underwent a computerized tomography (CT) of the abdomen and pelvis. The CT failed to pinpoint an etiology for her abdominal symptoms but confirmed a dense left lower lobe pulmonary infiltrate. Community-acquired pneumonia antibiotic coverage was initiated with azithromycin and piperacillin/tazobactam (the latter for possible aspiration with her confusion), and she was aggressively hydrated with normal saline. Hepatitis panel, TSH (1.77 UIU/mL), and hemoglobin A1c (5.7%) were unremarkable. After 2 days on antibiotics with persistent fever and gastrointestinal symptoms, urine *Legionella* antigen was ordered and subsequently positive on day 3 of admission. Her antibiotics were changed to levofloxacin upon detection, but her nausea and vomiting acutely worsened along with severe abdominal distension. An abdominal X-ray (Fig. 2) demonstrated multiple dilated small bowel loops consistent with intestinal obstruction. A repeat CT of the abdomen and pelvis (Fig. 3) for further characterization confirmed a high-grade partial small bowel obstruction with a transition point in the distal ileum. She clinically improved with conservative management of her intestinal obstruction with nasogastric suction and intravenous fluid resuscitation while completing a course of antibiotics for *L. pneumophila* infection.

Discussion

The most common risk factors for the development of intestinal obstruction include previous abdominal surgery, neoplasms, hernias, electrolyte abnormalities, and medications [10]. While our patient had a remote history of hysterectomy, other identifiable risk factors causing her distension (including opioid medications) were not present in her care. A normal abdominal CT 3 days before the obstruction makes it unlikely that an anatomical defect was contributory. These findings lead us to believe that her legionellosis was primarily responsible for the development of this potentially fatal complication. As this complication has not previously been reported, the exact mechanism is unknown; however, we hypothesize that this may be directly attributable to specific systemic responses observed in *Legionella* infection. The host's cell-mediated immune response becomes activated when the bacterium invades macrophages for replication, thus initiating an overwhelming immune cascade triggered by its lipopolysaccharide, lipid A, component on its outside membrane [11]. Lipid A directly stimulates tumor necrosis factor alpha (TNF α) production, which causes massive cytokine release and is primarily responsible for chloride secretion and subsequent development of diarrhea and intestinal inflammation [1, 11–14]. We hypothesize that our patient's TNF α response directly caused massive gut inflammation and edema leading to hypoperfusion and subsequent intestinal obstruction. It is important that clinicians be aware of this complication of *Legionella* infection, especially in patients with a history of previous abdominal surgery.

Statement of Ethics

Approval for the use of this case was obtained by the patient and the St. Vincent Institutional Review Board.

Disclosure Statement

The authors have no conflicts of interest to disclose.

References

- 1 Winn WC Jr: Legionella; in Baron S (ed): Medical Microbiology, ed 4. Galveston, University of Texas Medical Branch at Galveston, 1996, chapt 40. Available from: <http://www.ncbi.nlm.nih.gov/books/NBK7619/>.
- 2 Stout JE, Yu VL: Legionellosis. N Engl J Med 1997;337:682–687.
- 3 Dahdouh M, Grantham C, Kay S: Atypical presentation of legionnaire's disease: a case report and review. New York Med J 2007. <http://newyorkmedicaljournal.org/articles/atypical-presentation-of-legionnaires-disease/>.
- 4 Steinert M, Hentschel U, Hacker J: Legionella pneumophila: an aquatic microbe goes astray. FEMS Microbiol Rev 2002;26:149–162.
- 5 Calza L, Briganti E, Casolari S, Manfredi R, et al: Legionnaires' disease associated with macular rash: two cases. Acta Derm Venereol 2005;85:342–344.
- 6 Pedro-Botet ML, Sabria-Leal M, Haro M, Rubio C, et al: Nosocomial and community-acquired Legionella pneumonia: clinical comparative analysis. Eur Respir J 1995;8:1929–1933.
- 7 Kassha K, Abuanza I, Hadi SA, Hilton R: Severe Legionnaires disease complicated by multi-organ dysfunction in previously healthy patient: a case report. Cases J 2009;2:9151.
- 8 Vergis E, Akbas E, Yu VL: Legionella as a cause of severe pneumonia. Semin Respir Crit Care Med 2000;21:295–304.
- 9 Van Riemsdijk-van Overbeeke I, Van den Berg B: Severe Legionnaire's disease requiring intensive care treatment. Neth J Med 1996;49:196–201.
- 10 Jackson P, Raiji M: Evaluation and management of intestinal obstruction. Am Fam Physician 2011;83:159–165.
- 11 Bishop R: The lipid A palmitoyltransferase PagP: molecular mechanisms and role in bacterial pathogenesis. Mol Microbiol 2005;57:900–912.
- 12 Cramer M: Legionnaires disease: a case study. Am J Crit Care 2003;12:234–238.
- 13 Hofmann A, Beaulieu Y, Bernard F, Rico P: Fulminant legionellosis in two patients treated with infliximab for Crohn's disease: case series and literature review. Can J Gastroenterol 2009;23:829–833.
- 14 Reisinger EC, Fritzsche C, Krause R, Krejs GJ: Diarrhea caused by primarily non-gastrointestinal infections. Nat Clin Pract Gastroenterol Hepatol 2005;2:216–222.

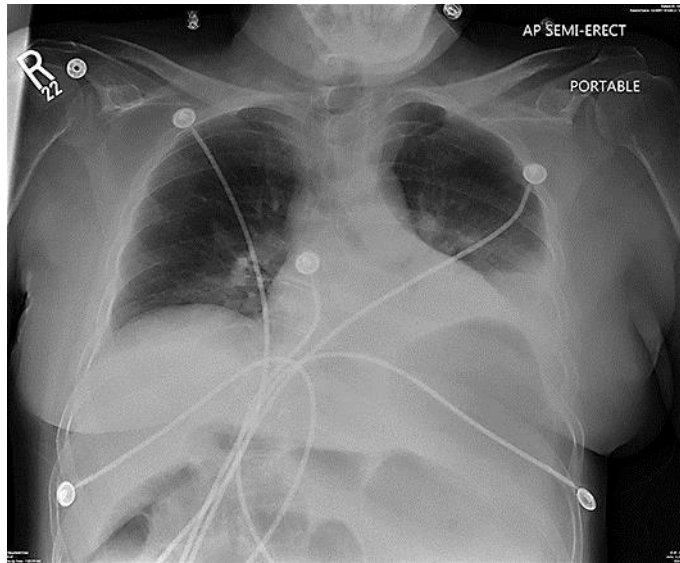


Fig. 1. Chest X-ray with left base opacity.

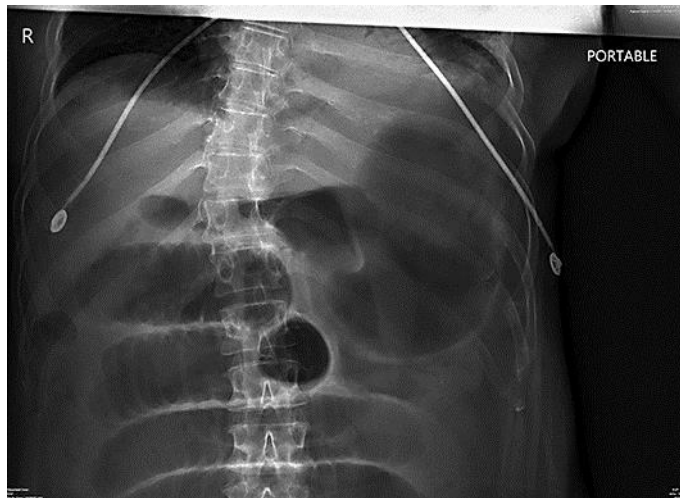

Fig. 2. Abdominal X-ray demonstrating obstruction.

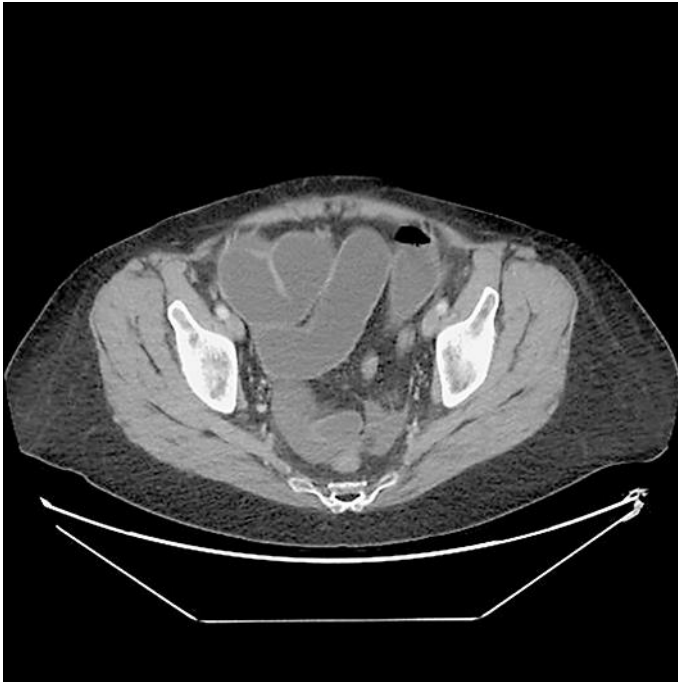

Fig. 3. Abdominal/pelvic CT of small bowel obstruction with transition point.