

# White matter abnormalities in drug-naïve patients with obsessive–compulsive disorder: a Diffusion Tensor Study before and after citalopram treatment

Yoo SY, Jang JH, Shin Y-W, Kim DJ, Park H-J, Moon W-J, Chung EC, Lee J-M, Kim IY, Kim SI, Kwon JS. White matter abnormalities in drug-naïve patients with obsessive–compulsive disorder: a Diffusion Tensor Study before and after citalopram treatment.

**Objective:** The aim was to investigate the white matter abnormalities of drug-naïve patients with obsessive–compulsive disorder (OCD) using diffusion tensor-imaging and the white matter changes in the patients after pharmacotherapy.

**Method:** Thirteen drug-naïve OCD patients and 13 age- and sex-matched healthy comparison subjects were examined using diffusion tensor-imaging and structural magnetic resonance imaging. Measurements were made in OCD patients before and after 12 weeks of citalopram treatment.

**Results:** Compared with controls, the drug-naïve OCD patients showed significant increases in fractional anisotropy (FA) in the corpus callosum, the internal capsule and white matter in the area superolateral to the right caudate. The increases in FA were mostly no longer observed in patients after 12 weeks of treatment compared with controls.

**Conclusion:** Our findings suggest that white matter alterations are associated with the pathophysiology of OCD, and the abnormalities may be partly reversible with pharmacotherapy.

S. Y. Yoo<sup>1</sup>, J. H. Jang<sup>1</sup>, Y.-W. Shin<sup>1</sup>,  
D. J. Kim<sup>2</sup>, H.-J. Park<sup>3</sup>,  
W.-J. Moon<sup>4</sup>, E. C. Chung<sup>5</sup>,  
J.-M. Lee<sup>2</sup>, I. Y. Kim<sup>2</sup>, S. I. Kim<sup>2</sup>,  
J. S. Kwon<sup>1</sup>

<sup>1</sup>Department of Psychiatry, Seoul National University College of Medicine, Seoul, <sup>2</sup>Department of Biomedical Engineering, Hanyang University, Seoul, Korea,

<sup>3</sup>Department of Radiology, Yonsei University College of Medicine, Seoul, <sup>4</sup>Department of Radiology, Kun Kook University College of Medicine, Seoul and <sup>5</sup>Department of Radiology, Samsung Medical Center, Sungkyunkwan University School of Medicine, Seoul, Korea.

Key words: obsessive–compulsive disorder; diffusion magnetic resonance imaging; citalopram

Jun S. Kwon, Department of Psychiatry, Seoul National University College of Medicine, 28 Yeongno-dong, Chongno-gu, Seoul 110-744, Korea.

E-mail address: kwonjs@plaza.snu.ac.kr

Accepted for publication April 11, 2007

## Significant outcomes

- Results suggest that white matter alterations are associated with the pathophysiology of obsessive–compulsive disorder.
- White matter alterations in obsessive–compulsive disorder may be partly reversible with pharmacotherapy.

## Limitations

- The small sample size in each group may be related to type II errors potentially causing false negative results such as lack of difference in the white matter integrity in other regions and the absence of significant correlations between OC symptoms and FA values.
- The treatment period was relatively short.

## Introduction

Neuroanatomical studies of obsessive–compulsive disorder (OCD) have reported various regional

abnormalities in the gray matter, including the orbitofrontal cortex, basal ganglia, thalamus, and, sometimes, the parietal cortex (1–4). In addition, functional neuroimaging studies have shown

abnormal hyperactivation in the prefrontal cortex, cingulate cortex, basal ganglia, and thalamus in most neutral-state (5–7) and symptom-provocation tasks (8–10). These findings have implicated a dysfunctional cortico-striato-thalamo-cortical circuit in the pathophysiology of OCD, rather than a deficit in distinct regions. The cortical and sub-cortical regions in this circuit are physically and functionally connected through the white matter. Therefore, the white matter in patients with OCD might show some alterations associated with the dysfunction of the cortico-striato-thalamo-cortical circuit at the microstructural level.

Some neuroimaging studies have examined the white matter in OCD, using morphometric measurements and reported inconsistent findings, such as no significant difference in the frontal and anterior cingulate white matter regions (11, 12) and reduced white matter volume in the sub-cortical occipito-temporal region of the right hemisphere (13) or in the posteroinferior pericallosal, retrocallosal, and cerebellar regions in OCD patients compared with healthy controls (14). In addition to volume studies, a larger corpus callosum (15) and greater white matter concentration in the anterior genu of the corpus callosum (16) were observed in drug-naïve pediatric patients with OCD and higher concentration of parietal Cho/Cr was reported in parietal white matter of OCD patients (17).

Diffusion tensor-imaging (DTI) is a non-invasive technique allowing the *in vivo* examination of the white matter fiber tract integrity through fractional anisotropy (FA). Compared with volumetric measurements, this method is potentially more sensitive to detecting subtle and early changes in the microstructure and organization of white matter fiber tracts. Recently, one study showed that the FA was lower bilaterally in the anterior cingulate gyrus white matter and the parietal region, right posterior cingulate gyrus, and left occipital lobe in medicated patients with OCD, compared with healthy volunteers, whereas no areas with a significantly higher FA were observed (18).

To the best of our knowledge, however, the white matter integrity in drug-naïve OCD patients has not yet been investigated. Because many studies have reported that pharmacological treatment affects the regional volumes (19), glucose metabolism (6, 20–25), and chemical metabolism (26) in the brain of OCD patients, it may be meaningful to investigate the white matter connectivity in drug-naïve OCD patients and the effect of pharmacotherapy to understand the pathophysiology of OCD.

#### Aims of the study

The aims of this study were to investigate white matter abnormalities in drug-naïve OCD patients compared with healthy controls using DTI and to reveal whether the abnormal structural integrity would change on treatment with citalopram. Instead of a region-of-interest approach, we used a voxel-based analysis to detect changes in the white matter throughout the brain. We hypothesized that white matter integrity in OCD would increase in some regions of cortico-striato-thalamic circuits. We also predicted that sufficient treatment would normalize the alterations of white matter integrity.

#### Material and methods

##### Participants

The subjects had participated in our previous proton magnetic resonance spectroscopic imaging (<sup>1</sup>H-MRSI) study (26). Detailed subjects and pharmacotherapy protocol have been described in that report. Briefly, 13 patients (eight men, five women) who fulfilled the DSM-IV criteria for OCD, as diagnosed with the Structured Clinical Interview for DSM-IV Axis I disorders (SCID-I) (27) and 13 sex- and age-matched normal controls were recruited. There were no significant differences with regard to age (mean  $\pm$  SD age,  $27.8 \pm 7.3$  for OCD patients;  $26.9 \pm 7.0$  for controls;  $t_{24} = -0.33$ ;  $P = 0.75$ ), or mean IQ ( $109.8 \pm 13.4$  for OCD patients;  $117.4 \pm 15.9$  for controls;  $t_{24} = 1.32$ ;  $P = 0.20$ ), as estimated by the Korean version of Wechsler Adult Intelligence Scale (K-WAIS) (28). All subjects were right-handed Koreans. The clinical characteristics of the patients sample are presented in Table 1. Two of the OCD patients had major depressive disorders and one patient had dysthymic disorder as comorbidity. Patients were drug-naïve except one who had taken medication for a few days, several years prior to the study. The present study was approved by the local institutional review board, and written informed consent was obtained from all the subjects after the procedures were fully explained.

For the 12-week pharmacotherapy, citalopram treatment was started at 10 mg/day, and titrated up to 60 mg/day by the sixth week, increasing by 10 mg every week. It was then maintained at 60 mg/day until the end of the 12-week pharmacotherapy regimen.

The OCD symptom severity was measured using the Yale-Brown Obsessive Compulsive Scale (Y-BOCS) (29). The Hamilton Depression Rating

Table 1. Demographic and clinical characteristics of patients with OCD and controls

	Patients with OCD ( <i>n</i> = 13)	Controls ( <i>n</i> = 13)	Analysis	
			<i>t</i> -score	<i>P</i> -value
Demographic characteristics				
Sex (M/F)	8/5	8/5		
Age (years), mean (SD)	27.8 (7.3)	26.9 (7.0)	-0.33	0.75
Education (years), mean (SD)	15.3 (1.8)	15.1 (2.9)	-0.24	0.81
Estimated IQ	109.8 (13.4)	117.4 (15.9)	1.32	0.20
Clinical characteristics				
Illness duration (years), mean (SD)	7.2 (9.0)			
	Pretreatment	Post-treatment		
YBOCS score, mean (SD)	30.2 (4.6)	16.6 (6.4)	-	8.76 <0.001
HDRS score, mean (SD)	12.5 (7.6)	6.2 (4.6)	-	3.14 0.009
BAI score, mean (SD)	22.2 (12.2)	11.5 (7.9)	-	3.80 0.003
BDI score, mean (SD)	17.9 (9.8)	9.2 (7.1)	-	3.68 0.003

SD, standard deviation; Y-BOCS, Yale-Brown Obsessive Compulsive Scale; BAI, Beck Anxiety Inventory; BDI, Beck Depression Inventory; HDRS, Hamilton Depression Rating Scale; OCD, obsessive-compulsive disorder.

Scale (HDRS) (30), the Beck Depression Inventory (BDI) (31), and the Beck Anxiety Inventory (BAI) (32) were also administered both before and after pharmacotherapy.

Diffusion tensor-imaging scans were performed on patients before and after pharmacotherapy and healthy controls, also, all patients completed the procedures and evaluation without dropouts.

#### Image-acquisition

Three-dimensional T1-weighted magnetic resonance imaging (MRI) and DTI studies were performed, using a 1.5-T MR scanner (Philips Medical Systems, Best, the Netherlands). Firstly, we acquired a high-resolution 3D T1-weighted MRI volume data set with the following parameters: repetition time (TR) 25 ms, echo time (TE) 6.9 ms, flip angle 40°, 256 × 256 acquisition matrix, and 240-mm field of view, contiguous 150 axial slices.

In the whole-brain DT-MRI examination, sets of axial diffusion-weighted single-shot echo-planar images were collected with the following parameters: 128 × 128 acquisition matrix, 1.71 × 1.71 × 4 mm<sup>3</sup> voxels; reconstructed to 0.86 × 0.86 × 4 mm<sup>3</sup>; 40 axial slices; 220-mm field of view; TE 62 ms, TR 7390 ms; Flip angle 90°; slice gap 0 mm; 3 averaging per slice; *b*-factor of 600 smm<sup>-2</sup>. With the baseline image without weighting [0, 0, 0], diffusion-weighted images were acquired from six different directions.

All axial sections were acquired parallel to the anterior commissure-posterior commissure line.

#### Data-processing

Magnitude Fourier-transformed images were transferred in DICOM format, then converted into ANAYZE 6.0 (Mayo foundation, Rochester,

MN, USA) readable form, using in-house written Matlab (MathWorks Inc., Natick, MA, USA) routines. The diffusion-weighted images were corrected for spatial distortions induced by eddy currents using the modified SPM99 (Wellcome Department of Cognitive Neurology, Institute of Neurology, University College London, UK) algorithm to minimize mutual information between the diffusion-unweighted and -weighted images. Diffusion tensor matrices from sets of seven diffusion-weighted images were generated and then, the three eigenvalues ( $\lambda_i = 1, 2, 3$ ) and eigenvectors ( $\epsilon_i = 1, 2, 3$ ) were calculated via matrix diagonalization. FA maps were generated according to the conventional method (33).

Image-processing methods were based on a voxel-based morphometry technique (34) and implemented in SPM2 (<http://www.fil.ion.ucl.ac.uk/spm/>). A standard template was created specifically for the study in order to match more closely the population under investigation and the image-acquisition protocols used by Good et al. (34) For the customized template creation, the  $B_0$  DTI volumes from the OCD patients and the control subjects were spatially normalized to the standard T2-MRI template, based on 152 healthy subjects from the Montreal Neurological Institute. The spatially normalized  $B_0$  images were averaged to provide the template in stereotactic space. Subsequently, the  $B_0$  images from all OCD patients and control subjects were spatially normalized to the customized template. The parameters resulting from this spatial normalization step were then applied to the FA map of each subjects. Thus, we obtained 26 FA maps of matrix size and voxel size 2 × 2 × 2 mm<sup>3</sup> in common Talairach space. Both the registered FA images were smoothed with an isotropic Gaussian kernel (10-mm full width at half maximum).

## Statistical analyses

Between-group statistical comparisons of demographic variables were performed with independent *t*-tests. Paired *t*-tests were employed to compare pre- to post-treatment Y-BOCS scores, BAI scores, HDRS scores and BDI scores in OCD patients. A level of  $P < 0.05$  was considered to be significant.

These smoothed images for patients with OCD and controls were compared using voxel-wise *t*-test statistics. The *t*-test and paired *t*-test were done to be compared with FA images between drug-naïve patients with OCD and controls and between before and after 12-week treatment within the patient group. The SPM (*t*) maps were then transformed to the unit normal distribution and thresholded at  $P < 0.001$  (uncorrected) and only the clusters of more than 20 contiguous voxels were considered in the analysis. This combination of  $\alpha$  level and cluster size was chosen to provide protection against type I error.

To investigate the correlation between the FA values and clinical characteristics, we examined the correlates using Spearman's rank correlation coefficient ( $r_s$ ). The FA values were computed in the regions showing higher or lower FA within the patient group compared with controls using a volume of interest (VOI) module of SPM2. Furthermore, the correlations between the changes of FA values from baseline to follow-up and the changes of the clinical measures were investigated.

## Results

All clinical measures in the OCD patients improved significantly after 12 weeks of citalopram treatment (Table 1). On comparing drug-naïve OCD patients and controls, significantly higher FA in the OCD patients was observed in the corpus callosum extending to the temporal lobe (tapetum), the white matter around the lentiform nucleus, including the posterior limb and retrolen-

ticular part of the internal capsule bilaterally, and the lateral aspect of the right caudate nucleus (Table 2, Fig. 1). Significantly lower FA was not observed in any part of the brain white matter in drug-naïve OCD patients compared with control subjects. We also compared the FA maps between only 10 OCD patients without comorbid mood disorder and 13 healthy controls to determine whether the comorbid mood disorder impacts the FA differences. We did not find significant difference between the result of all patients and the result of patients with OCD alone.

Examination of the change in FA in the OCD patients with pharmacotherapy revealed a significant pre- to post-treatment decrease in FA in the posterior thalamic radiation on the right parietal lobe (Fig. 2). The Talairach co-ordinates representing the centroid ( $x =$  right,  $y =$  anterior, and  $z =$  superior) were  $x = 34$ ,  $y = -41$ , and  $z = 30$ , and the cluster size was 34 voxels. However, pharmacotherapy did not lead to an increase in FA in any brain region in the patients. In addition, no increases in FA in drug-naïve OCD patients, compared with healthy controls, were observed after 12 weeks of treatment, except for the body of the left corpus callosum (44 voxels, maximal *Z*-score = 3.56, co-ordinates<sub>*x,y,z*</sub> = -30, -38, 24) and the right superior temporal region (53 voxels, maximal *Z*-score = 3.94, co-ordinates<sub>*x,y,z*</sub>: 42, -24, 12) (Fig. 3).

We also examined the clinical correlates of FA within the drug-naïve OCD patient group. We computed the average FA values for each of the six regions in which the FA differed significantly between the two groups. These investigations showed that none of the clinical measures, such as the Y-BOCS, HDRS, BDI, and BAI, was significantly correlated to FA. Furthermore, the change in FA in the regions showing FA differences from the baseline to the follow-up was not correlated to the changes in the scores of the clinical measures and not with clinical character-

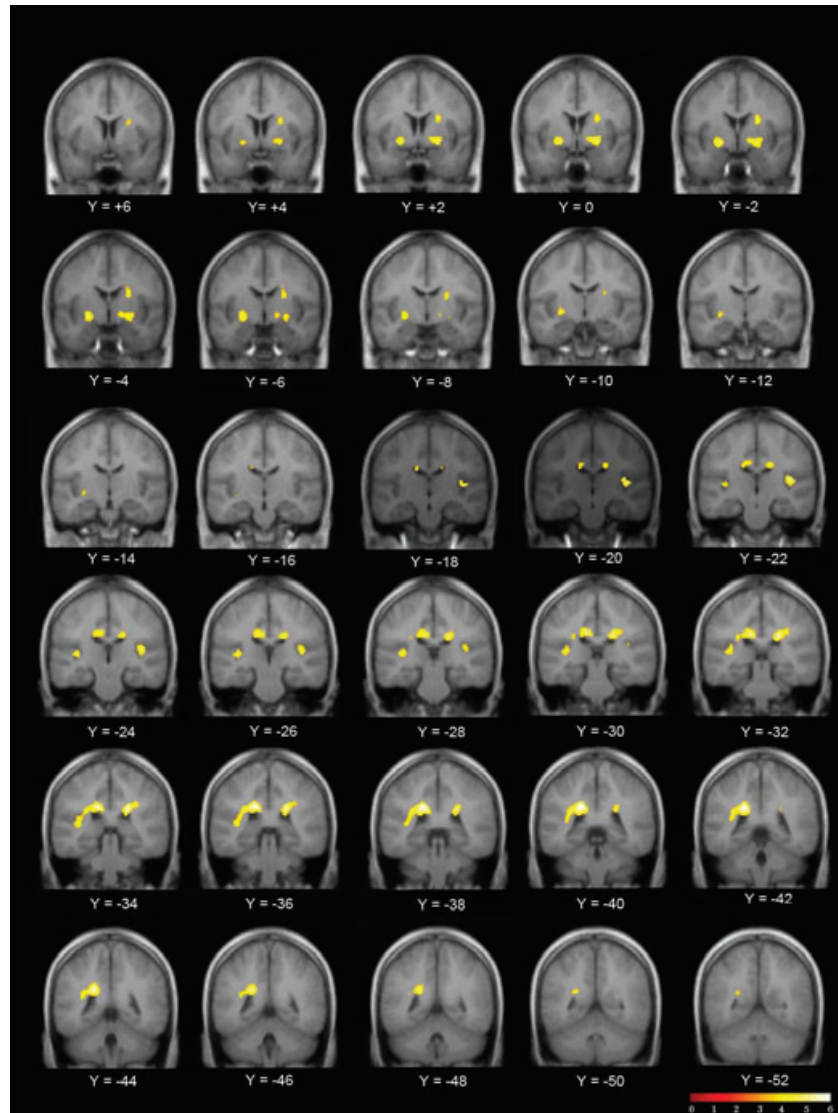
Region	Peak co-ordinates ( <i>x, y, z</i> ) <sup>*</sup>			Voxel number	<i>Z</i> -score
Left corpus callosum extending into temporal lobe	-18	-38	30	979	4.64
Left retrolenticular part of internal capsule	-40	-28	10		4.44
Right corpus callosum	22	-32	27	314	4.43
Right retrolenticular part of internal capsule <sup>†</sup>	42	-21	10	126	4.04
Left posterior limb of internal capsule	-22	-2	-7	190	3.97
Right posterior limb of internal capsule	22	0	-7	200	3.93
Supero-lateral area of the right caudate nucleus	24	-4	17	117	3.58

FA, fractional anisotropy.

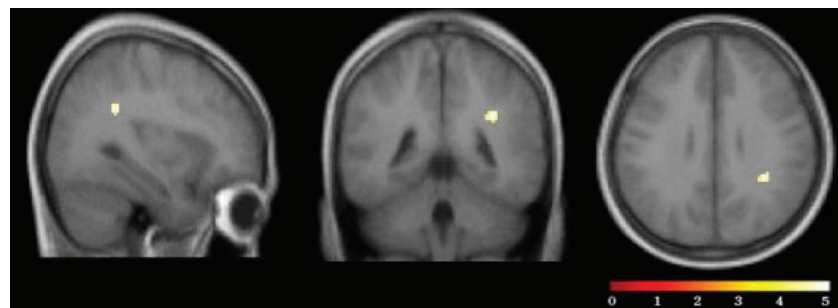
<sup>\*</sup>Foci for significant differences are listed ( $P < 0.001$ , uncorrected). Co-ordinates represent the location of the maximum pixel values in Talairach space.

<sup>†</sup>The voxels of the region were included in the same cluster of left corpus callosum extending into temporal lobe. Voxel number of '979' represented number of voxels in these two regions.

Table 2. Regions showing significant increases of FA value in patients with obsessive-compulsive disorder compared to controls at baseline.



*Fig. 1.* Voxels showing increases of fractional anisotropy in drug-naïve patients with obsessive-compulsive disorder compared to controls (threshold  $P < 0.001$ , uncorrected), mapped onto an average T1-weighted image of control and obsessive-compulsive disorder brains. The colour scale indicates the magnitude of Z-values.



*Fig. 2.* Voxels showing pretreatment to post-treatment fractional anisotropy decrease within patients with obsessive-compulsive disorder in the right posterior thalamic radiation mapped onto an average T1-weighted image (threshold  $P < 0.001$ , uncorrected).

istics such as age, duration of illness and the age of the onset.

## Discussions

We found abnormalities in the white matter integrity in drug-naïve OCD patients compared to healthy control subjects that were reversible on

treatment. Increases in the FA in drug-naïve OCD patients were observed in the white matter in the corpus callosum extending into the temporal lobe (tapetum) and in the white matter around the thalamus and corpus striatum. These structures are key regions in the pathophysiology of OCD, and these changes indicate dysfunction of the cortico-striato-thalamo-cortical circuit. Moreover,

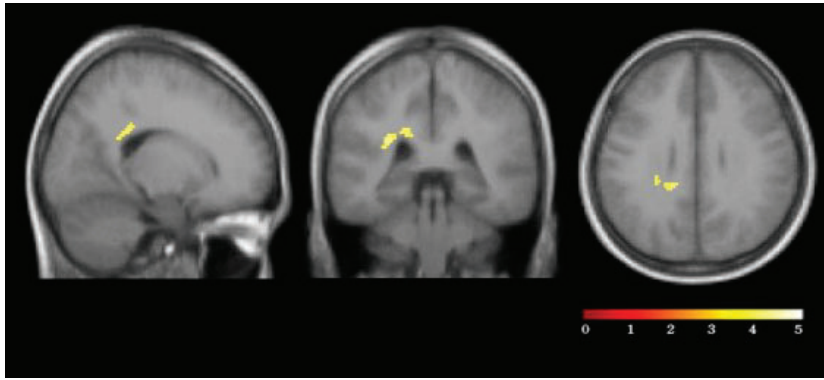


Fig. 3. Voxels showing significant increases of fractional anisotropy in patients with obsessive-compulsive disorder compared with controls after 12 weeks' treatment in the body of left corpus callosum mapped onto an average T1-weighted image (threshold  $P < 0.001$ , uncorrected).

the findings were interesting because increases in glucose metabolism or cerebral blood flow have been consistently observed in these regions, including the prefrontal area, anterior and posterior cingulate cortex, and thalamus (6–8, 35–38). Neurodevelopmentally, increases in FA due to axonal growth or myelination are observed in the normal brain until young adulthood (8–12 years), whereas there is very little change in young adults (21–27 years) (39). However, the physiological basis of the pathologic alterations in the FA remains unclear. Rosas et al. (40) suggested that the increase in FA could be a pathologic process that modifies tissue-integrity, such as neuronal remodeling or loss. From this perspective, an increase in FA might be a pathologic process caused by this neuronal change in OCD because a higher rate of the co-occurrence of OC symptoms is observed in epilepsy (41) and brain injury (42) leading to remodeling of neurons.

The increase in FA is generally proposed to be related to a higher density, more directional coherence, and greater degree of myelination of fibers; these factors could contribute to more rapid or greater information transmission functionally (43). Perhaps the higher FA in OCD patients represents a rapid or increased information transmission caused by filtering failures at the level of the thalamus. A deficiency in modulation via the cortico-striato-thalamic pathways is one of the models that explain the intrusive events, i.e. it is the hallmark of OCD. According to this scheme, excitation or disinhibition at the thalamus results from overdriving the cortico-thalamic branch, and the positive feedback loops between the cortex and thalamus might mediate circular and repetitive thoughts (10, 44). Therefore, it is interesting to note that the increases in FA in drug-naïve OCD patients were observed mostly in the regions that contain thalamic radiations, such as the posterior limb and the retrolenticular part of the internal capsule and the superolateral area of the caudate,

which are penetrated by posterior, superior, and anterior thalamic radiations respectively (45).

The other regions showing increased FA were the corpus callosum extending into the temporal lobe, especially the superior temporal region in both hemispheres. The corpus callosum is an important white matter structure that plays a critical role in inter-hemispheric communication (46, 47), and the superior temporal region also has rich reciprocal interconnections with other cortical and sub-cortical areas, such as the orbitomedial frontal areas (48), putamen, and caudate nucleus (49), where we also found increased FA. Cottraux et al. (37) reported that OCD patients who have checking rituals have greater regional cerebral blood flow (rCBF) in the superior temporal regions in the resting state, and that the processing of both obsessive and neutral stimulation increases the rCBF, based on the findings of a study using functional MRI. Choi et al. (50) also reported significant volume reductions in the superior temporal gyrus in OCD patients.

We also found that the increased FA was normalized after 12 weeks of citalopram treatment in most of the regions showing higher FA in drug-naïve OCD patients compared with healthy controls. This finding concurs with the results of previous pre- and post-treatment neuroimaging studies in which the hyperactivity in the frontal-sub-cortical circuits in untreated OCD patients was normalized in response to treatment (24, 51, 52). White matter FA changes have been reported in both the normal aging process and in disease processes with and without treatment (40, 53). Nobuhara et al. (54) reported white matter FA changes following electroconvulsive therapy in patients with depression. The changes of FA with citalopram treatment could also be resulted from the improvement of depression, not OCD. To investigate this possibility, we compared our results with previous studies. Saxena et al. (51) reported that subjects with OCD alone showed significant

metabolic decreases in the prefrontal cortex, caudate nucleus and thalamus after 8–12 weeks of treatment with paroxetine hydrochloride. On the other hand, the major depression disorder (MDD) and concurrent OCD + MDD groups showed metabolic decreases only in the prefrontal cortex and increases in the striatum. We found that decrease of white matter FA after citalopram treatment was observed in thalamic radiation only. This result supports the view that the changes of white matter FA are more associated with improvement of OCD rather than depression. However, further studies with larger subjects are necessary to determine the effect of MDD.

The OCD group showed a significant pre- to post-treatment decrease in FA only in the right posterior thalamic radiation, although most of the higher FA in drug-naïve patients compared with healthy controls was no longer seen on the subsequent comparison with healthy controls after pharmacotherapy. Although the 12 weeks of treatment with citalopram induced a normalization of FA in drug naive OCD patients compared with healthy controls, the changes of FA within OCD patients may be not significant except for one regions, i.e. the posterior thalamic radiation. Szeszko et al. (18) reported lower FA in several regions, including the anterior cingulate gyrus white matter and posterior cingulate gyrus, and no increase in FA. These differences in the results might be an effect of the treatment period or other subject characteristics such as the younger age, lower amount of co-morbid illness, and the drug-naïve state of our subjects, when we consider the significant decreases in FA after pharmacotherapy.

Moreover, in a previous study using  $^1\text{H}$ -magnetic resonance spectroscopic-imaging (MRSI) of the same subjects studied here, we found that the abnormal *N*-acetylaspartate (NAA) levels in the prefrontal cortex and frontal white matter of drug-naïve OCD patients were reversed after 12 weeks of citalopram treatment (26). Despite the vague correlations of FA with NAA (55) and the limitation that the regions of interest in the  $^1\text{H}$ -MRSI study did not include the thalamus and basal ganglia, our results may be significant when we consider that both studies provide evidence of the reversibility of the neuronal integrity in OCD patients with pharmacotherapy.

Our study has several limitations. Firstly, the sample size in each group was small. This may explain the lack of differences in the white matter integrity in other regions, including the orbitofrontal lobe and striatal regions, and the absence of significant correlations between OC symptoms and FA values. Secondly, the treatment period was

relatively short. Because the white matter volume or integrity changed according to treatment or the symptomatic state (56–58), the findings after 12 weeks of treatment could change further with additional treatment. Additional studies should examine the white matter integrity in OCD patients for a larger sample size and a longer period of treatment. Thirdly, the OCD patients were drug-naïve at baseline and had taken only citalopram. Therefore, it is difficult to speculate whether our results would be applicable to patients who are taking other medications or undergoing cognitive behavior therapy. Finally, the methodological limitations must be considered. There are some debates about Voxel-Based Morphometry methods, such as the accuracy of normalization and the detection ability of the precise regions showing differences. However, we inspected the all images to verify the normalization.

In conclusion, our findings suggest that white matter alterations are associated with the pathophysiology of OCD and the abnormalities may be partly reversible with pharmacotherapy.

### Acknowledgement

This research was supported by a grant (M103KV010012-06K2201-01210) from Brain Research Center of the 21st Century Frontier Research Program funded by the Ministry of Science and Technology, the Republic of Korea.

### References

1. KANG DH, KIM JJ, CHOI JS et al. Volumetric investigation of the frontal-subcortical circuitry in patients with obsessive-compulsive disorder. *J Neuropsychiatry Clin Neurosci* 2004;**16**:342–349.
2. KIM JJ, LEE MC, KIM J et al. Grey matter abnormalities in obsessive-compulsive disorder: statistical parametric mapping of segmented magnetic resonance images. *Br J Psychiatry* 2001;**179**:330–334.
3. SAXENA S, BRODY AL, SCHWARTZ JM, BAXTER LR. Neuroimaging and frontal-subcortical circuitry in obsessive-compulsive disorder. *Br J Psychiatry Suppl* 1998;**173**:26–37.
4. SZESZKO PR, ROBINSON D, ALVIR JM et al. Orbital frontal and amygdala volume reductions in obsessive-compulsive disorder. *Arch Gen Psychiatry* 1999;**56**:913–919.
5. BAXTER LR Jr, SCHWARTZ JM, MAZZIOTTA JC et al. Cerebral glucose metabolic rates in nondepressed patients with obsessive-compulsive disorder. *Am J Psychiatry* 1988;**145**:1560–1563.
6. PERANI D, COLOMBO C, BRESSI S et al. [ $^{18}\text{F}$ ]Fdg Pet study in obsessive-compulsive disorder. A clinical/metabolic correlation study after treatment. *Br J Psychiatry* 1995;**166**:244–250.
7. SWEDO SE, SCHAPIRO MB, GRADY CL et al. Cerebral glucose metabolism in childhood-onset obsessive-compulsive disorder. *Arch Gen Psychiatry* 1989;**46**:518–523.
8. MCGUIRE PK, BENCH CJ, FRITH CD, MARKS IM, FRACKOWIAK RS, DOLAN RJ. Functional anatomy of obsessive-compulsive phenomena. *Br J Psychiatry* 1994;**164**:459–468.

9. NAKAO T, NAKAGAWA A, YOSHIURA T et al. Brain activation of patients with obsessive-compulsive disorder during neuropsychological and symptom provocation tasks before and after symptom improvement: a functional magnetic resonance imaging study. *Biol Psychiatry* 2005;**57**: 901–910.
10. RAUCH SL, JENIKE MA. Neurobiological models of obsessive-compulsive disorder. *Psychosomatics* 1993;**34**:20–32.
11. PUJOL J, SORIANO-MAS C, ALONSO P et al. Mapping structural brain alterations in obsessive-compulsive disorder. *Arch Gen Psychiatry* 2004;**61**:720–730.
12. SZESZKO PR, MACMILLAN S, MCMENIMAN M et al. Brain structural abnormalities in psychotropic drug-naïve pediatric patients with obsessive-compulsive disorder. *Am J Psychiatry* 2004;**161**:1049–1056.
13. RIFFKIN J, YUCEL M, MARUFF P et al. A manual and automated MRI study of anterior cingulate and orbito-frontal cortices, and caudate nucleus in obsessive-compulsive disorder: comparison with healthy controls and patients with schizophrenia. *Psychiatry Res* 2005;**138**:99–113.
14. JENIKE MA, BREITER HC, BAER L et al. Cerebral structural abnormalities in obsessive-compulsive disorder. A quantitative morphometric magnetic resonance imaging study. *Arch Gen Psychiatry* 1996;**53**:625–632.
15. ROSENBERG DR, KESHAVAN MS, DICK EL, BAGWELL WW, MACMASTER FP, BIRMAHER B. Corpus callosal morphology in treatment-naïve pediatric obsessive compulsive disorder. *Prog Neuropsychopharmacol Biol Psychiatry* 1997;**21**:1269–1283.
16. MAC MASTER FP, KESHAVAN MS, DICK EL, ROSENBERG DR. Corpus callosal signal intensity in treatment-naïve pediatric obsessive compulsive disorders. *Prog Neuropsychopharmacol Biol Psychiatry* 1999;**23**:601–612.
17. KITAMURA HST, KIMURA T, OHKUBO M, NAKADA T, SOMEYA T. Parietal white matter abnormalities in obsessive-compulsive disorder: a magnetic resonance spectroscopy study at 3-Tesla. *Acta Psychiatr Scand* 2006;**114**:101–108.
18. SZESZKO PR, ARDEKANI BA, ASHTARI M et al. White matter abnormalities in obsessive-compulsive disorder: a diffusion tensor imaging study. *Arch Gen Psychiatry* 2005;**62**:782–790.
19. GILBERT AR, MOORE GJ, KESHAVAN MS et al. Decrease in thalamic volumes of pediatric patients with obsessive-compulsive disorder who are taking paroxetine. *Arch Gen Psychiatry* 2000;**57**:449–456.
20. BAXTER LR Jr. Neuroimaging studies of obsessive compulsive disorder. *Psychiatr Clin North Am* 1992;**15**:871–884.
21. HANSEN ES, PRICHEP LS, BOLWIG TG, JOHN ER. Quantitative electroencephalography in OCD patients treated with paroxetine. *Clin Electroencephalogr* 2003;**34**:70–74.
22. SAXENA S, BRODY AL, MAIDMENT KM et al. Localized orbitofrontal and subcortical metabolic changes and predictors of response to paroxetine treatment in obsessive-compulsive disorder. *Neuropsychopharmacology* 1999;**21**:683–693.
23. SAXENA S, RAUCH SL. Functional neuroimaging and the neuroanatomy of obsessive-compulsive disorder. *Psychiatr Clin North Am* 2000;**23**:563–586.
24. SWEDO SE, PIETRINI P, LEONARD HL et al. Cerebral glucose metabolism in childhood-onset obsessive-compulsive disorder. Revisualization during pharmacotherapy. *Arch Gen Psychiatry* 1992;**49**:690–694.
25. KANG DH, KWON JS, KIM JJ et al. Brain glucose metabolic changes associated with neuropsychological improvements after 4 months of treatment in patients with obsessive-compulsive disorder. *Acta Psychiatr Scand* 2003;**107**:291–297.
26. JANG JH, KWON JS, JANG DP et al. A proton MRSI study of brain *N*-acetylaspartate level after 12 weeks of citalopram treatment in drug-naïve patients with obsessive-compulsive disorder. *Am J Psychiatry* 2006;**163**:1–7.
27. FIRST MB, SPITZER RL. Structured clinical interview for DSM-IV Axis I disorder. New York: New York State Psychiatric Institute, 1996.
28. YUM TH PY, OH KJ, LEE YH. The manual of Korean-Wechsler adult intelligence scale. Seoul: Korean Guidance Press, 1992.
29. GOODMAN WK, PRICE LH, RASMUSSEN SA et al. The Yale-Brown Obsessive Compulsive Scale. I. Development, use, and reliability. *Arch Gen Psychiatry* 1989;**46**:1006–1011.
30. HAMILTON M. A rating scale for depression. *J Neurol Neurosurg Psychiatry* 1960;**23**:56–62.
31. BECK AT, WARD CH, MENDELSON M, MOCK J, ERBAUGH J. An inventory for measuring depression. *Arch Gen Psychiatry* 1961;**4**:561–571.
32. BECK AT, STEER R. Manual for the beck anxiety inventory. San Antonio: Psychological Corporation, 1990.
33. BASSER PJ, PAJEVIC S. Statistical artifacts in diffusion tensor MRI (DT-MRI) caused by background noise. *Magn Reson Med* 2000;**44**:41–50.
34. GOOD CD, JOHNSRUDE IS, ASHBURNER J, HENSON RN, FRISTON KJ, FRACKOWIAK RS. A voxel-based morphometric study of ageing in 465 normal adult human brains. *Neuroimage* 2001;**14**:21–36.
35. BAXTER LR Jr, PHELPS ME, MAZZIOTTA JC, GUZE BH, SCHWARTZ JM, SELIN CE. Local cerebral glucose metabolic rates in obsessive-compulsive disorder. A comparison with rates in unipolar depression and in normal controls. *Arch Gen Psychiatry* 1987;**44**:211–218.
36. BUSATTO GF, ZAMIGNANI DR, BUCHPIGUEL CA et al. A voxel-based investigation of regional cerebral blood flow abnormalities in obsessive-compulsive disorder using single photon emission computed tomography (SPECT). *Psychiatry Res* 2000;**99**:15–27.
37. COTTRAUX J, GERARD D, CINOTTI L et al. A controlled positron emission tomography study of obsessive and neutral auditory stimulation in obsessive-compulsive disorder with checking rituals. *Psychiatry Res* 1996;**60**:101–112.
38. SAWLE GV, HYMAS NF, LEES AJ, FRACKOWIAK RS. Obsessional slowness. Functional studies with positron emission tomography. *Brain* 1991;**114**(Pt 5):2191–2202.
39. SNOOK L, PAULSON LA, ROY D, PHILLIPS L, BEAULIEU C. Diffusion tensor imaging of neurodevelopment in children and young adults. *Neuroimage* 2005;**26**:1164–1173.
40. ROSAS HD, TUCH DS, HEVELONE ND et al. Diffusion tensor imaging in presymptomatic and early Huntington's disease: selective white matter pathology and its relationship to clinical measures. *Mov Disord* 2006;**21**:1317–1325.
41. ISAACS KL, PHILBECK JW, BARR WB, DEVINSKY O, ALPER K. Obsessive-compulsive symptoms in patients with temporal lobe epilepsy. *Epilepsy Behav* 2004;**5**:569–574.
42. COETZER BR. Obsessive-compulsive disorder following brain injury: a review. *Int J Psychiatry Med* 2004;**34**:363–377.
43. SHIMONY JS, MCKINSTRY RC, AKBUDAK E et al. Quantitative diffusion-tensor anisotropy brain MR imaging: normative human data and anatomic analysis. *Radiology* 1999;**212**:770–784.
44. MODELL JG, MOUNTZ JM, CURTIS GC, GREDEN JF. Neurophysiologic dysfunction in basal ganglia/limbic striatal and thalamocortical circuits as a pathogenetic mechanism of obsessive-compulsive disorder. *J Neuropsychiatry Clin Neurosci* 1989;**1**:27–36.



45. MORI S, WAKANA S, NAGAE-POETSCHER LM, ZIJL PCMV. MRI atlas of human white matter. Amsterdam: Elsevier B.V., 2005.
46. MARZI CA, BISIACCHI P, NICOLETTI R. Is interhemispheric transfer of visuomotor information asymmetric? Evidence from a meta-analysis. *Neuropsychologia* 1991;**29**:1163–1177.
47. SANCHEZ MM, HEARN EF, DO D, RILLING JK, HERNDON JG. Differential rearing affects corpus callosum size and cognitive function of rhesus monkeys. *Brain Res* 1998;**812**:38–49.
48. PANDYA DN. Anatomy of the auditory cortex. *Rev Neurol (Paris)* 1995;**151**:486–494.
49. YETERIAN EH, PANDYA DN. Corticostriatal connections of the superior temporal region in rhesus monkeys. *J Comp Neurol* 1998;**399**:384–402.
50. CHOI JS, KIM HS, YOO SY et al. Morphometric alterations of anterior superior temporal cortex in obsessive–compulsive disorder. *Depress Anxiety* 2006;**23**:290–296.
51. BENKELFAT C, NORDAHL TE, SEMPLE WE, KING AC, MURPHY DL, COHEN RM. Local cerebral glucose metabolic rates in obsessive–compulsive disorder. Patients treated with clomipramine. *Arch Gen Psychiatry* 1990;**47**:840–848.
52. SAXENA S, BRODY AL, HO ML et al. Differential cerebral metabolic changes with paroxetine treatment of obsessive–compulsive disorder vs major depression. *Arch Gen Psychiatry* 2002;**59**:250–261.
53. CHARLTON RA, BARRICK TR, MCINTYRE DJ et al. White matter damage on diffusion tensor imaging correlates with age-related cognitive decline. *Neurology* 2006;**66**:217–222.
54. NOBUHARA K, OKUGAWA G, MINAMI T et al. Effects of electroconvulsive therapy on frontal white matter in late-life depression: a diffusion tensor imaging study. *Neuropsychobiology* 2004;**50**:48–53.
55. STEEL RM, BASTIN ME, MCCONNELL S et al. Diffusion tensor imaging (DTI) and proton magnetic resonance spectroscopy (1H MRS) in schizophrenic subjects and normal controls. *Psychiatry Res* 2001;**106**:161–170.
56. CHRISTENSEN J, HOLCOMB J, GARVER DL. State-related changes in cerebral white matter may underlie psychosis exacerbation. *Psychiatry Res* 2004;**130**:71–78.
57. MALBERG JE, EISCH AJ, NESTLER EJ, DUMAN RS. Chronic antidepressant treatment increases neurogenesis in adult rat hippocampus. *J Neurosci* 2000;**20**:9104–9110.
58. MOLINA V, REIG S, SANZ J et al. Increase in gray matter and decrease in white matter volumes in the cortex during treatment with atypical neuroleptics in schizophrenia. *Schizophr Res* 2005;**80**:61–71.