

Published in final edited form as:

*J Neuroimaging*. 2014 September ; 24(5): 504–508. doi:10.1111/jon.12050.

## White matter changes in patients with Friedreich ataxia after treatment with erythropoietin

Karl Egger, M.D.<sup>1,2,\*</sup>, Christian Clemm von Hohenberg<sup>1,\*</sup>, Michael F Schocke, M.D.<sup>3</sup>, Charles RG Guttman, M.D.<sup>4,9</sup>, Demian Wassermann, Ph.D.<sup>1</sup>, Marlene C Wigand<sup>1</sup>, Wolfgang Nachbauer, M.D.<sup>5</sup>, Christian Kremser, M.D.<sup>3</sup>, Brigitte Sturm, Ph.D.<sup>6</sup>, Barbara Scheiber-Mojdehkar, Ph.D.<sup>6</sup>, Marek Kubicki, M.D., Ph.D.<sup>1,8,9</sup>, Martha E Shenton, Ph.D.<sup>1,7,8,9</sup>, and Sylvia Boesch, M.D.<sup>5</sup>

<sup>1</sup>Psychiatry Neuroimaging Laboratory, Brigham and Women's Hospital and Harvard Medical School, Boston, MA 02215, USA

<sup>2</sup>Department of Neuroradiology, University Hospital Freiburg, 79106, Germany

<sup>3</sup>Department of Radiology, Innsbruck Medical University, 6020, Austria

<sup>4</sup>Center for Neurological Imaging, Brigham and Women's Hospital, Harvard Medical School, Boston, MA 02115, USA

<sup>5</sup>Department of Neurology, Innsbruck Medical University, 6020, Austria

<sup>6</sup>Department of Medical Chemistry, Medical University of Vienna, 1090, Austria

<sup>7</sup>Department of Psychiatry, Veterans Affairs Boston Healthcare System, Brockton Division, Brockton, MA 02130, USA

<sup>8</sup>Department of Psychiatry, Brigham and Women's Hospital and Harvard Medical School, Boston, MA 02115, USA

<sup>9</sup>Department of Radiology, Brigham and Women's Hospital and Harvard Medical School, Boston, MA 02115, USA

### Abstract

**Background and Purpose**—Erythropoietin (EPO) has received growing attention because of its neuro-regenerative properties. Preclinical and clinical evidence supports its therapeutic potential in brain conditions like stroke, multiple sclerosis and schizophrenia. Also in Friedreich ataxia, clinical improvement after EPO therapy was shown. The aim of the present study was to assess possible therapy-associated brain white-matter changes in these patients.

---

Address correspondence to: Christian Clemm von Hohenberg, Psychiatry Neuroimaging Laboratory, Brigham and Women's Hospital and Harvard Medical School, 1249 Boylston St., Boston, MA 02215, Tel. +1 617 525-6105, Fax +1 617 525-6150, clemm@bwh.harvard.edu.

\*These authors contributed equally to this work.

#### Potential conflicts of interest

The following patents (related to the use of rhuEPO for FRDA) have been applied for by the Medical University of Vienna (Dr. Sturm, Dr. Scheiber-Mojdehkar): A 1869/2004 and PCT/EP2005/011510.

**Methods**—Nine patients with Friedreich ataxia underwent Diffusion Tensor Imaging (DTI) before and after EPO treatment. Tract-based spatial statistics (TBSS) was used for longitudinal comparison.

**Results**—We detected widespread longitudinal increase in fractional anisotropy (FA) and axial diffusivity (D<sub>||</sub>) in cerebral hemispheres bilaterally ( $p < 0.05$ , corrected), while no changes were observed within the cerebellum, medulla oblongata and pons.

**Conclusions**—To the best of our knowledge, this is the first DTI study to investigate the effects of erythropoietin in a neurodegenerative disease. Anatomically, the diffusivity changes appear disease-unspecific, and their biological underpinnings deserve further study.

## INTRODUCTION

EPO has received considerable attention because of its neuroprotective properties,<sup>1, 2</sup> and there is evidence from animal studies pointing to a *neuroregenerative* potential.<sup>3–6</sup>

Friedreich ataxia (FRDA) is the most common inherited ataxia in those of Western European descent, and is caused by an intronic GAA triplet repeat expansion in the Frataxin gene (FXN; OMIM606829) on chromosome 9q13.<sup>7, 8</sup> Larger GAA expansions are associated with earlier age of onset and greater clinical severity.<sup>9</sup> Frataxin is a small mitochondrial protein involved in iron metabolism, and its deficiency leads to mitochondrial dysfunction and oxidative stress.<sup>8</sup> Expression varies between tissues. In FRDA, the primary sensory neurons are specifically affected, which results in atrophy of the spinal cord's dorsal column and spinocerebellar tracts, which carry the proprioceptive information for the cerebellum.<sup>10</sup>

Magnetic resonance imaging (MRI) in FRDA has revealed volume loss in the spinal cord, brainstem, cerebellum and optic chiasm.<sup>11–14</sup> DTI has shown white matter (WM) changes including decreased FA and/or higher Mean Diffusivity (MD). These changes were present in the brainstem and cerebellum, but also in supratentorial regions like the optic radiation.<sup>15–17</sup> Diffusivity indices also correlated with number of triplet repeats, duration of illness and scores of clinical severity.<sup>16, 17</sup>

There is evidence that EPO could be an effective treatment in FRDA: Sturm et al. found that recombinant human EPO (rhuEPO) increases Frataxin levels in isolated lymphocytes from FRDA patients *in vitro*.<sup>18</sup> Subsequently, significant increase in Frataxin levels and clinical improvement in FRDA patients treated with rhuEPO were shown.<sup>19, 20</sup>

Given that DTI indices are a widely used marker of brain WM integrity, and there is evidence for their validity in FRDA,<sup>16, 17</sup> we used DTI in the present study to test for possible diffusivity changes in FRDA patients after treatment with rhuEPO.

## METHODS

Twelve patients with an established diagnosis of FRDA were included in the original clinical study.<sup>19</sup> Demographic and clinical variables are given in Table 1. Exclusion criteria (described in detail elsewhere<sup>19, 20</sup>) were all conditions incompatible with EPO treatment,

particularly hemoglobin levels above 17 mg/dl and a history of thrombosis. All diagnostic and therapeutic interventions were performed according to the Declaration of Helsinki and the recommendations of the local Ethics Committee and Security Board after obtaining written informed consent from the patients.

### Study design

In an open-label, Phase II, proof-of-concept study, FRDA patients received 5000IU rhuEPO subcutaneously three times a week for 2 months. The primary outcome measure was the serum concentration of Frataxin.<sup>19</sup> Thereafter, 10 out of these 12 patients entered a six-months follow-up study and received 2000 IU rhuEPO three times weekly.<sup>20</sup> The rhuEPO dose reduction was due to reported side effects (transient mental agitation, as well as raised hemoglobin- and hematocrit-levels). Two patients (see Table 1) chose not to enter the follow-up study and consequently received rhuEPO only during the initial 2 months. The primary outcome measures for this follow-up study were two clinical rating scores, the Friedreich Ataxia Rating Scale (FARS)<sup>21</sup> and the Scale for the Assessment and Rating of Ataxia (SARA).<sup>22</sup>

Safety was assessed by bi-weekly measurement of hematocrit and hemoglobin, as well as erythrocyte, reticulocyte and thrombocyte counts.

### MRI acquisition

MRI was performed before therapy (baseline) and after 10–12 months (follow-up). All participants were scanned on the same 1.5 Tesla MRI scanner (Magnetom Vision; Siemens Medical Solutions, Erlangen, Germany) using a standard circular-polarized head coil. Brain DTI was acquired in axial orientation using a diffusion-weighted spin-echo single-shot echo-planar imaging (EPI) sequence with diffusion encoding in 6 directions (TE=94ms, TR=6000ms, FOV=256, matrix size of 128×128, 35 contiguous axial slices with 3 mm thickness, b values 0 and 1000s/mm<sup>2</sup>). MRI scans were evaluated by an experienced radiologist (K.E.), to rule out structural abnormalities or artifacts. Two patients had to be excluded because of claustrophobia and another patient due to movement artifacts on MRI.

### TBSS

To test for longitudinal diffusivity changes, we performed voxelwise statistical analysis using TBSS, part of the Oxford Center for Functional MRI of the Brain (FMRIB) Software Library (FSL).<sup>23</sup>

First, the diffusion data were corrected for effects of motion and eddy currents through affine registration to the b0 volume. This was done using FMRIB's Linear Image Registration Tool (FLIRT), also part of FSL. Diffusion gradients were rotated accordingly. After noise-filtering, the images were skull-stripped with the Brain Extraction Tool (BET, also part of FSL). Next, diffusion tensors were estimated using a weighted least squares method in Slicer (slicer.org), and FA maps were computed for all subjects.

Within the TBSS pipeline, all FA images were non-linearly registered to a single subject. This subject was chosen automatically such that the amount of deformation required for all the other subjects was minimal.

All FA volumes were then averaged and the resulting mean FA image underwent a thinning process leading to the extraction of the skeleton, representing the central course of WM tracts.<sup>23</sup> In order to include only voxels clearly located in WM, this skeleton was thresholded ( $FA > 0.3$ ). This threshold is slightly higher than the default threshold of 0.2, but is also recommended in the original TBSS publication.<sup>23</sup> We chose to use the higher threshold because it yielded a skeleton more clearly restricted to WM, which should help avoid partial volume effects.

Each subject's registered FA data was then projected onto this skeleton. On these data, we applied a permutation-based voxelwise paired t-test (5000 permutations) in *randomise*, also part of FSL.<sup>24</sup> The significance threshold was set to  $p < 0.05$ , family-wise error (FWE) corrected for multiple comparisons.<sup>24</sup>

The MD,  $D_{||}$ ,  $D_{\perp}$  (i.e. radial diffusivity) and  $b_0$  images were analyzed using the same methodology: we applied the nonlinear warps obtained from the FA registrations and the skeleton projection and performed the same permutation-based test.

In a secondary analysis, we computed Spearman's correlation coefficient between longitudinal change in clinical scores (FARS and SARA) and longitudinal change in DTI parameters, averaged over all significant voxels from the main analysis. This nonparametric correlation coefficient was used due to the ordinal nature of the clinical scores and the small sample size.

## RESULTS

Comparing scans before and after treatment with rhuEPO, we observed widespread and bilateral FA increases ( $p < 0.05$ , FWE corrected), including the frontal, parietal, temporal and occipital lobes as well as the diencephalon and mesencephalon, but excluding the pons, cerebellum and medulla oblongata. Increases in  $D_{||}$  were similarly distributed but less pronounced, largely excluding the temporal and occipital lobes (see Figure 1). These changes in FA and  $D_{||}$  were attended by unchanged MD,  $D_{\perp}$  and  $b_0$  values throughout the entire brain.

In the correlational analyses, we did not detect correlations between longitudinal DTI changes and changes in SARA or FARS.

## DISCUSSION

To the best of our knowledge, this is the first study showing extensive FA increase in patients with a neurodegenerative disease, upon administration of a drug aimed to be neuroregenerative.

FA, MD,  $D_{||}$  and  $D_{\perp}$  are widely used measures for assessing WM in neurodegenerative processes. In most cases, these studies have reported decreased FA (often attended by increased MD and RD), for example in FRDA,<sup>15</sup> Huntington's disease<sup>25</sup> and Alzheimer's disease.<sup>26</sup>

In the case of  $D_{||}$ , both decreases and increases have been reported in neurodegeneration. In some of the above-cited studies where FA was reduced, both  $D_{||}$  and  $D_{\perp}$  were found increased, but with stronger increase of the latter.<sup>15, 25–27</sup> In contrast,  $D_{||}$  decline over time was observed in Huntington's.<sup>28</sup>

Even in the case of FA, single studies have reported increases associated with pathological conditions or reduced functioning, which was primarily interpreted as reflecting reduced fiber branching or crossing.<sup>29</sup>

Overall, while we cannot exclude this possibility, it appears unlikely that the longitudinal FA and  $D_{||}$  increases in our study reflect ongoing neurodegeneration, since these increases included, for example, the body of the corpus callosum, a highly ordered tract, where no fiber crossing is expected.

Regarding normal aging, a recent study focusing on the corpus callosum revealed increasing FA and decreasing MD during childhood and early adolescence, with FA values peaking from 21 to 29 years.<sup>30</sup> As five of the participants in our study were within this particular age range, we considered the possibility that the increase in FA could be merely due to ongoing development. This, however, appears unlikely, since FA increase in early adulthood is combined with prolonged decrease of  $D_{||}$ ,<sup>30</sup> whereas  $D_{||}$  in our patients increased significantly.

In combined histopathological-imaging studies in animals, axonal and myelin injury were found to correlate with elevated  $D_{||}$  and reduced  $D_{\perp}$ , respectively,<sup>31</sup> and the reverse held true for regeneration.<sup>32</sup> However, there are recent data indicating that the DTI-histology relationship may be more complex. For example, two recent studies in humans found axonal density to be correlated with FA and  $D_{\perp}$ , but not significantly with  $D_{||}$ .<sup>33, 34</sup> In the light of these reports, one can only speculate about the histological basis of the changes seen in our study, while axonal changes appear as a possible candidate.

Since iron metabolism is affected in FRDA,<sup>8</sup> we sought to rule out the possibility that ongoing iron deposition may have affected the diffusion-weighted data due to signal changes in the  $b_0$  images. However, comparison of these  $b_0$  images at baseline and follow-up did not reveal significant or trend-level alterations. Hence, iron-deposition is unlikely to explain our findings.

EPO and its derivatives have come into focus as promising candidates for the treatment of various brain conditions. There has been a wealth of preclinical studies and also some encouraging clinical trials, particularly in ischemic stroke, multiple sclerosis and schizophrenia (reviewed in <sup>35</sup>).

EPO and EPO receptors (EPO-R) are expressed in the brain during development and adulthood.<sup>36</sup> As mentioned, several animal studies have demonstrated beneficial effects of EPO administration after traumatic brain injury or ischemia.<sup>3-6</sup>

In the context of our DTI findings, it is particularly noteworthy that EPO increased oligodendrogenesis and reduced WM damage after ischemia in rats.<sup>3</sup>

Moreover, EPO administered after traumatic brain injury leads to higher glucose levels and lower lactate levels.<sup>37</sup> In FRDA patients, PET studies have shown that glucose metabolism is initially increased in various brain regions, but decreases again with clinical severity.<sup>38</sup> Therefore, the impact of EPO as measured in our study could also be related to an improvement of energy supply.

Regardless of the exact biological mechanism, we speculate that the changes seen are reflective of disease-unspecific EPO effects, which is supported by two observations: Firstly, significant effects were located only in regions that are not primarily affected in FRDA, i.e. not in the medulla, pons and cerebellum. One could speculate that these regions have less regenerative potential and are therefore less susceptible to the unspecific “positive” effects of EPO.

Secondly, we could not detect significant correlations between changes in clinical and diffusivity parameters, which is likely also related to the small sample size and resulting limited power in our study.

Unfortunately, there are no longitudinal studies assessing the development of DTI parameters in patients with FRDA specifically. Also, since our study lacks a placebo group, we consequently were not able to assess how diffusion parameters would have changed without therapy.

Additional limitations of this study include using a DTI acquisition protocol with only six directions of diffusion gradients, and the relatively small number of study participants.

## CONCLUSION

In this exploratory study, TBSS revealed extensive WM changes in patients with FRDA following therapy with rhuEPO. This finding supports the exciting potential of rhuEPO for neuro-protection and –regeneration in humans. Additionally, our findings, in combination with previously published results,<sup>16, 17</sup> support the potential of diffusivity parameters to act as valuable biomarkers in the assessment of disease progression and therapeutic response.

## Acknowledgments

### FUNDING SOURCES:

**Dr. Egger** received funding from a “Habilitation” grant of the Medical University Innsbruck.

**Mr. Clemm von Hohenberg** received funding from the German National Academic Foundation.

**Dr. Schocke** is an employee of the Innsbruck Medical University and reports no other financial disclosures.

**Dr. Guttman** is an employee of the Brigham and Women's Hospital and consulted for Tibotec Therapeutics/Johnson&Johnson and has received research grant funding from Teva Neurosciences. He holds stocks in Novartis, Roche, GSK, and Alnylam.

**Ms. Wigand** received funding from the German National Academic Foundation. Her work for this paper was part of her doctorate thesis at Ludwig-Maximilians-University Munich, Germany.

**Dr. Wassermann** is an employee of the Psychiatry Neuroimaging Laboratory, Brigham and Women's Hospital, and reports no other financial disclosures.

**Dr. Nachbauer** is an employee of the Medical University Innsbruck and reports no other financial disclosures.

**Dr. Kremser** is an employee of the Medical University Innsbruck and reports no other financial disclosures.

**Dr. Sturm** is an employee of the Medical University of Vienna and is inventor of a patent held by the Medical University of Vienna related to EPO and Friedreich's Ataxia.

**Dr. Scheiber-Mojdehkar** is an employee of the Medical University of Vienna and is inventor of a patent held by the Medical University of Vienna related to EPO and Friedreich's Ataxia, and received a research grant supporting this study from the Rofar foundation (Roche Foundation for Anaemia Research, Switzerland).

**Dr. Kubicki** received funding from the following grants: Veterans Affairs (VA) Schizophrenia Center Grant; National Institutes of Health (NIH) R01 MH074794; NIH/National Institutes of Mental Health (NIMH) 1P50MH080272-01, and VA Merit Award.

**Dr. Shenton** received funding from the following grants: NIH/NIMH R01 MH 40799, VA Merit Review, VA Center Grant, NIH/NIMH, W81XWH-07-CC-CS-DoD, HCDC PTSD/TBI Clinical Consortium, NIH/NIMH 1 R01MH082918-01A2, NIH/NIA 1R01AG034554, NIH/NIA R01 AG 034155, CIMIT.

**Dr. Boesch** is an employee of the Medical University Innsbruck and served on the scientific advisory board for Novartis, Cephalon, GSK, and Lundbeck.

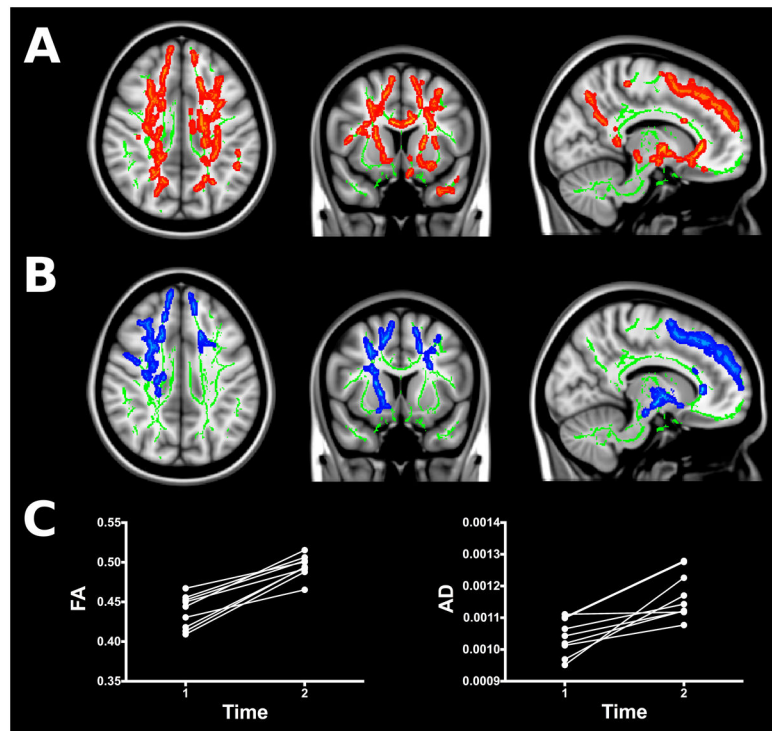
## References

1. Juul S. Erythropoietin in the central nervous system, and its use to prevent hypoxic-ischemic brain damage. *Acta Paediatr Suppl.* 2002; 91(438):36–42. [PubMed: 12477263]
2. Siren AL, Ehrenreich H. Erythropoietin--a novel concept for neuroprotection. *Eur Arch Psychiatry Clin Neurosci.* Aug; 2001 251(4):179–184. [PubMed: 11697582]
3. Iwai M, Stetler RA, Xing J, et al. Enhanced oligodendrogenesis and recovery of neurological function by erythropoietin after neonatal hypoxic/ischemic brain injury. *Stroke.* May; 2010 41(5): 1032–1037. [PubMed: 20360553]
4. Wang L, Zhang Z, Wang Y, Zhang R, Chopp M. Treatment of stroke with erythropoietin enhances neurogenesis and angiogenesis and improves neurological function in rats. *Stroke.* Jul; 2004 35(7): 1732–1737. [PubMed: 15178821]
5. Xiong Y, Lu D, Qu C, et al. Effects of erythropoietin on reducing brain damage and improving functional outcome after traumatic brain injury in mice. *J Neurosurg.* Sep; 2008 109(3):510–521. [PubMed: 18759585]
6. Xiong Y, Mahmood A, Meng Y, et al. Delayed administration of erythropoietin reducing hippocampal cell loss, enhancing angiogenesis and neurogenesis, and improving functional outcome following traumatic brain injury in rats: comparison of treatment with single and triple dose. *J Neurosurg.* Sep; 2010 113(3):598–608. [PubMed: 19817538]
7. Campuzano V, Montermini L, Molto MD, et al. Friedreich's ataxia: autosomal recessive disease caused by an intronic GAA triplet repeat expansion. *Science.* Mar 8; 1996 271(5254):1423–1427. [PubMed: 8596916]
8. Pandolfo M. Friedreich ataxia. *Arch Neurol.* Oct; 2008 65(10):1296–1303. [PubMed: 18852343]
9. Montermini L, Richter A, Morgan K, et al. Phenotypic variability in Friedreich ataxia: role of the associated GAA triplet repeat expansion. *Ann Neurol.* May; 1997 41(5):675–682. [PubMed: 9153531]

10. Koeppe AH. Friedreich's ataxia: pathology, pathogenesis, and molecular genetics. *J Neurol Sci.* Apr 15; 2011 303(1–2):1–12. [PubMed: 21315377]
11. Wullner U, Klockgether T, Petersen D, Naegele T, Dichgans J. Magnetic resonance imaging in hereditary and idiopathic ataxia. *Neurology.* Feb; 1993 43(2):318–325. [PubMed: 8437696]
12. Della Nave R, Ginestroni A, Giannelli M, et al. Brain structural damage in Friedreich's ataxia. *J Neurol Neurosurg Psychiatry.* Jan; 2008 79(1):82–85. [PubMed: 17634216]
13. Akhlaghi H, Corben L, Georgiou-Karistianis N, et al. Superior cerebellar peduncle atrophy in Friedreich's ataxia correlates with disease symptoms. *Cerebellum.* Mar; 2011 10(1):81–87. [PubMed: 21107777]
14. Pagani E, Ginestroni A, Della Nave R, et al. Assessment of brain white matter fiber bundle atrophy in patients with Friedreich ataxia. *Radiology.* Jun; 2010 255(3):882–889. [PubMed: 20501725]
15. Della Nave R, Ginestroni A, Diciotti S, Salvatore E, Soricelli A, Mascalchi M. Axial diffusivity is increased in the degenerating superior cerebellar peduncles of Friedreich's ataxia. *Neuroradiology.* Dec 3.2010
16. Della Nave R, Ginestroni A, Tessa C, et al. Brain white matter tracts degeneration in Friedreich ataxia. An in vivo MRI study using tract-based spatial statistics and voxel-based morphometry. *Neuroimage.* Mar 1; 2008 40(1):19–25. [PubMed: 18226551]
17. Rizzo G, Tonon C, Valentino ML, et al. Brain diffusion-weighted imaging in Friedreich's ataxia. *Mov Disord.* Mar 2.2011
18. Sturm B, Stupphann D, Kaun C, et al. Recombinant human erythropoietin: effects on frataxin expression in vitro. *Eur J Clin Invest.* Nov; 2005 35(11):711–717. [PubMed: 16269021]
19. Boesch S, Sturm B, Hering S, Goldenberg H, Poewe W, Scheiber-Mojdehkar B. Friedreich's ataxia: clinical pilot trial with recombinant human erythropoietin. *Ann Neurol.* Nov; 2007 62(5): 521–524. [PubMed: 17702040]
20. Boesch S, Sturm B, Hering S, et al. Neurological effects of recombinant human erythropoietin in Friedreich's ataxia: a clinical pilot trial. *Mov Disord.* Oct 15; 2008 23(13):1940–1944. [PubMed: 18759345]
21. Lynch DR, Farmer JM, Tsou AY, et al. Measuring Friedreich ataxia: complementary features of examination and performance measures. *Neurology.* Jun 13; 2006 66(11):1711–1716. [PubMed: 16769945]
22. Schmitz-Hubsch T, du Montcel ST, Baliko L, et al. Scale for the assessment and rating of ataxia: development of a new clinical scale. *Neurology.* Jun 13; 2006 66(11):1717–1720. [PubMed: 16769946]
23. Smith SM, Jenkinson M, Johansen-Berg H, et al. Tract-based spatial statistics: voxelwise analysis of multi-subject diffusion data. *Neuroimage.* Jul 15; 2006 31(4):1487–1505. [PubMed: 16624579]
24. Nichols TE, Holmes AP. Nonparametric permutation tests for functional neuroimaging: a primer with examples. *Hum Brain Mapp.* Jan; 2002 15(1):1–25. [PubMed: 11747097]
25. Della Nave R, Ginestroni A, Tessa C, et al. Regional distribution and clinical correlates of white matter structural damage in Huntington disease: a tract-based spatial statistics study. *AJNR Am J Neuroradiol.* Oct; 2010 31(9):1675–1681. [PubMed: 20488902]
26. Salat DH, Tuch DS, van der Kouwe AJ, et al. White matter pathology isolates the hippocampal formation in Alzheimer's disease. *Neurobiol Aging.* Feb; 2010 31(2):244–256. [PubMed: 18455835]
27. Acosta-Cabronero J, Williams GB, Pengas G, Nestor PJ. Absolute diffusivities define the landscape of white matter degeneration in Alzheimer's disease. *Brain.* Feb; 2010 133(Pt 2):529–539. [PubMed: 19914928]
28. Weaver KE, Richards TL, Liang O, Laurino MY, Sami A, Aylward EH. Longitudinal diffusion tensor imaging in Huntington's Disease. *Exp Neurol.* Jan 13.2009
29. Hoefl F, Barnea-Goraly N, Haas BW, et al. More is not always better: increased fractional anisotropy of superior longitudinal fasciculus associated with poor visuospatial abilities in Williams syndrome. *J Neurosci.* Oct 31; 2007 27(44):11960–11965. [PubMed: 17978036]
30. Lebel C, Caverhill-Godkewitsch S, Beaulieu C. Age-related regional variations of the corpus callosum identified by diffusion tensor tractography. *Neuroimage.* Aug 1; 2010 52(1):20–31. [PubMed: 20362683]



31. Song SK, Sun SW, Ju WK, Lin SJ, Cross AH, Neufeld AH. Diffusion tensor imaging detects and differentiates axon and myelin degeneration in mouse optic nerve after retinal ischemia. *Neuroimage*. Nov; 2003 20(3):1714–1722. [PubMed: 14642481]
32. Harsan LA, Poulet P, Guignard B, et al. Brain dysmyelination and recovery assessment by noninvasive in vivo diffusion tensor magnetic resonance imaging. *J Neurosci Res*. Feb 15; 2006 83(3):392–402. [PubMed: 16397901]
33. Concha L, Livy DJ, Beaulieu C, Wheatley BM, Gross DW. In vivo diffusion tensor imaging and histopathology of the fimbria-fornix in temporal lobe epilepsy. *J Neurosci*. Jan 20; 2010 30(3): 996–1002. [PubMed: 20089908]
34. Klawiter EC, Schmidt RE, Trinkaus K, et al. Radial diffusivity predicts demyelination in ex vivo multiple sclerosis spinal cords. *Neuroimage*. Apr 15; 2011 55(4):1454–1460. [PubMed: 21238597]
35. Sargin D, Friedrichs H, El-Kordi A, Ehrenreich H. Erythropoietin as neuroprotective and neuroregenerative treatment strategy: comprehensive overview of 12 years of preclinical and clinical research. *Best Pract Res Clin Anaesthesiol*. Dec; 2010 24(4):573–594. [PubMed: 21619868]
36. Juul SE, Yachnis AT, Rojiani AM, Christensen RD. Immunohistochemical localization of erythropoietin and its receptor in the developing human brain. *Pediatr Dev Pathol*. Mar-Apr;1999 2(2):148–158. [PubMed: 9949221]
37. Hartley CE, Varma M, Fischer JP, et al. Neuroprotective effects of erythropoietin on acute metabolic and pathological changes in experimentally induced neurotrauma. *J Neurosurg*. Oct; 2008 109(4):708–714. [PubMed: 18826359]
38. Gilman S, Junck L, Markel DS, Koeppe RA, Klun KJ. Cerebral glucose hypermetabolism in Friedreich's ataxia detected with positron emission tomography. *Ann Neurol*. Dec; 1990 28(6): 750–757. [PubMed: 2285262]



**Figure 1.**

(A, B) Areas of significant increase in fractional anisotropy (FA, red-yellow) and axial diffusivity (AD, blue) after therapy with recombinant human erythropoietin (rhuEPO) in patients with Friedreich ataxia (FRDA). Significance threshold was set to  $p < 0.05$ , family-wise error corrected.

In the background, the TBSS skeleton is shown in green, superimposed on a T1 weighted image. Images follow the radiological convention (right hemisphere is shown on the left).

Slices shown are at  $X = 12$ ,  $Y = 10$ ,  $Z = 37$  in MNI space. (C) Absolute values of FA and AD before and after rhuEPO therapy for each patient. For this graph, FA and AD were averaged over all voxels that showed a significant longitudinal increase in the respective diffusivity measure.

Table 1

Demographical and clinical data of the study participants

Patient ID	Age/Sex	GAA Repeats	DD	SARA	FARS		Therapy Duration	
					Pre	Post		
1	26/M	650	7	18	11.5	56	45	8
2	26/M	1000	12	26.5	24	86	84.5	8
3	46/M	800	14	23.5	18.5	68	55.5	8
6	51/F	190	15	20.5	10	44.5	35.5	8
7	29/F	320	9	21	11.5	52	37.7	8
8	32/M	370	10	14.5	9	36	36	8
9	29/F	1000	13	25.5	26.5	83	77	2
10	18/M	500	2	13	14	49	45	2
12	41/M	420	21	19	16.5	64	48	8

Notes: Patient ID in accordance with prior publications on this sample; 19, 20 age in years at study entry; M = male; F = female; GAA Repeats = number of GAA trinucleotide repeats on the shorter allele; DD = disease duration in years; SARA = Scale for the Assessment and Rating of Ataxia; FARS = Friedreich Ataxia Rating Scale; Pre = before treatment with rhuEPO; Post = after treatment with rhuEPO; Therapy Duration with rhuEPO in months.