

We are IntechOpen, the world's leading publisher of Open Access books Built by scientists, for scientists

5,900

Open access books available

145,000

International authors and editors

180M

Downloads

Our authors are among the

154

Countries delivered to

TOP 1%

most cited scientists

12.2%

Contributors from top 500 universities



WEB OF SCIENCE™

Selection of our books indexed in the Book Citation Index
in Web of Science™ Core Collection (BKCI)

Interested in publishing with us?
Contact book.department@intechopen.com

Numbers displayed above are based on latest data collected.
For more information visit www.intechopen.com



White Spots Lesions in Orthodontic Treatment and Fluoride — Clinical Evidence

Hakima Aghoutan, Sana Alami, Farid El Quars,
Samir Diouny and Farid Bourzgui

Additional information is available at the end of the chapter

<http://dx.doi.org/10.5772/59265>

1. Introduction

Orthodontic treatment aims to improve functions and facial aesthetics by ensuring harmonious occlusal and jaw relationship; with beneficial effects on the oral health and quality of life of patients. However, it also associates risks and complications. Enamel surface demineralization or white spots lesions (WSL) remain by far one of the major adverse sequelae of fixed orthodontic appliance therapy, despite techniques and materials advances in preventive dentistry and orthodontics. They appear during and sometimes persist after orthodontic treatment; they can compromise the successful outcome of the treatment and result in the early termination of treatment. In severe cases of WSL, invasive interventions can be required and clinician responsibility may also be engaged.

WSL seem to be related to the interaction of several factors including inadequate elimination of dental plaque due to intrabuccal appliances that limit the self-cleansing mechanism of the oral musculature and saliva, patient's modifying factors and change in bacterial flora during fixed appliances wear. [1, 2]

Considering how quickly these lesions can develop, prevention, early diagnosis and treatment remain one of the greatest challenges facing orthodontists and requires a thorough knowledge of the caries disease and the risk factors specific to each patient. These risk factors should be accurately evaluated before and during any orthodontic treatment in order to minimize tooth decay and discoloration that could compromise the aesthetic of smile. Early detection of WSL during orthodontic treatment would allow clinicians to implement preventive measures to control the demineralization process before lesions progress.

The non-invasive prophylactic techniques are of critical importance during orthodontic treatment in order to decrease the incidence of demineralization. They involve either decreasing the amount of plaque by maintaining good dietary and oral hygiene, or tackling the susceptibility of enamel to demineralization [3]. Among suitable caries preventative agents, fluoride agents are usually used to reduce enamel decalcification and enhance its mineralization since fluoride contains bactericide and bacteriostatic properties.

The aim of this chapter is to outline the evidence regarding the effectiveness of fluoride administration in the prevention and management of WSL during orthodontic treatment.

2. White spot lesions in orthodontic treatment

WSLs have been defined as “subsurface enamel porosity from carious demineralization” that is located on smooth surfaces and presents as “a milky white opacity” [4] due to consequential changes in the optical properties of the enamel [1]. Various risk factors can contribute to the development of these incipient lesions. Poor oral hygiene, low salivary volume and a sugary diet promote the proliferation and activity of the microbial biofilm for a period of time. Orthodontic treatments are known as non-negligible factors and equal susceptibility has been reported whether teeth are banded or bonded.

The levels of oral bacteria have been reported to increase five folds upon the application of fixed bonds [5]. So orthodontic patients develop significantly more WSLs than non-orthodontic patients [1, 4]. The fitting of fixed orthodontic appliances (figure 1) (brackets, bands, arch wires, springs, elastomeric modules...) makes oral hygiene very difficult, restricts salivary self-cleaning and creates more stagnation areas for plaque; encouraging a lowering of plaque pH in the presence of carbohydrates and forming a physical barrier prevent remineralization by calcium and phosphate ions from the saliva. All these changes in the oral ecosystem favor colonization of aciduric bacteria, resulting in a rise in the levels of mutans streptococci and lactobacilli, mainly around the bonding adhesives [6, 7]. This can disrupt balance between the processes of demineralization and remineralization in favor of demineralization, and would lead to the permanent formation of white spot lesions. To these conditions, one must add the duration of orthodontic treatment: the longer the time of oral appliances’ wearing is; the most prolonged the caries risk is. WSLs can develop into cavities and can no longer be reversed even in smooth surfaces that would normally have a low risk of caries [5, 8]. Tipping the balance back toward remineralization is the basis of WSL treatment although they can remain as cosmetic scars. However, even if high levels of mutans streptococci and lactobacilli in plaque indicate an increased risk of caries, the prediction of caries development based on bacterial counts is uncertain and it is of minor clinical significance [1, 9].

On the other hand, resting salivary flow rate rises during fixed appliance therapy; which increases salivary pH and buffer capacity and thus counteract the tendency for demineralization to occur around orthodontic appliances in some patients despite moderate plaque scores. This is especially true in individuals with good dietary regimen [5, 9]. Therefore, an assessment of patients’ susceptibility In order to identify those most at risk of demineralization prior to

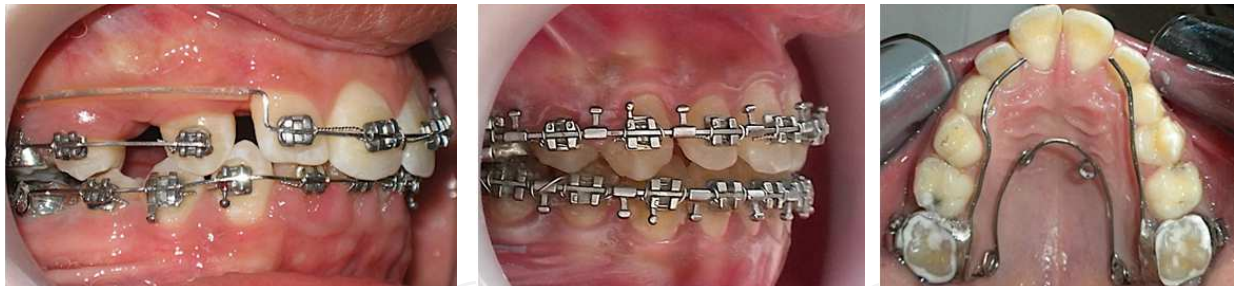

Figure 1. Fixed oral appliances increase stagnation areas of plaque and make oral hygiene difficult to carry out.

orthodontic treatment seems decisive. It was shown that subclinical demineralization before treatment may be a factor in the incidence of WSL during fixed appliance treatment [8].

In addition, orthodontic treatment is most often applied during adolescence, when the permanent teeth, recently erupted, are more vulnerable to caries because of their young enamel. Consequently, orthodontic treatment at this age will favor the formation of carious lesions in particular with the lack of cooperation encountered more frequently in this age group [10].

Commonly identified when the teeth are dry, WSL appears clinically as an opaque whitish or greyish halo under loose bands and around the bracket base periphery generally at the junction between the cement and the enamel, and at the gum level at the base of the half moon bracket (Figure 2). Studies show that these lesions can appear within a span of 4 weeks [11], which is even shorter than the time between two sessions of orthodontic appointments. Caries lesions may also develop after debonding in association with bonded retainer [1]. Furthermore, appliances' removing and tooth polishing cause a loss of the superficial enamel layer, rich in fluorine. This favors plaque retention due to porous enamel surface and thus decalcification. However, these alterations can gradually fade with natural abrasion and hygiene measures.

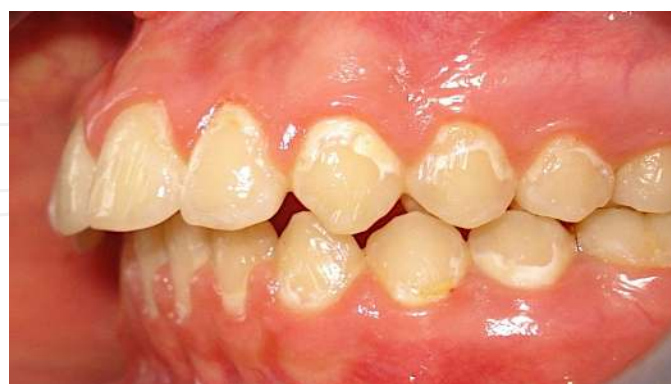

Figure 2. White spot lesions after orthodontic treatment localized at the gingival areas of teeth.

Since Zachrisson and Zachrisson (1971), WSL has been reported as a clinical observation [12]. Over the years, quantitative studies on decalcification incidence and prevalence have been reported. Depending on the examination technique used, the prevalence of WSL varies widely

in the literature. It ranges from 23% and 89% when the teeth have been inspected using visual scales and photographic evaluation [8, 13-16].

Boersma et al. [16], using quantitative light fluoroscopy, investigated the prevalence of WSLs at the end of orthodontic treatment and reported that 97% of subjects had one or more lesions and on average, 30% of the buccal surfaces in a person were affected.

The large variation in reported prevalence may also be due to sample size disparity, the use or otherwise of a fluoride regimen during treatment and whether developmental or not other idiopathic enamel lesions, which artificially increases the prevalence quoted, are included or excluded [18].

Clinical studies [8, 13, 15, 19] have showed a sharp increase in the number of WSL during the first 6 months of treatment that continued to rise at a slower rate to 12 months; supporting the idea that the presence of fixed orthodontic appliances and greater treatment lengths serve as a risk factor for WSL formation. Hence, oral hygiene status of patients should be evaluated during the initial months of treatment and, if necessary, measures to prevent demineralization should be implemented.

With regard to the location of these lesions, studies have shown a significant increase in the prevalence on the cervical and middle thirds of the crowns. But they can broadly extend over the teeth surface and sometimes involve proximal extensions. The teeth most vulnerable to demineralization are the first permanent molars, the maxillary incisors, the mandibular lateral incisors and canines [1, 16, 18]. Premolars have also been reported to have greater frequency of WSL [8], and the lowest incidence was in the maxillary posterior segment. According to Samawi 2005 [In 18], upper anterior teeth showed larger mean demineralization surface area than anterior teeth in the lower arch; and the distogingival quadrant was particularly more affected than the mesiogingival quadrant in the upper lateral incisor teeth.

In a study conducted by Arneberg and coworkers [20], the bonded upper incisors have presented the lowest levels of total plaque fluoride and the lowest PH (as low as 4) during resting and fermenting conditions. This can be explained by both a prolonged retention of acids in plaque due to the slow salivary clearance at these sites, and also by loss of fluoride reservoirs associated with limited cariostatic effect of fluoride under low PH.

Regardless of WSL treatment approach, these conditions are difficult to treat and recover to some extent depending on the degree of their severity. Currently, there is a lack of conclusive long-term studies on WSL modifications after orthodontic treatment, but some clinical data can be stated. Once the orthodontic appliances have been removed and oral hygiene is restored, the area of WS was shown to decrease markedly during the first and second years following treatment [21, 22]. The most likely reason for this clinical healing can be explained by removal of the primary etiologic factor which is the cariogenic plaque adhered to fixed orthodontic elements, combined with enamel surface wear during tooth brushing and also by remineralization [1, 22]. However, some spots secondary to debonding can last from 6 to 12 years [22, 23] and do not reach the pre-treatment level even 12 years after debonding [22]. Natural remineralization through saliva, involving mineral gain in the surface layer of WSL, has little improvement on the aesthetics and structural properties of the deeper lesions [24]. Evidence

of success is characterized clinically by the recuperation of hardness and shine, whereas translucency is not always recovered. Indeed, WSL can take up stain and become discolored after many years. Therefore, it is necessary to apply remineralizing agents as early as possible for better aesthetic results.

3. Fluoride in management of orthodontic-related white spot lesions

Patients wearing orthodontic appliances are considered as patients at risk, for whom a preventive approach should be implemented before, during and after orthodontic treatment. Controlling risk factors, in addition to awareness of bucco-dental hygiene, and early diagnosis of WSL are key elements of success to reduce their prevalence and incidence during orthodontic treatment.

Both office-applied and self-care programs have been described for preventive and curative approaches of WSL. In self-administered programs, compliance has been identified as a significant problem.

Little information is available about measures that are really used in orthodontic practices to prevent and treat demineralization. But several procedures have been described in association with oral-hygiene instructions and patients' motivation. Reducing enamel susceptibility to demineralization by periodical professional fluoride application and varnishing reside at the bottom of the intervention hierarchy, and therefore represents the frontline of incipient caries treatment.

Actually, it has been known for many years that fluoride reduces the incidence of dental caries by maintaining the plaque fluoride supersaturated with respect to Fluorapatite, hence tipping the balance of the caries process in favor of remineralization. While full mineral recovery might be achieved through fluoride measures in the case of shallow enamel lesions in both children and adults, long-existing white spot lesions have demonstrated negligible remineralization after further contact with fluorides [25]. Upon failure of remineralization measures by fluoride agents in active lesions, other conservative procedures, such as resin sealing, have been advocated as alternative measures to prevent demineralization progression and cavitation.

There are two main methods of fluoride administration. However, there is little evidence about which fluoride supplement provides the greatest decrease in decalcification: In topical form, active ingredients are supplied in forms such as a toothpaste, mouth rinse, gel, varnish, mousse, pastille, or by adding it to chewing gum. Professionals usually apply gels and varnishes, particularly if they contain a high concentration of fluoride, whereas the other means of topical application can be self-administered. The second way is the use of materials containing the active ingredient fluoride as part of the appliance, either as a bonding or banding material, or an auxiliary such as a glass bead or elastic [3].

When topical fluoride is applied, a calcium fluoride-like material (CaF_2) builds up in plaque, on the tooth surface or in incipient lesions. The CaF_2 acts as a reservoir of fluoride ions for release when pH is lowered during a carious attack. When associated with phosphate ions,

CaF₂ becomes more soluble and release fluoride at higher rate than the pure substance [1]. The preventive effect of fluoride can be illustrated using the Stephan curve (Figure 3). The limit of the fluoride effect is reached when pH drops below 4.5 so the solubility product of pure Fluorapatite is exceeded and no remineralization occurs. In old, acidic plaque a dose response to fluoride may not be apparent against lesion progression due to the low pH [26].

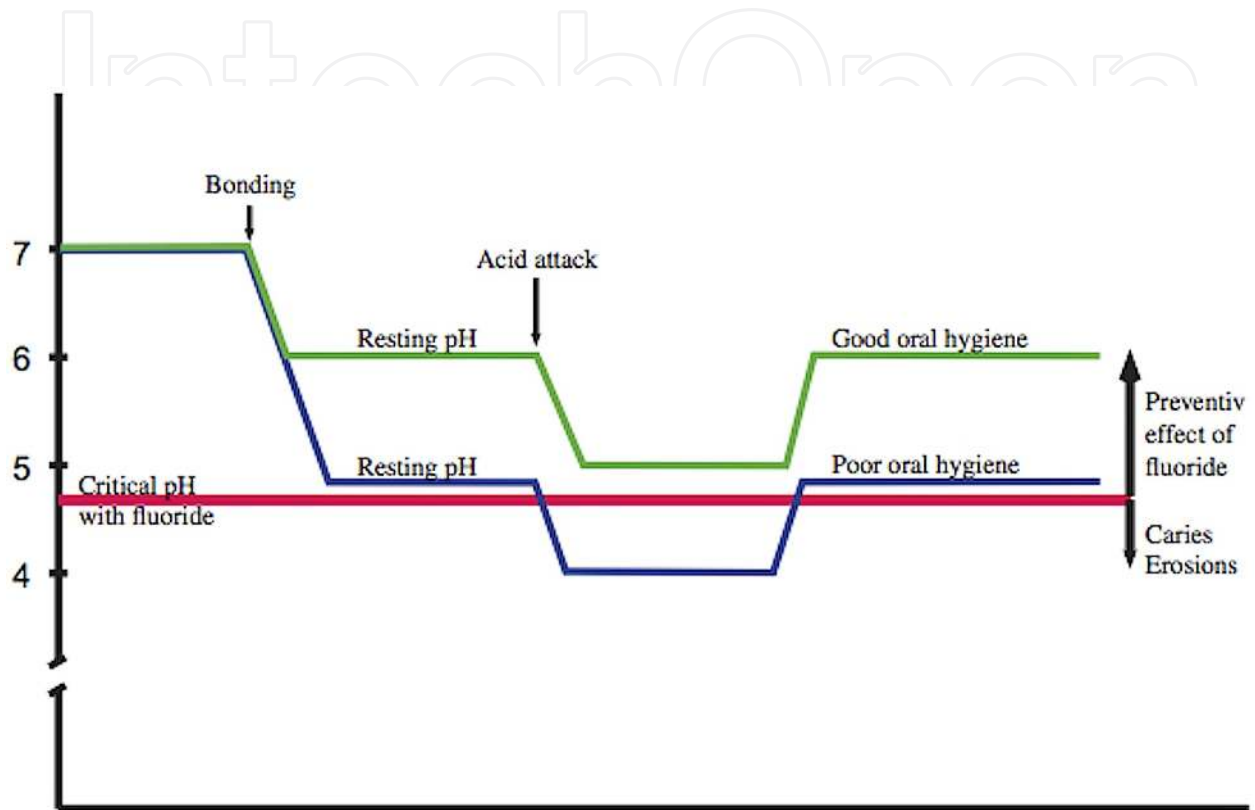


Figure 3. The Stephan curves in orthodontic patients with good or bad oral hygiene. After bonding, resting pH is lowered. An acid attack lowers the pH in the patient with bad oral hygiene below the critical pH of enamel. Assuming fluoride is frequently used, the critical pH of enamel is around 4.5 compared with 5.5 in the absence of fluoride. In the patient with good oral hygiene, fluoride is able to prevent lesions to develop. [1]

All these findings make optimal oral hygiene a crucial element that should be associated with fluoride prevention against WSL. Orthodontist must be cautious to create more favorable conditions to implement good oral hygiene by patients. Hence, the close fitting of bands on teeth is recommended and all excess bonding material around the attachment base should be eliminated. Also excessive surplus orthodontic etching of the complete labial enamel surface, instead of the bracket bases only, must be avoided to prevent iatrogenic white spot lesions [27], and steel ligatures or self-ligating brackets must be preferable to elastic ligatures [28]. (Figure 4)

According to Øgaard [1, 26], it is logical to differentiate between prevention of caries lesion development during orthodontic treatment and treatment of lesions present on labial surfaces at debonding. Clinical approaches differ in the two situations.

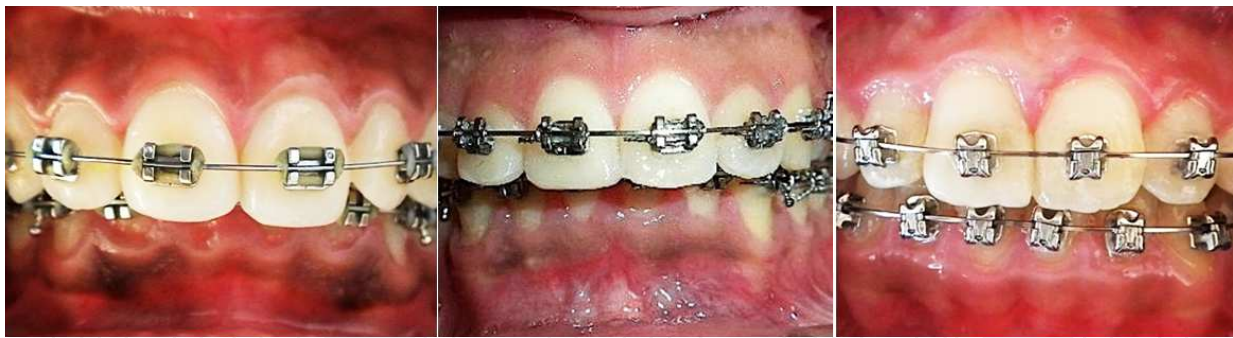

Figure 4. Different styles of ligatures: elastic ligatures (left) tend to discolor and increase the risk of plaque aggregation.

3.1. Fluoride prevention during orthodontic treatment

3.1.1. Oral-hygiene instructions

Clinical maintenance by elimination of plaque and food debris is essential throughout any orthodontic treatment as there is a much stronger relationship between oral hygiene and caries incidence in orthodontic patients than in non-treated individuals [26]. Therefore satisfactory level of oral hygiene should be successfully maintained despite the hindrance of the appliance.

Among the self-applied fluoride products available, toothpaste used in tooth brushing is thought to be the most important. Fluoridated toothpaste exerts a cariostatic effect. It increases fluoride levels in the biofilm, where it acts as an inhibitor of bacterial enzymes, and can reduce the frequency of caries by 15–30% [29]. Authors [30] have emphasized the need for at least two daily brushings in order to favor a continuous exchange of fluoride ions between the salivary and the enamel surface. The availability of fluoride from toothpaste is influenced by several factors, such as the concentration of fluoride, the amount of toothpaste used, and the post-brushing behavior (Davies and Davies, 2008; Zero et al., 2010 (In [31])). The fluoride concentration in toothpaste has traditionally been limited to 1450 ppm F; but in multicenter randomized controlled trial [31], authors have reported that daily use of high-fluoride (5000ppm) toothpaste may be recommended to prevent WSL during fixed oral appliances. This corroborates with other studies [32] that stipulate that the relative caries preventive effects of fluoride toothpastes of different concentrations increase with higher fluoride concentration. Fluoride concentrations below 0.1% should not to be recommended for orthodontic patients [1].

The daily use of a fluoride mouth rinse throughout brace treatment to prevent WSL is also highly recommended [33–34]. It was demonstrated that the daily use of a 0.05% sodium fluoride rinse during orthodontic treatment resulted in a statistically significant reduction of enamel white spot lesions. The more closely patients adhered to this rinsing regimen the more likely they exhibited a decrease in the occurrence of white spot lesions. The dose response effect between the frequency of rinsing and the incidence of white spots was evident regardless of oral hygiene status [34]. Besides self-controlled oral hygiene, professional prophylactic

cleaning using fluoridated pastes is designed to reduce bacterial load and enhance the efficacy of brushing mainly in difficult areas around appliances [35].

3.1.2. In office-applied topical fluorotherapy

Use of additional topical fluorides designed to deliver additional fluoride to the tooth surface at-risk area near orthodontic brackets is likely to reduce the risk of DWL development. In a review conducted in 2103 [36], the authors found some moderate evidence that fluoride varnish applied every six weeks at the time of orthodontic review during treatment is effective. It has also been reported that the application of a fluoride varnish resulted in a 44.3% reduction in enamel demineralization in orthodontic patients [37], and there were significantly fewer new demineralized white lesions in the patients that had the application of the fluoride varnish at each visit compared with the placebo varnish [38].

Additionally, with in office-applied fluoride varnishes, the amounts of fluoride exposure can be controlled better and does not depend on patients' compliance. However, there is a limitation on the frequency of fluoride exposures received since the application occurs in the clinician's office only. In addition, the repeated varnish applications may lead to the temporary discoloration of the teeth and gingival tissue, and increase costs to the patient and/or chair time to the clinician [4]. In order to enhance the cariostatic potential of current fluoride agents and procedures for orthodontic purposes, substance like titanium fluoride or stannous fluoride has been described to reduce lesion depths and total mineral loss when compared to conventional fluoride preparations. The acid resistant coating deposited from these solutions can protect the enamel surface against severe acid challenges from plaque with low pH [1, 39, 40] (Figure 5).

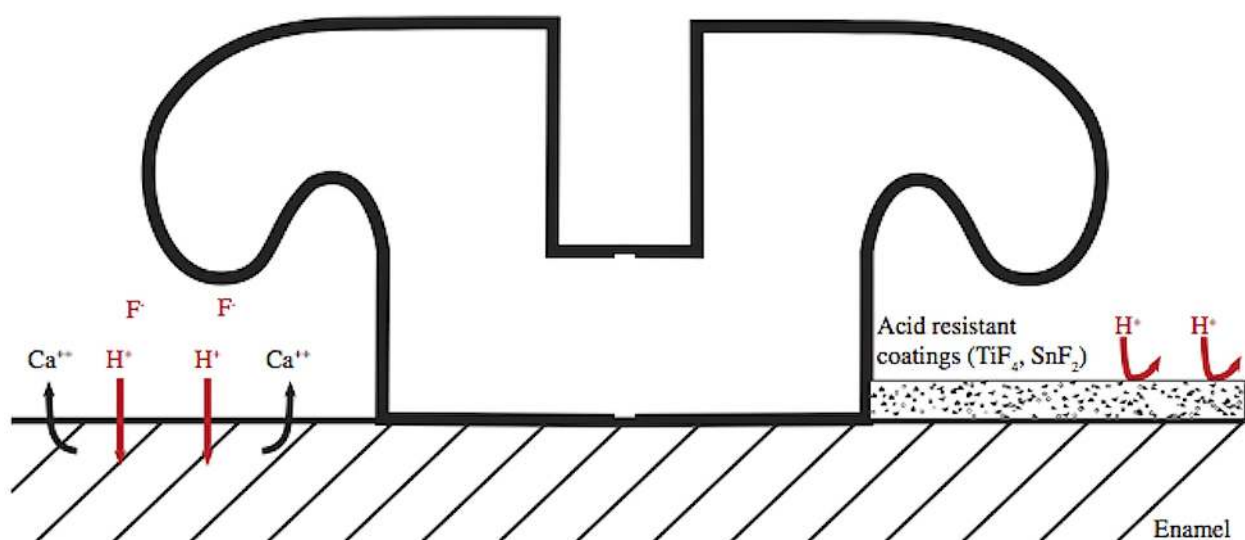


Figure 5. Acid resistant coating deposited from titanium fluoride or stannous fluoride, protect the enamel surface against severe acid challenges (H⁺ions under the right bracket wing). Conventional fluoride preparations have a reduced cariostatic effect in plaque with low pH (under the left bracket wing). Ca²⁺loss illustrates the caries process [1].

The use of antimicrobials like Chlorhexidene, as a complement to fluoride therapy, has also demonstrated demineralization-inhibiting tendencies in patients with fixed orthodontic appliances to reduce WSL at the time of debonding when compared with a control group [1, 4, 23, 26]. Chlorhexidene varnishes for long-term use may reduce the cariogenic challenge sufficiently to improve the fluoride effect on WSL instead daily Chlorhexidene rinsing, which is a well-known cause of teeth and tongue discoloration [23]. In this context, the use of products combining fluorides and antimicrobial agents should be seriously considered, especially among patients with a lack of motivation to maintain optimal oral hygiene, provided that such products do not significantly decrease mechanical properties of the adhesive system used [4].

On the other hand, if fluoride use may be beneficial for WSL prevention during orthodontic treatment, it can have conversely unwanted effects on properties of orthodontic alloys. In the presence of fluoride, β titanium, currently used for his elasticity and corrosion resistance, can undergo a degradation process and be affected in terms of biological and mechanical features. Thus, coating with TiAlN (deposing thin films of titanium aluminium nitride) has been recommended [41] in order to reduce the corrosive effects of fluorides on β titanium orthodontic archwires. Likewise, fluoride attacks the protective oxide surface film on Nickel-Titanium wires causing corrosion and nickel release, which increases with increasing fluoride concentration [42]. Some authors have recommended diamond-like carbon (DLC) coatings onto nickel-titanium wires to reduce fluoride-induced corrosion and improve orthodontic friction [43].

3.1.3. Fluoride-releasing materials used in orthodontic practice

While compliance with preventive protocols at home is the most frequently difficult to obtain [44], it would be an advantage if bonding materials could inhibit demineralization near the brackets. Presently, it seems impossible to make recommendations on the use of fluoride-containing orthodontic materials during fixed orthodontic treatment. However, it is advantageous to report some studies outcomes.

Using fluoride containing sealants and adhesives to bond brackets has been attempted. Glass ionomer cements (GIC) were initially introduced as orthodontic bonding adhesives for their ability to chemically bond to tooth structure and their sustained fluoride release following bonding. Resin particles were added to their formulation to create Resin-modified glass ionomer cements (RMGIC). These bonding systems have been developed to combine the desirable properties of composite resin bond strength and glass ionomer fluoride release. Studies have shown that RMGIC is more effective than an acrylic-bonding agent in preventing white spot formation, but weak evidence was reported [22, 45]. It has been suggested that these adhesives should be more widely used in bonding orthodontic brackets [46] particularly on the maxillary incisors that represent a significant aesthetic challenge to both the patient and the orthodontist.

Additionally, filled and fluoride releasing sealant may offer more enamel protection next to orthodontic brackets exposed to cariogenic conditions, mainly in patients with poor oral hygiene [47, 48]. Their application has been shown to not affect the shear bond strength (SBS) of orthodontic adhesives, and they are able to produce a sustained fluoride release [4, 42]. It

was also found out that using the combination of an antimicrobial self-etching primer and a fluoride-releasing adhesive had acceptable bond strength for clinical use [49]. However, the clinical effectiveness of the fluoride release may be questionable, as the amount of fluoride required from a bonding material to be caries preventive is still unknown [50].

Resin composite bonding system with the ability of fluoride release was also developed for bracket bonding. An in-vitro study using nano-indentation test to evaluate the nano-mechanical properties of the enamel around and beneath orthodontic brackets, has showed that use of these product may reduce demineralization during orthodontic treatment [51].

3.2. Fluoride use after orthodontic treatment

The best treatment of WSL begins with a preventive approach, as they are difficult to recover especially in severe cases. In addition, White spot lesions treatment after appliance removal to produce a sound and aesthetically pleasing enamel surface is still a question to be fully answered. As patients respond differently to the presence of WSL, the course of treatment will likely be unique to each patient [4].

Debonding the orthodontic appliances eliminates an important cariogenic environment. However, the removal of stagnant plaque alone is not enough to achieve complete repair of WSL, and some spots secondary to debonding can last from 5 to 12 years [22, 52]. Evaluation of lesions that have developed during appliance therapy in the different sites of the dentition represents a clinical challenge for orthodontists [1]. Initial surface-softened lesions appear to remineralize quickly in saliva even without fluoride [53]. Resolution is thought to occur via the redistribution of various minerals soluble in saliva, particularly calcium, phosphate, and fluoride, but also and primarily via surface wear exposing the underlying enamel crystals, which are tightly packed and thus provide proper light reflection [54]. When arrested, they may exhibit a white color or may become yellowish or dark brown due to exogenous uptake of stains.

In general, treatment of WSL should begin with the most conservative approaches. If such approaches do not resolve the problem to the clinician's satisfaction, more aggressive treatment modalities can be pursued if the patient is interested (micro-abrasion, composite restorations, tooth whitening, porcelain veneers....)

Although the treatment of post-orthodontic WSL differs from their prevention, topical fluoride is thought to be the first step in WSL management. Based on the literature, and compared with the evidence on the WSL forestalling during orthodontic treatment, there is a lack of reliable evidence to support the effectiveness of remineralizing agents for the treatment of post-orthodontic white spot lesions [52, 55-56]. Nevertheless, for mild WSL, application of lower concentrations of fluorides can be used in an attempt to arrest their progression with successful and more aesthetic treatment results since hypermineralization maintains the whiteness of the lesions. Indeed, direct application of a high concentration of fluoride is not recommended as it causes rapid remineralization of the enamel surface, which restricts the passage of ions into the deeper, more affected layers, and limits their complete recovery [4, 57].

Finally, it has been suggested that acid etching of WSLs may increase the surface porosity and hence remineralization [1]. However, a study by Al-Khateeb et al (2000) [58] has shown lack of complete remineralization, and the etched lesions retained a porous structure of their surface layer even after a long period of remineralization in vitro.

4. Experience of Casablanca Dental School in fluoride use during orthodontic treatment

A clinical study was conducted for 10 months and 3 days in the Department of Dento Facial Orthopedics at the Faculty of Dentistry in Casablanca to determine the incidence of WSL in orthodontic population and to evaluate the fluoride varnish effect on the prevention and remineralization of carious lesions generated by orthodontic treatment.

5. Method framework

All patients starting treatment at the Dentofacial Orthopedics Unit from December 2010 to April 2011 were selected. The survey included healthy patients aged from 12 to 27 years old, and for whom treatment duration was estimated at more than 6 months. Patients with anterior restorations (composite, glass ionomer, endodontic treatment) or prosthetic devices, those displaying tooth tissue abnormalities (fluorosis, amelogenesis imperfecta, WSL....) or following preventive fluoride regimens (except toothpaste) and those with orthodontic treatment history were excluded. A total of 68 consecutive orthodontic patients fulfilled the eligibility criteria and were approached to participate.

This was a prospective study that has been made in the form of Crossover, which exposes teeth to the same factors: Oral hygiene, saliva composition, and enamel's structure. All patients were fitted with multi-bracket appliance and the same bonding system. The right side, from the central incisor to the first molar, has received a fluoride varnish (Fluor Protector 0, 1% F, Ivoclar Vivadent, Schaan, Liechtenstein) while the left side was taken as control. Before applying the varnish, an evaluation of oral hygiene status was recorded via plaque quantification for each tooth in both lower and upper arch. WSL were evaluated by naked eye after teeth brushing and drying with air spray, and scored depending on their severity and location according to the modified White spot lesion index (WSL-Index) by Gorelick et al. (1982) [59]. The visual evaluation of the individual teeth was based on a labial surface examination assessing the presence or absence of WSL. The severity of WSL was scored as follows: (Figure 6, 7)

- (0)=No white spot lesion formation
- (1)=Slight white spot or line formation
- (2)=Excessive white spot formation
- (3)=White spot formation with cavitations

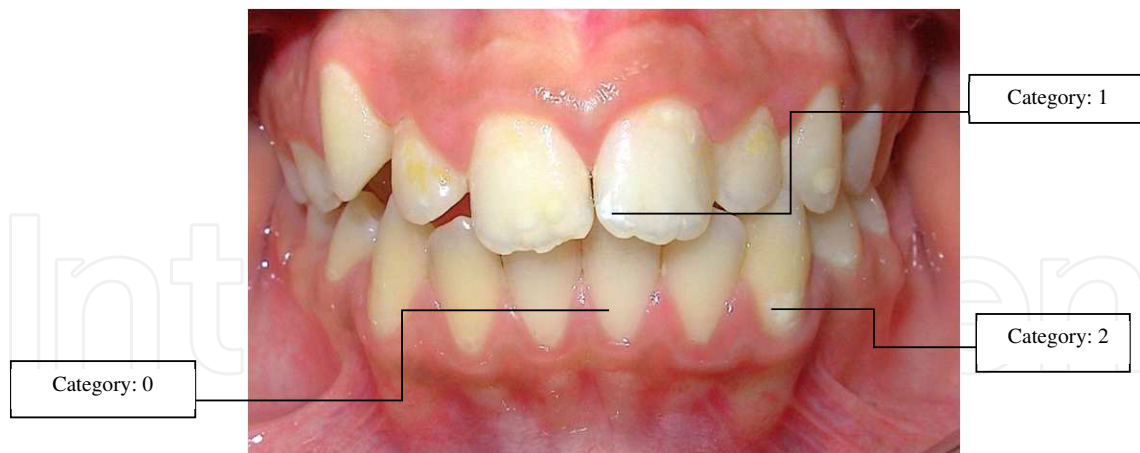

Figure 6. Evaluation of WSL 0, 1 and 2

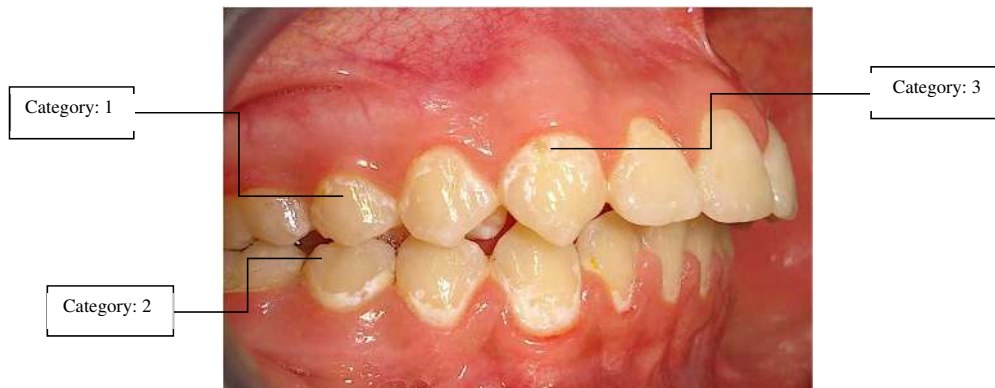

Figure 7. Evaluation of WSL 1, 2 and 3

Patients were notified about the importance of complying with the recommendations advocated by the manufacturer: Avoid eating and brushing teeth for 45 min after the application of fluoride varnish. The varnish was applied every 6 weeks for a six-month period. After every 6 weeks, the plaque index and the WSL formation have been evaluated for all the teeth in two arches.

In total, we conducted 5 applications of fluoride varnish during the 6 months of the study. The statistical analysis of the data was performed using the software Epi6.0 fr.

6. Results

From 68 selected, only 30 patients have been recruited for the study. 38 were excluded from the study because they did not respect their periodic appointments, they did not show up

The sample study was distributed as follows: (figure 8-10)

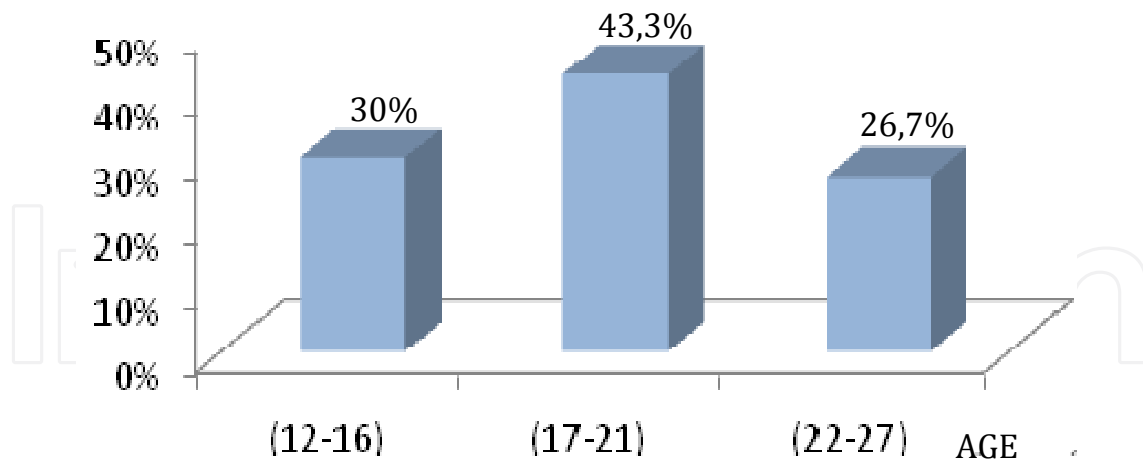


Figure 8. Sample distribution by age

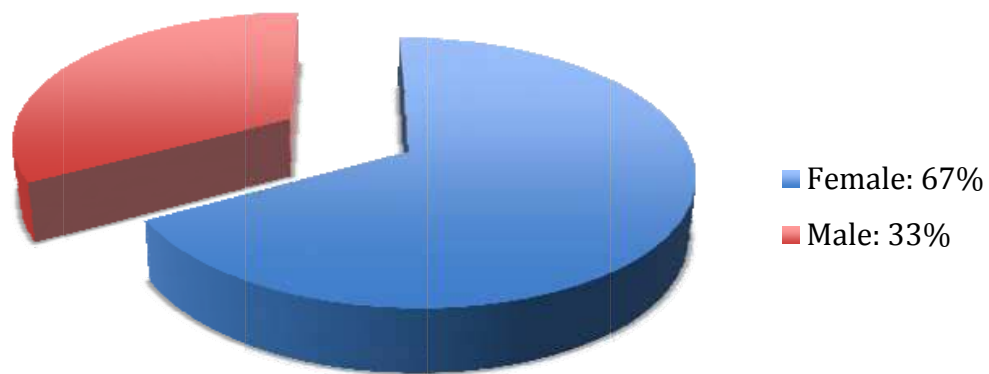


Figure 9. Sample distribution by sex

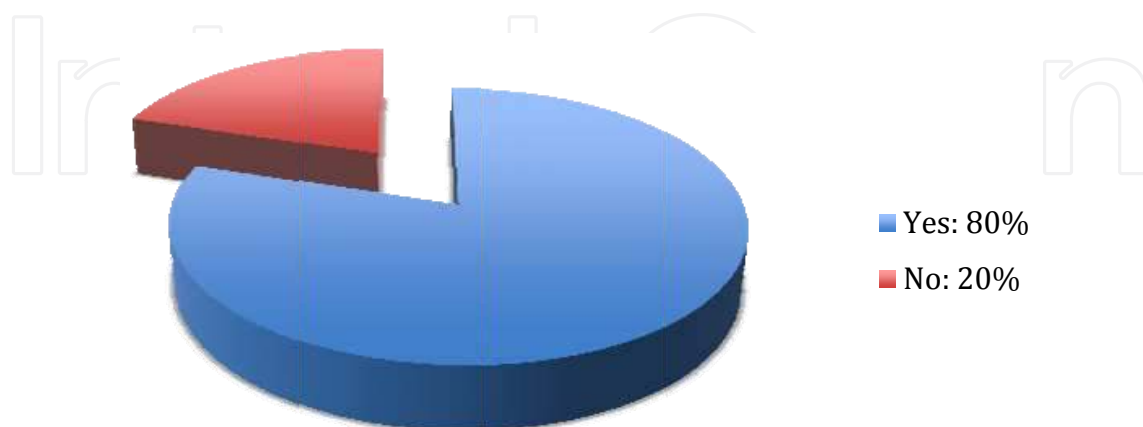


Figure 10. Sample distribution according to the sugary diet

Oral hygiene was evaluated by the frequency and method of brushing as well as the amount of plaque (table 1). The vertical brushing method was the most used by study's patients, and 73,3% used no way adjuvant for their daily tooth brushing. According to the saliva parameters, 76,7% of patients had a normal salivation and 63,3% had fluid saliva.

Plaque	Appointment n°1		Appointment n°2		Appointment n°3		Appointment n°4		Appointment n°5	
	Number	%	Number	%	Number	%	Number	%	Number	%
0≤P<1	15	50,0	15	50,0	18	60,0	20	66,7	21	70,0
1≤P<2	12	40,0	11	36,7	12	40,0	9	30,0	9	30,0
P≥2	3	10,0	4	13,3	0	0,0	1	3,3	0	0,0
Total	30	100	30	100	30	100	30	100	30	100

Table 1. Distribution of the study's sample according to the plaque amount

In the test group of teeth, the incidence of WSL was 60% versus 66.7% in the control group. In addition, 55.5% of female patients and 44.5% of male patients have developed WSL against 56,5% and 43,5% respectively in the control group.

On the other hand, 73.7% patients with snacking habit have developed at least one WSL versus 72,7% in those without this practice. No association was found between the habit of snacking and the appearance of WSL. The frequency of people who had at least one WSL increases according to the number of snack, but the difference was not significant (table 2). Likewise and paradoxically, there was more WSL among those without sugary diet compared with those who consumed more sweet foods, but the difference was not significant. The saliva parameters have also been considered. The X² test (P=0.71) has shown no association between the quality and the quantity of saliva and the appearance of WSL (table 3-4).

Both in the group of teeth test than in the control group, there was at baseline more of WSL among patients with mediocre and average oral hygiene compared with those who had good hygiene. By the end of the study, the opposite was observed. But in both cases, the difference was not significant.

As for varnish effect, there were fewer WSL in the teeth having benefited from fluoride varnish compared with the contralateral, but the difference was not significant. The relative risk was 0.73 with a confidence interval of [0.49-1.09]. It was < 1, which seems to be in favor of fluoride varnish. This reflects that fluoride is a protective factor, but we cannot draw any conclusions conclude on the basis of the results of the confidence interval of the relative risk (table 5).

Snacks number	0		1		2		3	
	Number	%	Number	%	Number	%	Number	%
WSL presence	8	72.7%	8	72.7%	6	85.7%	0	0,0%
WSL absence	3	27.3%	3	27.3%	1	14.3%	1	100,0%
X ² = 3,30	p = 0,34				No significant difference			

Table 2. Association between snacks number and WSL formation

	Hyper salivation		Normal salivation	
	Number	%	Number	%
WSL presence	5	71.4%	17	73.9%
WSL absence	2	28.6%	6	26.1%
$\chi^2 = 0, 02$	$p = 0, 62$		No significant difference	

Table 3. Association between saliva quantity and WSL formation

	Viscous Saliva		Fluid Saliva	
	Number	%	Number	%
WSL presence	8	72.7%	14	73.7%
WSL absence	3	27.3%	5	26.3%
$\chi^2 = 0, 14$	$p = 0, 71$		No significant difference	

Table 4. Association between saliva quality and WSL formation

	WSL presence	WSL absence	Total
Test group	33	172	205
Control group	46	163	209
$\chi^2 = 0, 92$	$p = 0, 12$		No significant difference

Table 5. Evaluation of the occurrence of WSL

7. Discussion

During this investigation, we have tried to avoid bias in order to obtain valid results and overcome some difficulties regarding:

- The lack of cooperation and refusal of participation of some patients.
- The lack of reliability concerning oral hygiene and dietary habits.
- The non-respect of appointments
- Gingival inflammation of the maxillary premolars after the brackets location and poor hygiene. So the cervical zone was often weakly induced by fluoride varnish.

7.1. Discussion of the findings

As discussed above, identification of risk factors of carious lesions is a necessary step before any orthodontic treatment is undertaken. In this respect, dietary habits are of great importance.

Beyond the amount of sugar ingested, the frequency of the daily ingestion maintains oral PH in critical levels, and thus, leads to the development of the caries process.

A study conducted on 155 patients in the Department of Dentofacial Orthopedics at Casablanca Dental School to evaluate the prevalence of dental caries and associated risk factors in orthodontics (Bourzgui et al, 2010) [60], showed that 31, 6% of patients had an excessive sugary diet and 45, 8% had a snack habit. In the present investigation, this estimation was 80% and 63, 3%, respectively. However, the association between WSL formation and the dietary habits (number of meals, snacking and consumption of sugary diets) was not significant.

The fitting of orthodontic appliances causes adverse changes in the composition of the bacterial plaque increasing radically periodontal and caries risk. Adolescents following orthodontic treatment are considered to be high-risk patients and they need more motivation, hygiene control and use of topical fluoride [61]. Good individual control of dental plaque associated with a daily use of topical fluoride per toothpaste remains the most effective way. Patients with good oral hygiene during fixed orthodontic treatment have less prevalence of enamel decalcification. Simple daily oral hygiene procedures have shown a reduction in these decalcifications. Four factors influence the effectiveness of oral brushing: The frequency of brushing, brushing length, the concentration of fluoride and rinse after brushing. Oral brushing should be done at least twice a day and for a longer duration. The high fluoride concentration toothpaste is recommended. The use of fluoride supplementation (fluoride mouthrinse, varnishes, gel...) is of great interest to prevent WSL and reduce their severity [62]. Our study has shown a slight improvement in the frequency of brushing (43.3% brushed three times per day at the beginning of the investigation versus 53.3% at the end) with a non-significant difference between the WSL occurrence and the brushing frequency.

Additionally, all teeth have presented at least one demineralization except the first right upper Premolar. However, some patients presented a total lack of demineralization. The previous study conducted in the same Dental Clinic [60] showed that 7.7% of patients developed whit spots during their orthodontic treatment, with a similar distribution between front and posterior areas of the arches. Our study has shown that the most affected tooth in the control group was the first molar, followed by upper lateral incisor, upper cuspid, and then premolar group. While in the experimental group, the lateral incisor was the most affected, followed by canines, and the premolar group (Figures 11-12). The lateral incisors in some cases had a palatine position at the base, and they thereby were subject concurrently to the fastest accumulation of plaque due to the cleaning difficulty.

In the literature, all the studies conducted so far have used different fluoride concentration with different application frequencies (Table 6). The findings consolidated the use of topical fluorides in addition to fluoride toothpaste as the best evidence-based way to forestall these incipient lesions. Regular high fluoride varnish application around the brackets is the most effective topical method. It is a quick and easy professional application with conservation and a slow-release fluoride for an extended time period. Also, it is usefully independent of patients' compliance [63]. In our study, the incidence of whit lesions in the control group was slightly higher than the test group. However, the chi-2 test was not significant, so according to our study, there was no association between the application of fluoride varnish and the appearance

of whitish lesions; this could be explained by the fact that our sample was small and the duration of our study was short. In this study, fluoride varnish reduced the severity of lesions, but it did not prevent their appearance.

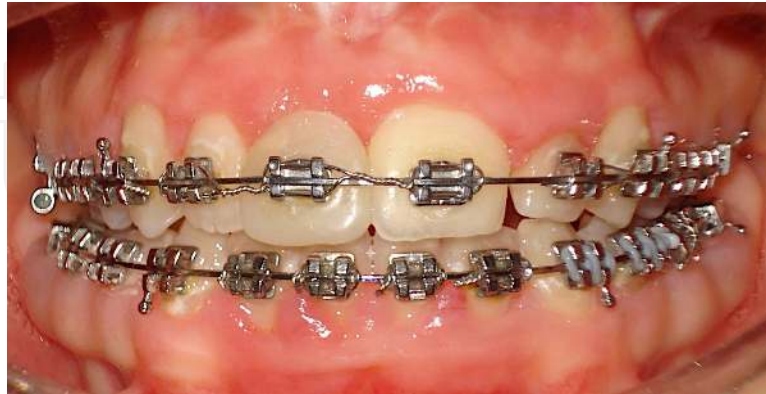

Figure 11. WSL on cervical area on lower and upper incisors and cuspids during orthodontic treatment.

Authors (year)	Sample	Fluoride varnish	Frequency	Results	Incidence Test/ control
Gontijo (2007)	16 teeth	Duraphat 22600 ppm	One application	Significant Difference in the composition of enamel	-
Farhadian (2008)	15 patients	Bifluoride: 12, 6% of calcium fluoride and 6% of sodium fluoride	One application	Significant difference	57/93
Stecksén-Blicks (2004)	273 patients	Fluor Protector 1000ppm	Every 6 weeks	Significant difference	7/26
Vivaldi-Rodrigues (2006)	10 patients	-	Every 3 months	Significant difference	0, 34/0, 51*

*Index of decalcification

Table 6. Examples of in vivo studies about WSL prevention

The secondary prevention, that is the control and treatment of existing WSL after debonding, has gained interest, too. Treatment of post-orthodontic WSL, with a remineralizing cream with casein phosphopeptide-stabilized amorphous calcium phosphate (CPP-ACP) as adjunct to fluoride toothpaste seemed to be beneficial with some mineral and aesthetic improvements compared with fluoride applications [63].

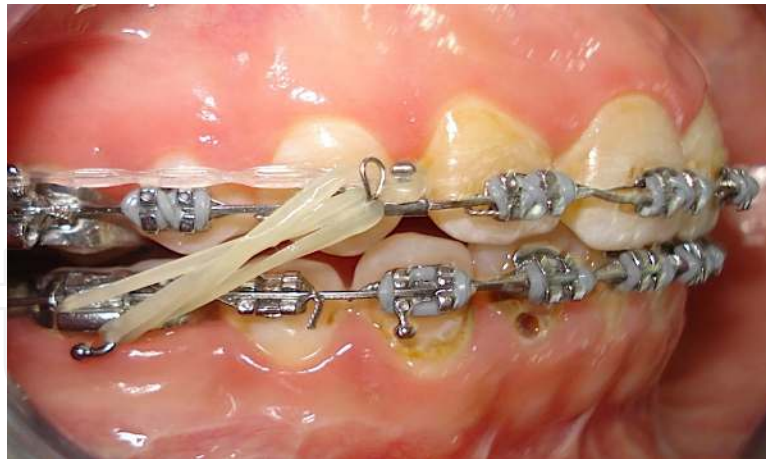


Figure 12. Development of a cavity in cervical zone of the 43 during orthodontic treatment

While the findings of the different studies are equivocal, further research with standardized protocols, is needed before practice guidelines on the fluoride/non-fluoride therapies can be recommended.

8. Conclusion

Even with the advances in material and techniques, demineralization around brackets during orthodontic treatment remains problematic. The literature points to the need for more evidence to clarify the most recent opinions, on which orthodontists can base their clinical practice. Developing a practice and standardized guideline for the prevention and the treatment of enamel demineralizations at the start of, during, and after orthodontic treatment is highly recommended to improve outcomes quality and manage unplanned debondings.

There are a number of products containing fluoride available to clinicians and their patients. Unfortunately, the evidence for the effectiveness of these products is weak. However, to date, using fluoride varnish in high concentration and with regular applications is the most effective way to avoid WSL appearance. This should be implemented in close association with the control of caries risk factors. Indeed, It is still crucial to emphasize that prevention of these lesions is the furthestmost desirable outcome aesthetically and also the least costly for patients.

As for treatment of WSL already installed, the concerns are more complicated. It is expected that the majority of slight or mild the WSL will improve during the retention period if good oral hygiene is maintained. For more advanced cases, total recovery remains unsystematic. The lesions may induce aesthetic consequences and require more invasive approaches. However, current evidence supports the use of topical application of fluoride in low concentration or better the use of CPP-ACP to obtain a reduction in the severity of these lesions.

Author details

Hakima Aghoutan¹, Sana Alami¹, Farid El Quars¹, Samir Diouny² and Farid Bourzgui^{*}

*Address all correspondence to: faridbourzgui@gmail.com

1 Department of Dento-facial Orthopedic, Faculty of Dental Medicine, Hassan II University of Casablanca, Morocco

2 Chouaib Doukkali University, Faculty of Letters & Human Sciences, El Jadida, Morocco

References

- [1] Øgaard B. White spot lesions during orthodontic treatment: mechanisms and fluoride preventive aspects. *Seminars in Orthod.* 2008; 14(3): 183-93.
- [2] Hadler-Olsen S, Sandvik K, El-Agroudi MA et al. The incidence of caries and white spot lesions in orthodontically treated adolescents with a comprehensive caries prophylactic regimen: a prospective study. *Eur J Orth* 2012; 314 : 633-39
- [3] Benson PE. Prevention of Demineralization during orthodontic treatment with fluoride-containing materials or casein phosphopeptide-amorphous calcium phosphate. In Huang GJ, Richmond S, Vig KWL.(eds) *Evidence-Based Orthodontics*. Blackwell Publishing, Ltd 2011 p149-65
- [4] Bishara SE, Ostby AW. White Spot Lesions: Formation, Prevention, and Treatment. *Semin Orthod* 2008;14:174-82
- [5] Chang HS, Walsh LJ, Freer TJ. Enamel demineralization during orthodontic treatment. Aetiology and prevention. *Aust Dent J.* 1997; 42(5): 322-7.
- [6] Jung WS, Kim H, Park SY, et al. Quantitative analysis of changes in salivary mutans streptococci after orthodontic treatment. *Am J Orthod Dentofacial Orthop.* 2014; 145(5): 603-9.
- [7] Lim BS, Lee SJ, Lee JW et al. Quantitative analysis of adhesion of cariogenic streptococci to orthodontic raw materials. *Am J Orthod Dentofacial Orthop.* 2008; 133(6): 882-8.
- [8] Chapman JA, Roberts WE, Eckert GJ et al. Risk factors for incidence and severity of white spot lesions during treatment with fixed orthodontic appliances. *Am J Orthod Dentofacial Orthop.* 2010; 138(2): 188-94.
- [9] Van Palenstein Helderman WH, Matee MI, van der Hoeven JS, et al. Cariogenicity depends more on diet than the prevailing mutans streptococcal species. *Dent Res.* 1996; 75(1): 535-45.

- [10] Kukleva M P, Shetkova D G, Beev V H: Comparative age study of the risk of demineralization during orthodontic treatment with brackets. *Folia Med* 2002; 44: 56-9.
- [11] Øgaard B, Rølla G, Arends J: Orthodontic appliances and enamel demineralization. Part 1. Lesion development. *Am J Orthod Dentofacial Orthop* 1988; 94: 68-73.
- [12] Zachrisson BU, Zachrisson S. Caries incidence and orthodontic treatment with fixed appliances. *Scand J Dent Res* 1971; 79: 183-92.
- [13] Julien KC, Buschang PH, Campbell PM. Prevalence of white spot lesion formation during orthodontic treatment. *Angle Orthod.* 2013; 83: 641-47.
- [14] Lovrov S, Hertrich K, Hirschfelder U. Enamel demineralization during fixed orthodontic treatment—incidence and correlation to various oral-hygiene parameters. *J Orofac Orthop.* 2007; 68: 353-63.
- [15] Tufekci E, Dixon JS, Gunsolley JC, Lindauer SJ. Prevalence of white spot lesions during orthodontic treatment with fixed appliances. *Angle Orthod.* 2011; 2: 206-10.
- [16] Khalaf K. Factors affecting the formation, severity and location of white spot lesions during orthodontic treatment with fixed appliances. *J Oral Maxillofac Res* 2014; 5(1): e4. 10.5037/jomr.2014.5104
- [17] Boersma JG, van der Veen MH, Lagerweij MD, et al. Caries prevalence measured with QLF after treatment; with fixed orthodontic appliances: influencing factors. *Caries Res.* 2005; 39: 41-7.
- [18] Willmot D. White Spot Lesions After Orthodontic Treatment. *Semin Orthod* 2008;14: 209-19.
- [19] Lucchese A, Gherlone E. Prevalence of white-spot lesions before and during orthodontic treatment with fixed appliances. *Eur J Orthod.* 2013; 35(5): 664-8.
- [20] Arneberg P, Giertsen E, Emberland H, et al: Intra-oral variations in total plaque fluoride related to plaque pH. A study in orthodontic patients. *Caries Res* 1997; 31: 451-56.
- [21] Mattousch TJ, van der Veen MH, Zentner A. Caries lesions after orthodontic treatment followed by quantitative light-induced fluorescence: a 2-year follow-up. *Eur J Orthod* 2007; 29: 294-8.
- [22] Shungin D, Olsson AI, Persson M. Orthodontic treatment-related white spot lesions: a 14-year prospective quantitative follow-up, including bonding material assessment. *Am J Orthod Dentofacial Orthop* 2010; 138: 136-7.
- [23] Øgaard B, Larsson E, Henriksson T, et al: Effects of combined application of antimicrobial and a fluoride varnishes in orthodontic patients. *Am J Orthod Dento-facial Orthop* 2001; 120: 28-35.

- [24] Cochrane NJ, Cai F, Huq NL, et al. New approaches to enhanced remineralization of tooth enamel. *J Dent Res* 2010; 89: 1187-97.
- [25] Belli R, Rahiotis C, Schubert EW, Baratieri LN et al. Wear and morphology of infiltrated white spot lesions. *J dentistry* 2011; 39: 376–85
- [26] Øgaard B: Oral microbiological changes, long-term enamel alterations due to decalcification, and caries prophylactic aspects, in Brantley WA, Eliades T, eds: *Orthodontic Materials. Scientific and Clinical Aspects*. Stuttgart, Thieme, 2001, p123-142
- [27] Knösel M, Bojes M, Jung K, et al. Increased susceptibility for white spot lesions by surplus orthodontic etching exceeding bracket base area. *Am J Orthod Dentofacial Orthop* 2012;141:574-82.
- [28] Garcez AS, Suzuki SS, Ribeiro MS, et al. Biofilm retention by 3 methods of ligation on orthodontic brackets: a microbiologic and optical coherence tomography analysis. *Am J Orthod Dentofacial Orthop*. 2011; 140 (4): e193-8.
- [29] Derks A, Katsaros C, Frencken JE, et al. Caries-inhibiting effect of preventive measures during orthodontic treatment with fixed appliances: a systematic review. *Caries Res* 2004; 38: 413-20.
- [30] Farhadian N, Miresmaeili A, Eslami B, at al. Effect of fluoride varnish on enamel demineralization around brackets: an in-vivo study. *Am. J. Orthod. Dentofacial Orthop*. 2008; 133: S95-98.
- [31] Sonesson M, Twetman S, Bondmark L. Effectiveness of high-fluoride toothpaste on enamel demineralization during orthodontic treatment: a multicenter randomized controlled trail. *Eur J Orth*. 2013; Dec 28 doi: 10.1093/ejo/cjt096.
- [32] Walsh T1, Worthington HV, Glenny AM, et al. Fluoride toothpastes of different concentrations for preventing dental caries in children and adolescents. *Cochrane Database Syst Rev*. 2010; 20(1):CD007868. doi: 10.1002/14651858.CD007868.pub2.
- [33] Geiger AM, Gorelick L, Gwinnett AJ, Benson BJ. Reducing white spot lesions in orthodontic populations with fluoride rinsing. *Am J Orthod Dentofacial Orthop* 1992; 101: 403-7
- [34] Kerbusch AE, Kuijpers-Jagtman AM, Mulder J, Sanden WJ. Methods used for prevention of white spot lesion development during orthodontic treatment with fixed appliances. *Acta Odontologica Scandinavica* 2012; 70(6): 564–8.
- [35] Arnold WH, Dorow A, Langenhorst S et al. Effect of fluoride toothpastes on enamel demineralization. *BMC Oral Health* 2006; 6(8): 1-6.
- [36] Benson PE, Parkin N, Dyer F, et al. Fluorides for the prevention of early tooth decay (demineralised white lesions) during fixed brace treatment. *Cochrane Database of Systematic Reviews* 2013 (12). Art. No.: CD003809. DOI: 10.1002/14651858.CD003809.pub3.

- [37] Vivaldi-Rodrigues G, Demito CF, Bowman SJ, et al: The effectiveness of a fluoride varnish in preventing the development of white spot lesions. *World J Orthod.* 2006; 7:138-44.
- [38] Steckslen-Blicks C, Renfors G, Oscarson ND. et al. Caries-preventive effectiveness of a fluoride varnish: a randomized controlled trial in adolescents with fixed orthodontic appliances. *Caries Research* 2007; 41: 455-59
- [39] Buyukyilmaz T, Tangugsorn V, Øgaard B, et al: The effect of titanium tetrafluoride (TiF₄) application around orthodontic brackets. *Am J Orthod Dentofacial Orthop*, 1994; 105: 293-96.
- [40] Hove L, Holme B, Øgaard B, et al: The protective effect of TiF₄, SnF₂ and NaF on erosion of enamel by hydro-chloric acid in vitro measured by white light interferometry. *Caries Res* 2006; 40: 440-43.
- [41] Krishnan V, Krishnan A, Remya R, et al. Development and evaluation of two PVD-coated β-titanium orthodontic archwires for fluoride-induced corrosion protection. *Acta Biomater.* 2011; 7(4): 1913-27
- [42] Brantley WA. Wires used in orthodontic practice. In Miles PG, Rinchuse DJ, Rinchuse DJ (Eds) *Evidence-based clinical orthodontics*. 2012 Quintessence Publishing Co Inc
- [43] Huang SY, Huang JJ, Kang T, et al. Coating NiTi archwires with diamond-like carbon films: reducing fluoride-induced corrosion and improving frictional properties. *J Mater Sci Mater Med.* 2013; 24 (10): 2287-92.
- [44] Geiger AM, Gorelick L, Gwinnett AJ, et al. Reducing white spot lesions in orthodontic populations with fluoride rinsing. *Am J Orthod Dentofacial Orthop* 1992; 101: 403-7.
- [45] Rogers S, Chadwick B, Treasure E. Fluoride-containing orthodontic adhesives and decalcification in patients with fixed appliances: a systematic review. *Am J Orthod Dentofacial Orthop.* 2010; 138(4): 390.e1-8
- [46] Eliades T: Orthodontic materials research and applications: Part 1. Current status and projected future developments in bonding and adhesives. *Am J Orthod Dentofacial Orthop* 2006; 130:445-51
- [47] Hu W, Featherstone JD. Prevention of enamel demineralization: an in-vitro study using light-cured filled sealant. *Am J Orthod Dentofacial Orthop.* 2005; 128(5): 592-600
- [48] Behnan SM, Arruda AO, González-Cabezas C, et al. In-vitro evaluation of various treatments to prevent demineralization next to orthodontic brackets. *Am J Orthod Dentofacial Orthop* 2010; 138: 712.e1-712.e7.
- [49] Korbmacher HM, Huck L, Kahl-Nieke B: Fluoride-releasing adhesive and antimicrobial self-etching primer effects on shear bond strength of orthodontic brackets. *Angle Orthod.* 2006; 76:845-50.

- [50] Pseiner BC, Freudenthaler J, Jonke E, et al. Shear bond strength of fluoride-releasing orthodontic bonding and composite materials. *Eur J Orthod*. 2010; 32(3): 268-73.
- [51] Raji SH, Banimostafae H, Hajizadeh F. Effects of fluoride release from orthodontic bonding materials on nanomechanical properties of the enamel around orthodontic brackets. *Dent Res J*. 2014; 11(1): 67–73.
- [52] Chen H, Liu X, Dai J, et al. Effect of remineralizing agents on white spot lesions after orthodontic treatment: A systematic review. *Am J Orthod Dentofacial Orthop*. 2013; 143(3): 376-82.e3.
- [53] Øgaard B, ten Bosch JJ: Regression of white spot enamel lesions. A new optical method for quantitative longitudinal evaluation in vivo. *Am J Orthod Dentofacial Orthop* 1994; 106 : 238-42.
- [54] Artun J, Thylstrup A. A 3-year clinical and SEM study of surface changes of carious lesions after inactivation. *Am J Orthod Dento-facial Orthop* 1989; 95: 327-33.
- [55] Kalha AS. Lack of reliable evidence of the effectiveness of remineralising agents for the treatment of post orthodontic white spot lesions. *Evid Based Dent*. 2013; 14(3): 76-7.
- [56] Ballard RW, Hagan JL, Phaup AN, et al. Evaluation of 3 commercially available materials for resolution of white spot lesions *Am J Orthod Dentofacial Orthop*. 2013; 143: S78-84.
- [57] Artun J, Thylstrup A. Clinical and scanning electron microscopic study of surface changes of incipient caries lesions after debonding. *Scand J Dent Res* 1986; 94: 193-201.
- [58] Al-Khateeb S, Exterkate RAM, Angmar-Månsson B, et al: Effect of acid-etching on remineralization of enamel white spot lesions. *Acta Odontol Scand* 2000; 58:31-6.
- [59] Gorelick L, Geiger AM, Gwinnett AJ. Incidence of white spot formation after bonding and banding. *Am J Orthod*. 1982; 81: 93-8.
- [60] Bourzgui F, Sebbar M, Hamza M. Risk of caries in orthodontics: descriptive study on 155 patients. *Rev Stomatol Chir Maxillofac*. 2010; 111: 276-79.
- [61] Chaussain C, Opsahl Vital S, Viallon V, et al. Interest in a new test for caries risk in adolescents undergoing orthodontic treatment. *Clin Oral Investig*. 2010; 14: 177–85
- [62] Al Mulla AH, Kharsa SA, Birkhed D. Modified fluoride toothpaste technique reduces caries in orthodontic patients: A longitudinal, randomized clinical trial. *Am J Orthod Dentofac Orthop*. 2010; 138: 285-91
- [63] Bergstrand F, Twetman S. A review on prevention and treatment of post-orthodontic white spot lesions—evidence based methods and emerging technologie. *Open Dent J*. 2011; 5: 158-62.

