

WHY DOES THE PATIENT WITH GRAVES' DISEASE REMAIN EUTHYROID/MILDLY HYPERTHYROID FOLLOWING TOTAL THYROIDECTOMY – THE ROLE OF THYROTROPIN RECEPTOR ANTIBODIES (TRAb) AND VESTIGIAL REMNANTS OF THE THYROGLOSSAL TRACT

Maja Cigrovski-Berković¹, Darko Solter² and Miljenko Solter¹

¹University Department of Endocrinology, Diabetes and Metabolism, ²University Department of ENT, Sestre milosrdnice University Hospital, Zagreb, Croatia

SUMMARY – A young female patient suffering from Graves' disease is presented, who raised some diagnostic and therapeutic dilemmas after being diagnosed with subclinical hyperthyroidism following total thyroidectomy. This 20-year-old female patient, carrier of HLA B8 DR3 genes, was referred to our hospital for total thyroidectomy after developing severe leukopenia on both methimazole and propylthiouracil therapy. A high postoperative titer of thyrotropin receptor antibodies and positive scintigraphy finding of the pyramidal lobe and remnant thyroid tissue in the left thyroid lobe led to the administration of radioiodine. Despite further enlargement of the remnant thyroid tissue on post-radioiodine scintiscanning, the patient is currently euthyroid, with normal thyroid-stimulating hormone levels; however, her long-term prognosis remains uncertain.

Key words: *Graves disease – therapy; Graves disease – prevention and control; Prognosis; Receptors; Thyrotropin – immunology; Antibodies – analysis; Case report*

Introduction

Hyperthyroidism is a clinical syndrome resulting from exposure of tissues to excess levels of circulating thyroid hormones¹. In over 90% of patients it is due to Graves' disease, which can be distinguished from other forms of hyperthyroidism by the presence of diffuse thyroid enlargement, ophthalmopathy, and rarely pretibial myxedema^{2,3}. The hyperthyroidism, in this case immunologically mediated, results from the production of IgG class antibodies directed against the thyrotropin receptor antibodies (TRAb)^{1,4}. In Caucasians, there is an association of Graves' disease with HLA B8, DR3 and DR2

haplotype and the disease usually affects the 30-50 age groups. Women are affected more commonly than men, and as many as 60% of patients have a family predisposition for developing Graves' disease. Specific therapeutic options currently available include antithyroid drugs (methimazole and propylthiouracil), operative procedures (subtotal and total thyroidectomy) and radioactive iodine, depending, among other, on the severity of hyperthyroid episode, recurrence of symptoms, presence and titer of TRAb, patient age and goiter size⁵⁻⁷. We present a case of a young female patient suffering from Graves' disease, who raised considerable diagnostic and therapeutic dilemmas.

Case Report

A 20-year-old female patient, carrier of HLA B8 DR3 genes, was referred to our hospital after developing se-

Correspondence to: *Maja Cigrovski-Berković, MD*, University Department of Endocrinology, Diabetes and Metabolism, Sestre milosrdnice University Hospital, Vinogradska c. 29, HR-10000 Zagreb, Croatia

E-mail: mberkovi@globalnet.hr

Received July 24, 2008, accepted August, 29, 2008

vere leukopenia on both methimazole and propylthiouracil therapy introduced for Graves' disease. Upon admission, she had incipient ophthalmopathy and arthropathy with demineralization of the left femur. Her previous medical history included autoimmune thrombocytopenia, idiopathic leukopenia, and due to polymorph symptomatology (migrating polyarthralgia, erythema) she was followed by the immunologist, being suspected to have antiphospholipid syndrome. Her mother and sister have been treated for vasculitis. Upon achievement of euthyroid state, total thyroidectomy was advised and, to our knowledge, performed. The patient was discharged with levothyroxine 100 µg. On 3-month postoperative follow up, she had suppressed thyroid-stimulating hormone (TSH) level (<0.1) and substitution therapy was gradually discontinued. After a year of continuous monitoring, some symptoms suggestive of hyperthyroidism and a hormonal pattern characteristic of subclinical hyperthyroidism persisted (T3=1.7; T4=100; TSH <0.1). Scintigraphic scanning revealed thyroid tissue remnant in the left thyroid lobe and pyramidal lobe (Fig. 1). The titer of TRAb was significantly elevated (198 IU/L; normal value <9 IU/L). In 2003, the patient received 4 mCi of radioiodine. Following this treatment she was euthyroid (T3=1.7, normal range 1.1-2.8 nmol/L; TSH 0.91, normal range 0.3-4.5 mIU/L) but the remnant thyroid tissue enlarged even further than before the administration of radioiodine (Fig. 2).

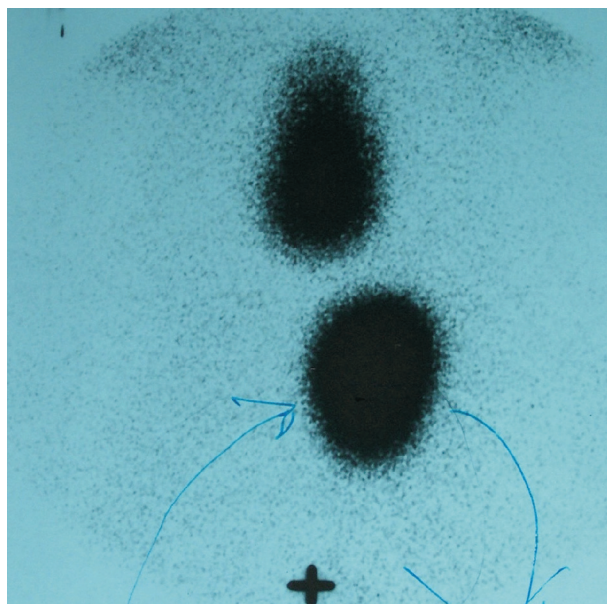


Fig. 1. Postoperative scintiscan.

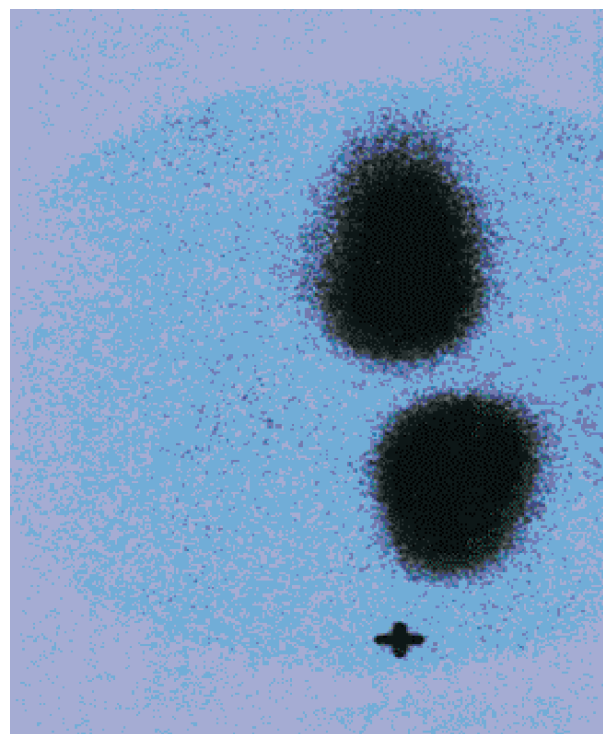


Fig. 2. Post-radioiodine scintiscan.

Discussion

The diagnosis of Graves' disease is quite straightforward when the clinical picture of ophthalmopathy and arthropathy develops in a setting of hyperthyroidism. It is usually based on laboratory findings of elevated T3 and T4 levels and suppressed TSH, while TRAb and thyroid scintiscanning are only rarely part of initial diagnostic algorithm. The present experience suggests that the best treatment of Graves' disease depends on prediction of the natural history of hyperthyroidism in an individual patient at presentation of symptoms. Remission can be achieved either by the course of antithyroid drugs (ATD) or radioiodine. ATD are usually administered for up to 18 months in those patients where a single episode is anticipated. For those likely to relapse, surgery or radioactive iodine is advised^{1,6-10}. The serious adverse effects of ATD include leukopenia and agranulocytosis. They occur rarely, in 0.1%-0.5% of patients, usually within the first 3 months of therapy initiation, but when present, they limit further conservative therapeutic options. Radioiodine therapy is mostly avoided at younger age and in pregnant or lactating women because of the possible teratogenic and carcinogenic effects. It is not recommended in patients with ophthal-

mopathy either because of evidence for worsening the prognosis. These were the reasons why total thyroidectomy, with anticipated permanent hypothyroidism, seemed to be the best therapeutic option for our patient⁶. The need of postoperative scintigraphy and TRAb titer detection was quite unexpected and uncommon; however, it arose in the setting of postoperative hyperthyroidism. The most probable explanation is that the patient must have undergone incomplete rather than the planned total thyroidectomy due to the unidentified and thus left over pyramidal lobe. This, in the context of high TRAb titer (with predominantly expressed stimulating effect) led to reactivation of autoimmune inflammation and hyperplasia of the remnant thyroid tissue. Furthermore, the pyramidal lobe left over seemed to have virtually nullified the anticipated benefit of radioiodine by absorbing most of the radioactive material. Thus, instead of an easy manageable hypothyroidism, the patient is now facing a high likelihood of recurrence of overt hyperthyroidism⁹⁻¹². Although being the best therapeutic option in this context, the administration of radioiodine, in spite of her young age, was also only partly successful¹³⁻¹⁵, since post-iodine scintiscanning showed further enlargement of the thyroid tissue. Although presently both peripheral thyroid hormones and TSH are within the normal range, the final outcome of the disease in this patient remains uncertain^{16,17}. This case suggested the following conclusions: 1) at a young age, total thyroidectomy including accessory and ectopic thyroid tissue should be the preferred treatment, especially having in mind that subtotal surgery leads to recurrence or persistence of the disease in approximately 15% of patients^{6,18}; and 2) in some instances, especially in patients with expected exaggerated immune response measured by TRAb elevations, preoperative ultrasound and scintiscan would be recommended in the preoperative algorithm, so that pyramidal lobe (which is evident in as many as 20% of patients with Graves' disease) and other vestigial remnants of the thyroglossal tract can be included in extensive thyroidectomy¹⁹⁻²¹, because when left behind, in the setting of autoimmunity, they could adversely influence the outcome of operative treatment.

References

1. WEETMAN AP. Etiology, diagnosis and treatment of Graves' disease. *Thyroid Int* 2003;2:3-14.
2. FATOURECHI V, AHMED DD, SCHWARTZ KM. Thyroid acropathy: report of 40 patients treated at a single institution in a 26-year period. *J Clin Endocrinol Metab* 2002;87:5435-41.
3. WALL JR. Graves' disease is a multi-system autoimmune disorder in which extra ocular muscle damage and connective tissue inflammation are variable features. *Thyroid* 2002;12:35-6.
4. TAKASU N, YAMASHIRO K, KOMIYA I, OCHI Y, SATO Y, NAGATA A. Remission of Graves' hyperthyroidism predicted by smooth decreases of thyroid-stimulating antibody and thyrotropin-binding inhibitor immunoglobulin during antithyroid drug treatment. *Thyroid* 2000;10:891-6.
5. BROKKEN LJ, WIERSINGA WM, PRUMMEL MF. Thyrotropin receptor autoantibodies are associated with continued thyrotropin suppression in treated euthyroid Graves' disease patients. *J Clin Endocrinol Metab* 2003;88:4135-8.
6. BARAKATE MS, AGARWAL G, REEVE TS, BARRACLOUGH B, ROBINSON B, DELBRIDGE LW. Total thyroidectomy is now the preferred option for the surgical management of Graves' disease. *A N Z J Surg* 2002;72:321-4.
7. FRANKLYN JA. The management of hyperthyroidism. *N Engl J Med* 1994;330:1731-8.
8. ORGIAZZI J, MADEC AM. Reduction of the risk of relapse after withdrawal of medical therapy for Graves' disease. *Thyroid* 2002;12:849-53.
9. NEDREBO BG, HOLM PI, UHLVING S, SORHEIM JI, SKEIE S, EIDE GE, HUSEBYE ES, LIEN EA, AANDERUD S. Predictors of outcome and comparison of different drug regimens for the prevention of relapse in patients with Graves' disease. *Eur J Endocrinol* 2002;147:583-9.
10. WALLASCHOFSKI H, MIEHLE K, MAYER A, TUSCHY U, HENTSCHEL B, PASCHKE R. Prediction of remission or relapse for Graves' hyperthyroidism by the combined determination of stimulating, blocking and binding TSH-receptor antibodies after the withdrawal of antithyroid drug treatment. *Horm Metab Res* 2002;34:383-8.
11. CHEN CR, PICHURIN P, NAGAYAMA Y, LATROFA F, RAPOPORT B, MCLACHLAN SM. The thyrotropin receptor autoantigen in Graves disease is the culprit as well as the victim. *J Clin Invest* 2003;111:1897-904.
12. HOOGENDOORN EH, Der HEIER M, Van DIJK AP, HERMUS AR. Subclinical hyperthyroidism: to treat or not to treat? *Postgrad Med J* 2004;80:394-8.
13. SYED AA, EVANS C, LUDGATE M, LAZARUS JH. Early changes in thyroid-stimulating antibody activity following radioiodine therapy. *Med Princ Pract* 2003;12:266-8.
14. GOMEZ-ARNAIZ N, ANDIA E, GUMA A, ABOS R, SOLER J, GOMEZ JM. Ultrasonographic thyroid volume as a reliable prognostic index of radioiodine-131 treatment outcome in Graves' disease hyperthyroidism. *Horm Metab Res* 2003;35:492-7.
15. SABRI O, ZIMNY M, SCHRECKENBERGER M, REINARTZ P, NOWAK B, OSTWALD E, SCHAFFER W, BLOCK S, SETANI K, BULL U. Characterization of therapy failures in radioiodine therapy of Graves' disease without simultaneous antithyroid agents. *Nuklearmedizin* 2001;40:1-6.
16. KUBO T, TOKI J, KADO Y, KURIHARA M, MORIWAKE T, KANZAKI S, SEINO Y. Thyroid-stimulating antibody in a

- patient with euthyroid Graves' disease. *Endocr J* 2000;47:197-201.
17. AKUZAWA M, MURAKAMI M, YAMADA M, SATOH T, SHIMIZU H, MORI M. Preserved activation of thyrotropin receptor antibody to stimulate thyroid function despite long-term treatment in euthyroid patients with Graves' disease. *Eur Endocrinol* 1998;138:281-5.
18. WERGA-KJELLMAN P, ZEDENIUS J, TALLSTEDT L, TRAIK F, LUNDELL G, WALLIN G. Surgical treatment of hyperthyroidism: a ten-year experience. *Thyroid* 2001;11:187-92.
19. BAIK SH, CHOI JH, LEE HM. Dual ectopic thyroid. *Eur Arch Otorhinolaryngol* 2002;259:105-7.
20. WEIDER DJ, PARKER W. Lingual thyroid: review, case reports, and therapeutic guidelines. *Ann Otol Rhinol Laryngol* 1977;86:841-8.
21. PALUDETTI G, GALLI J, ALMADORI G, OTTAVIANI F, D'ALATRI L, MAURIZI M. Ectopic thyroid gland. *Acta Otorhinolaryngol Ital* 1991;11:117-33.

Sažetak

ZAŠTO BOLESNICA S GRAVESOVOM BOLEŠĆU OSTAJE EUTIROIDNA/BLAGO HIPERTIROIDNA NAKON TOTALNE TIROIDEKTOMIJE – ULOGA ANTITIJELA NA TIROTROPINSKE RECEPTORE (TRAb) I VESTIGALNIH OSTATAKA TIROGLOSALNOG TRAKTA

M. Cigrovski-Berković, D. Solter i M. Solter

Opisan je slučaj bolesnice operirane zbog hipertireoze na podlozi Gravesove bolesti, u koje se na početno primijenjenu medikamentnu terapiju razvila granulocitopenija. Iako je kod bolesnice bila planirana totalna tireoidektomija, s obzirom na prijeoperacijski neprepoznat lobus piramidalis učinjena je tek djelomična resekcija štitnjače. Poslijeoperacijski se kao posljedica autoimune aktivacije ostatnog tkiva štitnjače antitijelima na tirotropinske receptore (TRAb) razvila hipertireoza, pa je daljnji tijek bolesti još uvijek nesiguran.

Ključne riječi: *Gravesova bolest – terapija; Gravesova bolest – prevencija i kontrola; Prognoza; Receptori; Tirotropin – imunologija; Antitijela – analiza; Prikaz slučaja*