



Contents lists available at ScienceDirect

The Veterinary Journal

journal homepage: www.elsevier.com/locate/tvj

Widespread retinal degenerative disease mutation (*rdAc*) discovered among a large number of popular cat breeds

M. Menotti-Raymond^{a,*}, V.A. David^a, S. Pflueger^b, M.E. Roelke^c, J. Kehler^a, S.J. O'Brien^a, K. Narfström^d

^a Laboratory of Genomic Diversity, National Cancer Institute-Frederick, Frederick, MD 21702, USA

^b Baystate Medical Center, Springfield, MA 01199, USA

^c Laboratory of Genomic Diversity, SAIC-Frederick, Inc., NCI-Frederick, Frederick, MD 21702, USA

^d Department of Veterinary Medicine and Surgery, College of Veterinary Medicine, University of Missouri, Columbia, MO 65211, USA

ARTICLE INFO

Article history:

Accepted 5 August 2009

Available online xxx

Keywords:

Retinal degeneration

Cat breeds

Mutation

CEP290

Photoreceptors

ABSTRACT

The recent discovery of a mutational variant in the *CEP290* gene (*CEP290*: IVS50 + 9T>G), conferring recessive retinal degeneration in Abyssinian and Somali (long-haired Abyssinian) cats (*rdAc*) prompted a survey among 41 cat breeds (846 individuals) to assess the incidence, frequency and clinical consequence of *rdAc*. The *rdAc* allele displayed widespread distribution, observed in 16/43 (37%) breeds, exhibiting a high allele frequency (~33%) in North American and European Siamese populations. Clinical evaluations demonstrated high concordance between *rdAc* pathology and the *CEP290* (IVS50 + 9T>G) homozygous genotype ($P = 1.1E-6$), with clinical disease similar to affected Abyssinians/Somalis. This retinal degeneration has not been reported in breeds other than the Abyssinian/Somali and poses a significant health risk particularly in the Siamese breed group. Alertness of the veterinary community and the present availability of commercial diagnostic testing could synergistically enable breeders to reduce the incidence of *rdAc* blindness in pure-bred cat populations.

Published by Elsevier Ltd.

Introduction

Cat breeds exhibit a high incidence of hereditary disease pathologies (Pontius et al., 2007), as has been seen in other domesticated animal breed populations (Higgins and Nicholas, 2008; Taberlet et al., 2008). Small effective population sizes, the use of popular sires, line breeding and founder effects increase the likelihood of expression of rare pathogenic mutations. Over 280 pathologies with a hereditary component have been reported in the domestic cat.¹ Many conditions are not seen outside of the breed or breed group in which the causative mutation occurred, such as gangliosidosis in the Korat (Baker et al., 2001; Martin et al., 2004; Muldoon et al., 1994) and Type IV glycogen storage enzyme disease in the Norwegian Forest cat (Fyfe and Kurzhals, 1998), possibly due to the constraints that registration rules may place on gene transfer between breeds. Others such as polycystic kidney disease have most likely spread into newer breeds from contributing parental breeds (Persian) (Barthez et al., 2003).

Whilst there have been reports of sporadic retinal pathologies identified in cats (Bistner et al., 1976; Glaze, 2005; Gould and Sargan, 2002; Narfström, 1999, 1983; Rah et al., 2005), hereditary

retinal blindness has not generally been considered a significant health factor in pure-bred cats. With the discovery of an unusually high prevalence (45%) of hereditary rod cone degeneration in the Abyssinian cat approximately 25 years ago in Sweden, it became clear that there was increased risk for hereditary retinal dystrophies causing blindness within some cat breeds (Narfström, 1983, 1985a; Narfström and Nilsson, 1983). Hereditary blindness was observed in a group of American short-haired cats (West-Hyde and Buyukmihci, 1982) and another Abyssinian cat model was subsequently described for retinal blinding disease in the United Kingdom (Barnett and Curtis, 1985; Curtis et al., 1987). More recently, an autosomal recessive form of early onset progressive retinal atrophy has been described in Persian cats (Rah et al., 2005).

The development of critical genetic mapping resources in the cat, including comprehensive genetic maps (Davis et al., 2009; Menotti-Raymond et al., 1999, 2003, 2009; Murphy et al., 2007), the recent 1.9X whole genome sequence of the cat (Pontius et al., 2007; Pontius and O'Brien, 2007) and the generation of a pedigree segregating for *rdAc* (Narfström et al., in press) has enabled the identification of the causal mutation for *rdAc* (Menotti-Raymond et al., 2007b). A single base pair substitution in an intron of the centrosomal protein 290 gene (*CEP290*) (IVS50 + 9T>G) (previously referred to as the *rdAc* allele) results in alternative splicing of the *CEP290* transcript, with subsequent introduction of a premature

* Corresponding author. Tel.: +1 301 846 7486; fax: +1 301 846 6327.

E-mail address: raymond@ncifcrf.gov (M. Menotti-Raymond).

¹ See: <http://omia.angis.org.au>.

stop codon and truncation of the mature protein (Menotti-Raymond et al., 2007b).

Mutations in the homologous human *CEP290* gene are a common cause of human blindness, including approximately 30% of patients with Leber's congenital amaurosis (Hollander et al., 2006). Additionally, mutations in *CEP290* are causative of several rare, severe, early onset syndromic diseases in humans including Joubert's, Senior-Loken, Meckel-Gruber, and Bardet-Biedl syndromes, which cause blindness, mental retardation and kidney failure among other severe clinical signs (Baala et al., 2007; Leitch et al., 2008; Sayer et al., 2006; Valente et al., 2006). None of these additional clinical manifestations are observed in *rdAc* affected cats (Narfström et al., in press).

A recent survey of 21 cat breeds in the USA ($n = 2/\text{breed}$) (Menotti-Raymond et al., 2007b) suggested that the *rdAc* allele was confined to the Abyssinian/Somali (Somali cats are long-haired Abyssinians) and Abyssinian related breeds, including a single *rdAc* allele identified in an Ocicat. This recently generated hybrid breed has had input from both Abyssinian and Siamese cats (Helgren, 1997). Furthermore, a recent genetic survey of Abyssinian and Somali cat populations from the USA, UK, Australia and Scandinavia, identified *rdAc* allele frequencies of 0.07, 0.21, 0.11, 0.20, respectively (Menotti-Raymond et al., 2007b; Narfström et al., in press). In this extended survey the *rdAc* allele genotype was in complete concordance with the presence or absence of retinal atrophy ($P = 3.2E-8$), demonstrating that the *rdAc* genotype is highly predictive of *rdAc* disease progression ($n = 846$).

As the *rdAc* allele has a world-wide distribution in Abyssinian and Somali populations with a significant clinical impact on homozygous affected cats, it became imperative to determine whether the *rdAc* allele is present in additional related breeds. In this report 41 further breeds ($n = 846$ individuals) and 92 outbred (random bred) cats were genotyped at the *rdAc* locus, and 27 individual cats screened for evidence of retinal degeneration.

Surprisingly, the *rdAc* allele was detected in 34% of the cat breeds examined with relatively high frequencies in Siamese and Siamese-related breeds in both North America and Europe. Based on a recent publication on the genetic relatedness of cat breeds (Menotti-Raymond et al., 2007a), we were unable to identify genetic distinctiveness between the Siamese, Colorpoint Shorthair, Oriental Shorthair, Balinese and Javanese breeds, which we will refer to in this study as 'Siamese related breeds' or the 'Siamese breed group'. In addition, the *rdAc* genotype was predictive of the disease phenotype, where all homozygous *rdAc* pure-bred cats that were examined in the study had evidence of retinal degeneration, similar to that observed in Abyssinian and Somali cats. Clearly the *rdAc* mutation has a global distribution in multiple breeds of cats, and this form of heritable retinal degeneration has been previously unrecognized in several popular breeds of cats.

Materials and methods

DNA and tissue samples

DNA samples representing 43 cat breeds and one outbred population were used in the study (Table 1). DNA samples of individuals representing 36 breeds were used from a previous collection (Menotti-Raymond et al., 2005). DNA from five additional breeds was obtained from a population genetic survey (Thai) (see below), the Laboratory of Genomic Diversity DNA resources (Tennessee Rex, Munchkin, Angora) and from a commercial DNA testing laboratory (see below) which included the Peterbald, a breed recently developed with Siamese influence (Fogle, 2001).

DNA from 92 random bred, feral cats was extracted from discarded tissues provided by veterinary hospitals and spay clinics in Frederick and Howard County, Maryland. Additionally, DNA samples ($n = 54$) were obtained from a commercial testing laboratory in Europe LABOKLIN (Bad Kissingen, Germany), including 28 Siamese cats, 1 Balinese, 8 Peterbald, 3 Ocicat, 12 Oriental Shorthair, and 2 Bengal, under the condition of anonymity of the individuals and their owners.

Animals

For cats of recognised breeds, buccal swab samples were obtained, under an approved Animal Care and Use Protocol, from Siamese ($n = 107$), Oriental Shorthair ($n = 40$), Javanese ($n = 4$), Balinese ($n = 11$), and Colorpoint Shorthair ($n = 3$) cats from cat breeders in Maryland, Massachusetts, Pennsylvania, Virginia, Texas and Ohio. Breeders' names were withheld under request for anonymity.

DNA extraction and genotyping of the *rdAc* allele

DNA was extracted from buccal or tissue samples using Qiagen QiAmp DNA Blood Midi and Mini Extraction Kits following the manufacturer's suggested protocols. DNA was quantified using a Hoefer DNA Quant 200 Fluorometer (Amersham BioSciences). A proportion of each sample was diluted to a standard concentration of 2.5 ng/ μL with sterile distilled water (Quality Biological). Genotyping of the *rdAc* causative single nucleotide polymorphism (SNP) (IVS50 + 9T>G) was performed as described by Menotti-Raymond et al. (2007b).

Clinical examinations

Clinical study of *rdAc* has been extensively characterized in the Abyssinian cat (Narfström, 1983, 1985a,b; Narfström et al., 1989, 2001, 1988; Narfström and Nilsson, 1986, 1989). To determine if the *rdAc* genotype correlated with the development of retinal degeneration pathology as observed in the Abyssinian, a subset of individuals ($n = 27$) from 8 months to 18 years of age, representing six specific breeds in the Siamese breed group (Table 2), were clinically evaluated after genotyping. Ophthalmologic examinations were performed in a masked fashion, in that the veterinary ophthalmologist (KN) examined cats without knowledge of their *rdAc* genotype. Pupils were dilated using short acting mydriatics (Tropicamide 1%, Alcon), and fundic examinations were performed through indirect ophthalmoscopy (Welch Allyn Distributors) in all cats included in the study.

Full-field flash electroretinography (ERG) was performed in a 1-year old Siamese with suspected disease (stage 1) according to the ophthalmoscopic examination and normal age-matched cat, both under medetomidine, 150 $\mu\text{g}/\text{kg}$, equivalent to 0.15 mL/kg (Domitor, Pfizer) and ketamine anaesthesia (5 mg/kg IM). A portable ERG unit was used (HMsERG, RetVetCorp.) with an automated protocol for evaluation of rod and cone function (Narfström et al., 2002; Katz et al., 2008).

Results

In a genetic survey of 846 pure-bred and 92 outbred cats, the *rdAc* single nucleotide polymorphism (*CEP290*: IVS50 + 9T>G) previously characterized in the Abyssinian and Somali breeds was detected in 14/41 breeds (34%) (Table 1). Frequencies for the *rdAc* allele in the cat breeds from the US ranged from 0.02 (Cornish Rex) to 0.36 (Balinese) (Table 1), although sample sizes were small for some of the breeds and may not accurately reflect the true frequencies. While the *rdAc* allele was also detected in two carriers out of 92 outbred cats sampled in Maryland, the frequency was extremely low (0.01). Whereas, individuals in the Siamese and Siamese-related breeds (Colorpoint Shorthair, Oriental Shorthair, Balinese, Javanese), which will be referred to in this study as the 'Siamese breed group', exhibited the highest allele frequencies for the *rdAc* mutation ranging from 0.27 to 0.36 (Table 1).

A significant part of our study focused on the Siamese breed group, as initial estimates in 36 individuals had demonstrated elevated *rdAc* allele frequencies (data not shown). To confirm these initial estimates within the Siamese and Siamese-related breeds, additional samples were collected from several independent US breed registries ($n = 187$) (Table 3) and European countries ($n = 52$) (Table 1). Samples obtained from 52 cats from six breeds (Balinese, Bengal, Ocicat, Oriental Shorthair, Peterbald, Siamese) from geographically separated countries, demonstrated presence of the *rdAc* allele in 5/6 breeds with elevated frequencies in the Siamese breed group (Table 1).

Within the US additional samples were obtained from populations of Siamese cats maintained in separate registries (CFA, TICA, TCA) (Table 3). Within the TCA registry, breeders have developed two populations of Siamese cats with different conformational standards. Siamese cats which exhibit a rounder head shape and more robust body (reminiscent of the old-style Siamese conformation) are referred to as classic or 'appleheads', and are shown and

Table 1
Frequencies observed for *rdAc* genotypes in 43 cat breeds and one outbred population.

Cat breed	n ^a	Genotype			Frequency of <i>CEP290</i> risk allele	Anticipated frequency of affected individuals ^c	Potential breed introducing risk allele
		Unrelated ^b	<i>CEP290</i> +/+ (homozygous unaffected)	<i>CEP290</i> +/- (carrier)			
Abyssinian/Somali (USA) ^d	16	16	14	2	0	0.070	0.005
Abyssinian (UK) ^e	34	34	22	10	2	0.206	0.042
Abyssinian (Australia) ^e	57	57	46	10	1	0.105	0.011
Abyssinian/Somali (Scandinavia) ^e	130	130	85	39	6	0.196	0.038
American curl	10	10	9	1	0	0.050	0.003
American wirehair	10	10	8	2	0	0.100	0.010
Bengal	18	18	16	2	0	0.056	0.003
Balinese/Javanese	28	24	10	12	2	0.333	0.111
Colorpoint shorthair	11	11	5	4	2	0.364	0.132
Cornish rex	20	20	19	1	0	0.025	0.001
Munchkin	15	15	14	1	0	0.033	0.001
Ocicat	18	18	15	3	0	0.083	0.007
Oriental shorthair	46	25	11	11	3	0.340	0.116
Siamese	91	49	28	16	5	0.265	0.070
Singapura	6	6	6	0	1	0.167	0.028
Tonkinese	7	7	6	1	0	0.071	0.005
American shorthair	9	9	9	0	0	0.000	0.000
Angora	13	13	13	0	0	0.000	0.000
Birman	10	10	10	0	0	0.000	0.000
Bobtail	13	13	13	0	0	0.000	0.000
Bombay	9	9	9	0	0	0.000	0.000
British shorthair	9	9	9	0	0	0.000	0.000
Burmese	35	35	35	0	0	0.000	0.000
Chartreux	10	10	10	0	0	0.000	0.000
Devon rex	20	20	20	0	0	0.000	0.000
Egyptian Mau	19	19	19	0	0	0.000	0.000
Exotic	18	18	18	0	0	0.000	0.000
Havana	8	8	8	0	0	0.000	0.000
Himalayan	17	17	17	0	0	0.000	0.000
Korat	7	7	7	0	0	0.000	0.000
Maine coon cat	13	13	13	0	0	0.000	0.000
Manx	19	19	19	0	0	0.000	0.000
Norwegian forest cat	19	19	19	0	0	0.000	0.000
Persian	19	19	19	0	0	0.000	0.000
Ragdoll	8	8	8	0	0	0.000	0.000
Russian blue	10	10	10	0	0	0.000	0.000
Scottish fold	20	20	20	0	0	0.000	0.000
Selkirk rex	20	20	20	0	0	0.000	0.000
Siamese ('appleheads')	31	18	18	0	0	0.000	0.000
Sphynx	20	20	20	0	0	0.000	0.000
Tennessee rex	19	19	19	0	0	0.000	0.000
Thai	2	2	2	0	0	0.000	0.000
Turkish angora	14	14	14	0	0	0.000	0.000
Turkish van	9	9	9	0	0	0.000	0.000
Outbred (USA)	92	92	92	2	0	0.011	0.000
Total cats this study (North America)	792						
<i>European samples</i>							
Balinese	1		0	0	1	1.000	1.000
Bengal	2		2	0	0	0.000	0.000
Ocicat	3		1	2	0	0.333	0.111
Oriental shorthair	12		7	4	1	0.250	0.063
Peterbald	8		2	4	2	0.500	0.250
Siamese	28		18	9	1	0.196	0.039
Total European	54						
Total cats	846						

^a Numbers of individuals include cats in this study, only.

^b Total number of unrelated cats used for statistical analyses.

^c Estimates are based on expectations for populations in Hardy Weinberg equilibrium (see text).

^d See Menotti-Raymond et al. (2007).

^e See Narfström et al. (in press).

maintained as a distinct group from those with a 'wedge-shaped' face. A slim body and more extreme 'wedge-shaped' face has become the standard for most contemporary Siamese cat registries, including the CFA and TICA. No *rdAc* alleles were identified in any of the 31 'appleheads' examined. However, the *rdAc* allele was found at high frequencies in all 'wedge-faced' Siamese, confirming earlier estimates, regardless of registry (Table 3).

A subset of cats from the Siamese and Siamese breed group was examined to determine, if the *rdAc* genotype was predictive of the development of retinal degeneration, as in Abyssinian and Somali cats. Ophthalmic evaluations and functional testing using ERG showed similar changes to those which been described for the Abyssinian cat (Hyman et al., 2005; Kang Derwent et al., 2006; Vaegan and Narfström, 2005, 2008), and it was possible to stage

Table 2
Results of clinical ophthalmoscopic exams.

Cat breed ^a	Age (years)	Sex	<i>rdAc</i> genotype ^b	Clinical diagnosis	Stage of disease	Examination performed
Balinese	5	M	Affected	Affected	Stage 2	Ophthalmoscopic
Colorpoint shorthair	11	F	Affected	Affected	Stage 3+	Ophthalmoscopic
Oriental shorthair	3	F	Affected	Affected	Stage 3+	Ophthalmoscopic
Oriental shorthair	1	M	Affected	Affected	Stage 2	Ophthalmoscopic
Siamese	3.5	F	Affected	Affected	Stage 2	Ophthalmoscopic
Siamese	1.5	M (N)	Affected	Affected	Stage 1	Ophthalmoscopic, ERG
Siamese	8	F	Affected	Affected	Stage 4	Ophthalmoscopic
Oriental shorthair	8 months	F	Carrier	Unaffected		
Oriental shorthair	2	F	Carrier	Unaffected		
Oriental shorthair	2	F	Unaffected	Unaffected		
Oriental shorthair	10.5	F	Carrier	Unaffected		
Oriental shorthair	3	F	Carrier	Unaffected		
Oriental shorthair	1	F	Carrier	Unaffected		
Oriental shorthair	6.5	M	Carrier	Unaffected		
Oriental shorthair	4	F	Carrier	Unaffected		
Oriental shorthair	1	M	Carrier	Unaffected		
Siamese	18	F	Carrier	Unaffected		
Siamese	1.5	F	Carrier	Unaffected		
Siamese (A)	3.5	F	Unaffected	Unaffected		
Siamese (A)	5	F	Unaffected	Unaffected		
Siamese (classic wedge)	9	F (S)	Unaffected	Unaffected		
Siamese (wedge:traditional)	18	M (N)	Unaffected	Unaffected		
Siamese	8	M (N)	Carrier	Unaffected		
Siamese	5.5	M (N)	Unaffected	Unaffected		
Siamese	13	M (N)	Unaffected	Unaffected		
Siamese	6	M	Unaffected	Unaffected		
Thai ^c	1	M	Unaffected	Unaffected		Ophthalmoscopic, ERG

^a (A) refers to the rounder head style Siamese known as the 'applehead' – see text in results for detailed description; cats not so designated are wedge or modified wedge style head.

^b Affected: homozygous for the *rdAc* defining SNP, *CEP290* –/–; Carrier: *CEP290* +/-; Unaffected: *CEP290* +/+.

^c The Thai breed is a recently recognized breed of the International Cat Association, representing recent imports from Thailand which exhibit features of the rounder-headed old-style Siamese.

Table 3
Frequency of *rdAc* genotypes in the Siamese breed group in different cat registries.

Cat breed (registry)	n	Unrelated	Genotype			Frequency of <i>CEP290</i> allele	Anticipated frequency of affected cats ^e	P-value
			<i>CEP290</i> +/+ (homozygous unaffected)	<i>CEP290</i> +/- (carrier)	<i>CEP290</i> –/– (affected)			
Siamese (CFA, TICA, TCA) ^{ab}	71	49	28	16	5	0.265	0.070	0.791
Siamese (CFA)	25	25	11	11	3	0.340	0.116	0.734
Siamese (TICA)	25	17	14	2	1	0.118	0.014	0.906
Siamese: TCA (classic:wedge-faced) ^d	21	7	3	3	1	0.357	0.128	0.721
Siamese: TCA ('applehead')	31	18	18	0	0	0.000	0.000	
Oriental shorthair	46	25	11	11	3	0.340	0.116	0.734
Balinese/Javanese	28	24	10	12	2	0.333	0.111	0.739
Colorpoint shorthair	11	11	5	4	2	0.364	0.132	0.716
Total	187							

^a CFA: Cat Fancy Association; TICA: The International Cat Association; TCA: The Traditional Cat Association.

^b Numbers do not include 'applehead' cats.

^c Frequency is based on expectations of populations in Hardy Weinberg equilibrium.

^d The TCA 'classic' Siamese has a less severe wedge-shaped face and more robust body than the TICA, CFA Siamese.

the disease in these cats according to criteria established in these earlier studies (Narfström, 1985a,b) (Table 2). The age of onset and developmental progression of *rdAc* within these additional cat breeds appears to be similar to the slowly progressive retinal degeneration previously described in *rdAc* Abyssinians, in which affected kittens may have reduced retinal function by 8 months of age with early funduscopic changes detectable at 1–2 years and visual impairment by 5–6 years of age.

Seven individual cats homozygous for the *rdAc* allele, including three Siamese, one Balinese, one Colorpoint Shorthair and two Oriental Shorthair cats, were found to have clinical signs of *rdAc* disease (Table 2). Fig. 1 demonstrates typical funduscopic changes in an 8-year old Siamese cat. ERG recordings resulting from white light stimulation using 10 cd/s/m² in the dark adapted state (Fig. 2) performed in a 1-year old Siamese with stage 1 disease

showed a reduced a-wave in comparison to an age-matched normal cat, while the b-wave in the affected animal was less reduced (43% reduction for the a-wave and 33% for the b-wave, respectively). No signs of retinal degeneration were detected in the 20 remaining cats that were either carriers of the *rdAc* allele or homozygous for the unaffected (wildtype) allele. Complete concordance between *rdAc* genotype and *rdAc* disease status was observed in all 27 individuals examined representing six breeds ($P = 1.1E-6$) (Table 2).

Discussion

The mutational variant in the *CEP290* gene (*CEP290*: IVS50 + 9T>G or *rdAc*) originally identified as the cause of heritable retinal degeneration in Abyssinian and Somali cats has a previously

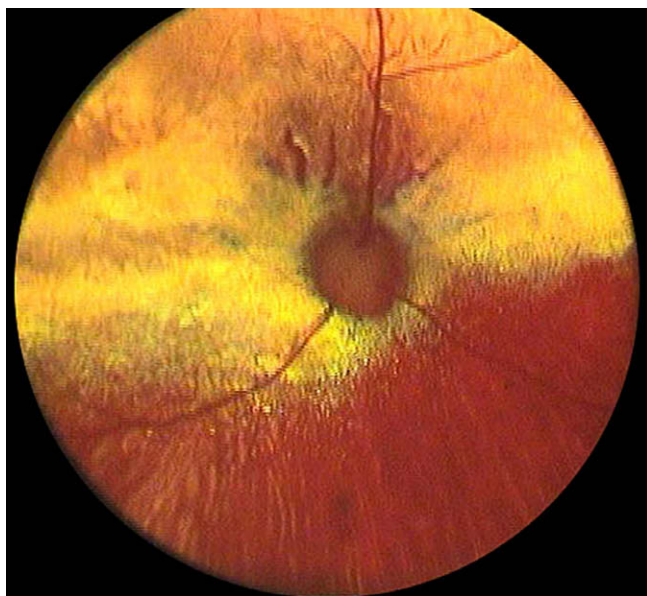


Fig. 1. Fundus photograph of an 8-year-old Siamese cat homozygous for the *rdAc* mutation in an advanced stage of retinal degeneration. Note the generalized retinal color changes in this submelanotic fundus. There is greyish discoloration horizontally along the visual streak area, hyper-reflectivity in the central fundus and also in the mid-peripheral parts and a generalized vascular attenuation. Courtesy Dr. David A. Wilkie.

unrecognised world-wide distribution in additional cat breeds. In this present study the *rdAc* allele was detected in 14/41 breeds (34%) sampled, with a relatively high frequency found in Siamese and Siamese-related breeds (Table 1). The incidence of *rdAc* affected individuals in outbred populations was negligible, as would be expected for a recessively inherited pathology, with two *rdAc* allele carrier individuals detected from farms in adjacent counties of rural Maryland. The *rdAc* allele was also detected at high frequency in cats from the Siamese breed group residing in Europe, confirming that this mutation is present in geographically separated populations.

Most importantly, all 26 individual cats within the Siamese breed group that were directly examined exhibited complete concordance of *rdAc* genotype with affection status ($P = 1.1E-6$), demonstrating that *rdAc* genotype is an excellent predictor of a cat's *rdAc* affection status. Within this small subset of affected Siamese breed group cats, progression of *rdAc* proceeded in an age-dependent manner, similar to that observed in Abyssinian cats (Table 2). Additional clinical studies will be necessary to confirm these observations in other breeds unrelated to Abyssinians or Siamese in which the *rdAc* allele was detected.

Although sample sizes were small, the *rdAc* allele frequency may be as high as 27–36% in the wedge-faced Siamese breed group of cats from North America (Table 1). If these allele frequencies are confirmed by increased sampling, 7–13% of the individuals in this breed group could be affected with *rdAc*, and would be expected to be severely visually impaired by middle age, at approximately 5–6 years of age. This estimate is based on principals of population genetic theory, specifically the Hardy–Weinberg equilibrium (HWE), which posits that alleles in a population associate randomly unless acted upon by selection (Hartl and Clark, 2006). Certain assumptions about gene flow, genetic drift and non-random mating in populations in the HWE may not apply in populations maintained by the Cat Fancy. However, the *rdAc* polymorphism conformed to HWE within and among each of five Siamese-related breeds ($P > 0.1$) (Table 3).

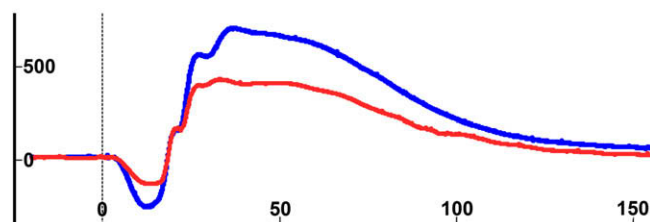


Fig. 2. ERG tracings from an affected 1-year-old Siamese cat (red) in stage I (stage of suspected disease) and from an age-matched normal cat (blue) showing responses using scotopic high intensity white light stimulation (10 cd s/m^2) and the HMsERG under similar recording conditions for both cats. Note the severely reduced a-wave and the less reduced b-wave in the affected individual in comparison to the normal cat. Amplitude calibration in microvolts and implicit time calibration in milliseconds are shown on the ordinate and on the abscissa, respectively. See also Vaegan and Narfström (2005, 2008).

Of interest was the absence of the *rdAc* allele in our sample set of 'applehead' Siamese which is highly suggestive that these individuals represent a separate gene pool from the wedge-faced Siamese. There is little motivation for breeders to cross between the two widely different phenotypes, resulting in relative isolation. Thus it should not be surprising that there is a significant difference in *rdAc* allele frequency among different registries (see Table 3). The high *rdAc* allele frequency in the wedge-faced individuals could result from a founder effect within the Siamese, which are bred for showing. Additionally, the *rdAc* risk allele could be linked to a gene involved in the distinctive wedge-shaped face phenotype. *RdAc* is not observed in other cat breeds with the distinctive color points of the Siamese (i.e., Birman, Himalayan, Ragdoll), though this linkage was not expected as the gene/gene variants responsible for 'colorpoint' and *rdAc* phenotypes, *tyrosinase* and *CEP290*, respectively, are located on different chromosomes (D1 and B4) (Lyons et al., 2005; Schmidt-Küntzel et al., 2005).

We demonstrate a single SNP in the *CEP290* gene that exhibits high predictability for *rdAc* affection status in multiple breeds. Additionally, we have observed a single DNA haplotype over an approximate 500 kilobase region 5' and 3' of the *CEP290* gene in three breeds (Abyssinian, Siamese, Oriental Shorthair) affected with *rdAc* (data not shown). These data support the hypothesis that the mutation causative of *rdAc* occurred only once, which raises the question of how *rdAc* become so widespread in cat breeds.

The high frequency of *rdAc*, first reported in Abyssinian populations in Sweden (45%) (Narfström, 1983), and the present high incidence in the Siamese breed group, suggest that the *rdAc* mutation originated in either the Abyssinian or Siamese breed group. Based on breeding practice within the Cat Fancy and allele frequency comparisons with other cat populations, it appears most likely that the Abyssinian was the point of origin for introduction into the Cat Fancy. The Abyssinian has anecdotally experienced little genetic input from other breeds, but has itself had input in the creation of several of the modern breeds (Lipinski et al., 2008). Although it cannot be proven, the presence of the allele in the Siamese most likely reflects outcrosses to the Abyssinian sometime after World War II, with selection bias for the more extreme phenotype contributing to the high frequency of the *rdAc* allele in some populations within the Siamese breed group. At the end of WWII, cat breeds in Europe were practically decimated. The long-legged Abyssinian would have been an attractive candidate to 'contribute' to the Siamese breed gene pool.

The absence of the allele in the applehead population study suggests introduction of the *rdAc* allele after the phenotypic split within the Siamese population and argues against the original imports from Siam (now Thailand) as the source for *rdAc* in the Siamese

breed group. We have not found the mutation in other established breeds tracing their origin to Southeast Asia (including the Korat and a large sampling of Burmese), nor in more recent imports from Thailand (Thai) (Table 1), further argument in favor of a more recent introduction into the Siamese.

The majority of modern cat breeds have been developed within the last 100 years, many with genetic input from the Siamese, and some from the Abyssinian (Fogle, 2001; Helgren, 1997). Recently we conducted a study of the relatedness of 38 cat breeds (Menotti-Raymond et al., 2007a). Members of the Siamese breed group exhibited a common genetic pool for markers in the study, facilitating transfer of *rdAc* across these breeds. The majority of the additional *rdAc* affected breeds have had 'input' genetically at some point in the recent past from either the Siamese or Abyssinian breeds, as noted in Table 1 (Fogle, 2001; Helgren, 1997). Founder effects or the use of popular sires in the small effective population sizes of cat breeds can have dramatic impacts on allele frequencies in a relatively short period of time. Our sample numbers are small in some breeds. With a larger and wider sampling, *rdAc* may be identified in other breeds. Additionally, a larger sampling in affected breeds is needed in order to get a more accurate estimate of *rdAc* allele frequency, and perhaps to identify 'lines' that are especially at risk for *rdAc*.

The Siamese cat is one of the most popular breeds. Sporadic reports of blindness in Siamese cats have been made in the veterinary literature (Barnett, 1965; Carlile, 1981; Giuliano and van der Woerd, 1999), but the condition has not been clinically evaluated nor has the magnitude of the problem, as suggested by the present study, been appreciated. Our data suggests that *rdAc* represents a significant problem in the Siamese breed group and a condition that veterinarians should be alert to in a wide range of pure-bred cats.

The fact that *rdAc* has gone undetected across a wide spectrum of cat breeds and appears with a relatively high frequency in the Siamese breed group of cats, is testament to the cats' phenomenal ability to adapt to visual impairment. Pure-bred cats are often maintained in a closed environment of the home and not allowed outside. Given the slowly progressive nature of the disease, generally over several years, affected cats learn to adapt to their decreased visual function. It has been shown in previous studies that the clinical expression of the disease (i.e., visual impairment or blindness) is difficult for cat owners to recognise, since indoor cats can manoeuvre in known surroundings, using their other well developed senses (Narfström et al., in press). In addition, pupillary light reflexes (PLRs), if tested with conventional instrumentation (such as a penlight or a Finhoff transilluminator) appear reactive in affected cats until late in the disease process. However, recent studies have shown that using white and chromatic light stimulation under controlled conditions, and video monitoring, it is possible to observe subtle changes in the PLRs of affected cats already in the early stage of disease (S. Thompson et al., unpublished data).

With a concerted effort between veterinarians and breeders to diagnose and test for *rdAc* induced retinal degeneration, this condition can be reduced in pure-bred cat populations. In the early 1980s *rdAc* had an extremely high incidence of approximately ~45% in the Swedish Abyssinian population. The current incidence of individuals affected with *rdAc* has decreased to approximately 4% through a concerted effort among breeders reporting carrier individuals (Narfström et al., in press). Two commercial animal testing laboratories provide genotyping for the *rdAc* causative SNP. As *rdAc* is a recessive condition, testing is recommended in the breeding population, particularly in the Siamese breed group. Cooperation and alertness on the part of the cat breeder and veterinarian community could work to reduce significantly the incidence of *rdAc* in cat breed populations.

Conclusions

These results demonstrate that the mutational variant (*CEP290*: IVS50 + 9T>G), causative of *rdAc*, so far unreported in breeds other than the Abyssinian/Somali, displays widespread distribution among cat breeds and exhibits a high allele frequency (~33%) in both North American and European Siamese cat populations. Clinical evaluations demonstrate high concordance between *rdAc* pathology and the presence of a homozygous genotype for the *rdAc* risk allele. This retinal degeneration poses a significant health risk particularly in the Siamese breed group. Alertness of the veterinary community and the present availability of commercial diagnostic testing could synergistically enable breeders to reduce the incidence of *rdAc* blindness in pure-bred cat populations.

Conflict of interest statement

None of the authors of this paper has a financial or personal relationship with other people or organizations that could inappropriately influence or bias the content of the paper.

Acknowledgements

We wish to thank all of the cat breeders who donated buccal swab samples for this study. Names have been withheld under the desire for anonymity. We thank Dr. David Wilkie for the photograph used in Fig. 1. We additionally thank LABOKLIN for their contribution of 54 pure-bred cat DNA samples. We also wish to thank Donald Crouser DVM of the Boston Road Animal Hospital, Springfield, MA, USA for the contribution of his time facilitating ERG procedures.

This project has been funded in whole or in part with federal funds from the National Cancer Institute, National Institutes of Health, under contract N01-CO-12400. The content of this publication does not necessarily reflect the views or policies of the Department of Health and Human Services, nor does mention of trade names, commercial products, or organizations imply endorsement by the US Government.

References

- Baala, L., Romano, S., Khaddour, R., Saunier, S., Smith, U.M., Audollent, S., Ozilou, C., Faivre, L., Laurent, N., Foliguet, B., Munnich, A., Lyonnet, S., Salomon, R., Encha-Razavi, F., Gubler, M.C., Boddaert, N., de Lonlay, P., Johnson, C.A., Vekemans, M., Antignac, C., Attie-Bitach, T., 2007. The Meckel–Gruber syndrome gene, *MKS3*, is mutated in Joubert syndrome. *American Journal of Human Genetics* 80, 186–194.
- Baker, H., Smith, B.F., Martin, D.R., Foureman, P., 2001. Molecular diagnosis of gangliosidosis: a model of inherited diseases in pure breeds. In: August, J.R. (Ed.), *Consultations in Feline Internal Medicine*, vol. 4. W.B. Saunders Company, Philadelphia, pp. 615–620.
- Barnett, K.C., 1965. Retinal atrophy. *Veterinary Record* 77, 1543–1560.
- Barnett, K.C., Curtis, R., 1985. Autosomal dominant progressive retinal atrophy in Abyssinian cats. *Journal of Heredity* 76, 168–170.
- Barthez, P.Y., Rivier, P., Begon, D., 2003. Prevalence of polycystic kidney disease in Persian and Persian related cats in France. *Journal of Feline Medicine and Surgery* 5, 345–347.
- Bistner, S.I., Aguirre, G., Shively, J.N., 1976. Hereditary corneal dystrophy in the Manx cat: a preliminary report. *Investigative Ophthalmology* 15, 15–26.
- Carlile, J.L., 1981. Feline retinal atrophy. *Veterinary Record* 108, 311.
- Curtis, R., Barnett, K.C., Leon, A., 1987. An early-onset retinal dystrophy with dominant inheritance in the Abyssinian cat. *Clinical and pathological findings. Investigative Ophthalmology and Visual Science* 28, 131–139.
- Davis, B.W., Raudsepp, T., Pearks Wilkerson, A.J., Agarwala, R., Schäffer, A.A., Houck, M., Chowdhury, B.P., Murphy, W.J., 2009. A high-resolution cat radiation hybrid and integrated FISH mapping resource for phylogenomic studies across Felidae. *Genomics* 93, 299–304.
- Fogle, B., 2001. *The new encyclopedia of the cat*. DK Publishing, Inc., New York, NY.
- Fyfe, J.C., Kurzhals, R.L., 1998. Glycogen Storage Disease Type IV in Norwegian Forest Cats: Molecular Detection of Carriers. In: *First International Feline Genetic Disease Conference*, University of Pennsylvania.

- Giuliano, E.A., van der Woerd, A., 1999. Feline retinal degeneration: clinical experience and new findings (1994–1997). *Journal of the American Animal Hospital Association* 35, 511–514.
- Glaze, M.B., 2005. Congenital and hereditary ocular abnormalities in cats. *Clinical Techniques in Small Animal Practice* 20, 74–82.
- Gould, D.J., Sargan, D.R., 2002. Autosomal dominant retinal dystrophy (*Rdy*) in Abyssinian cats: exclusion of *PDE6G* and *ROM1* and likely exclusion of *Rhodopsin* as candidate genes. *Animal Genetics* 33, 436–440.
- Hartl, D.L., Clark, A.G., 2006. *Principles of Population Genetics*, fourth ed. Sinauer Associates Inc., Sunderland, MA.
- Helgren, J.A., 1997. *Barron's encyclopedia of cat breeds: a complete guide to the domestic cats of North America*. Barron's Educational Series, Hauppauge, NY.
- Higgins, A.J., Nicholas, F.W., 2008. The breeding of pedigree dogs: time for strong leadership. *The Veterinary Journal* 178, 157–158.
- Hollander, A.I.D., Koeneke, R.K., Yzer, S., Lopez, I., Arends, M.L., Voeselek, K.E.J., Zonneveld, M.N., Strom, T.M., Meitinger, T., Brunner, H.G., Hoyng, C.B., Born, L.I.V.d., Rohrschneider, K., Cremers, F.P.M., 2006. Mutations in the *CEP290* (*NPHP6*) gene are a frequent cause of Leber congenital amaurosis. *American Journal of Human Genetics* 79, 556–561.
- Hyman, J.A., Vaegan, L., Narfström, K.L., 2005. Electrophysiologic differentiation of homozygous and heterozygous Abyssinian-crossbred cats with late-onset hereditary retinal degeneration. *American Journal of Veterinary Research* 66, 1914–1921.
- Kang Derwent, J.J., Padnick-Silver, L., McRipley, M., Giuliano, E., Linsenmeier, R.A., Narfström, K., 2006. The electroretinogram components in Abyssinian cats with hereditary retinal degeneration. *Investigative Ophthalmology and Visual Science* 47, 3673–3682.
- Katz, M.L., Coates, J.R., Cooper, J.J., O'Brien, D.P., Jeong, M., Narfström, K., 2008. Retinal pathology in a canine model of late infantile neuronal ceroid lipofuscinosis. *Investigative Ophthalmology and Visual Science* 49, 2686–2695.
- Leitch, C.C., Zaghoul, N.A., Davis, E.E., Stoetzel, C., Diaz-Font, A., Rix, S., Alfadhel, M., Lewis, R.A., Eyaid, W., Banin, E., Dollfus, H., Beales, P.L., Badano, J.L., Katsanis, N., 2008. Hypomorphic mutations in syndromic encephalocoele genes are associated with Bardet–Biedl syndrome. *Nature Genetics* 40, 443–448.
- Lipinski, M.J., Froenicke, L., Baysac, K.C., Billings, N.C., Leutenegger, C.M., Levy, A.M., Longeri, M., Niini, T., Ozpinar, H., Slater, M.R., Pedersen, N.C., Lyons, L.A., 2008. The ascent of cat breeds: genetic evaluations of breeds and worldwide random-bred populations. *Genomics* 91, 12–21.
- Lyons, L.A., Imes, D.L., Rah, H.C., Grahn, R.A., 2005. Tyrosinase mutations associated with Siamese and Burmese patterns in the domestic cat (*Felis catus*). *Animal Genetics* 36, 119–126.
- Martin, D.R., Krum, B.K., Varadarajan, G.S., Hathcock, T.L., Smith, B.F., Baker, H.J., 2004. An inversion of 25 base pairs causes feline GM2 gangliosidosis variant. *Experimental Neurology* 187, 30–37.
- Menotti-Raymond, M., David, V.A., Lyons, L.A., Schäffer, A.A., Tomlin, J.F., Hutton, M.K., O'Brien, S.J., 1999. A genetic linkage map of microsatellites in the domestic cat (*Felis catus*). *Genomics* 57, 9–23.
- Menotti-Raymond, M., David, V.A., Pflueger, S.M., Lindblad-Toh, K., Wade, C.M., O'Brien, S.J., Johnson, W.E., 2007a. Patterns of molecular genetic variation among cat breeds. *Genomics* 91, 1–11.
- Menotti-Raymond, M., David, V.A., Roelke, M.E., Chen, Z.Q., Menotti, K.A., Sun, S., Schäffer, A.A., Tomlin, J.F., Agarwala, R., O'Brien, S.J., Murphy, W.J., 2003. Second-generation integrated genetic linkage/radiation hybrid maps of the domestic cat (*Felis catus*). *Journal of Heredity* 94, 95–106.
- Menotti-Raymond, M., David, V.A., Schäffer, A.A., Stephens, R., Wells, D., Kumar-Singh, R., O'Brien, S.J., Narfström, K., 2007b. Mutation in *CEP290* discovered for cat model of human retinal degeneration. *Journal of Heredity* 98, 211–220.
- Menotti-Raymond, M., David, V.A., Schäffer, A.A., Tomlin, J.F., Eizirik, E., Phillip, C., Wells, D., Pontius, J.U., Hannah, S.S., O'Brien, S.J., 2009. An autosomal genetic linkage map of the domestic cat, *Felis silvestris catus*. *Genomics* 93, 305–313.
- Menotti-Raymond, M.A., David, V.A., Wachter, L.L., Butler, J.M., O'Brien, S.J., 2005. An STR forensic typing system for genetic individualization of domestic cat (*Felis catus*) samples. *Journal of Forensic Sciences* 50, 1061–1070.
- Muldoon, L.L., Neuwelt, E.A., Pagel, M.A., Weiss, D.L., 1994. Characterization of the molecular defect in a feline model for type II GM2-gangliosidosis (Sandhoff disease). *American Journal of Pathology* 144, 1109–1118.
- Murphy, W.J., Davis, B., David, V.A., Agarwala, R., Schäffer, A.A., Pearks-Wilkerson, A.J., Neelam, B., O'Brien, S.J., Menotti-Raymond, M., 2007. A 1.5-Mb-resolution radiation hybrid map of the cat genome and comparative analysis with the canine and human genomes. *Genomics* 89, 189–196.
- Narfström, K., 1999. Hereditary and congenital ocular disease in the cat. *Journal of Feline Medicine and Surgery* 1, 135–141.
- Narfström, K., 1983. Hereditary progressive retinal atrophy in the Abyssinian cat. *Journal of Heredity* 74, 273–276.
- Narfström, K., 1985a. Progressive retinal atrophy in the Abyssinian cat. Clinical characteristics. *Investigative Ophthalmology and Visual Science* 26, 193–200.
- Narfström, K., 1985b. Retinal degeneration in a strain of Abyssinian cats: a hereditary, clinical, electrophysiological and morphological study, Vol. No. 208. Linköping University Medical Dissertations, Linköping.
- Narfström, K., Arden, G.B., Nilsson, S.E., 1989. Retinal sensitivity in hereditary retinal degeneration in Abyssinian cats: electrophysiological similarities between man and cat. *British Journal of Ophthalmology* 73, 516–521.
- Narfström, K., David, V., Jarret, O., Beatty, J.A., Barrs, V.R., Wilkie, A.L., O'Brien, S.J., Menotti-Raymond, M., in press. Retinal degeneration in the Abyssinian cat (*rdAc*): correlation between genotype and phenotype and *rdAc* allele frequency in two continents. *Veterinary Ophthalmology*.
- Narfström, K., Ehinger, B., Bruun, A., 2001. Immunohistochemical studies of cone photoreceptors and cells of the inner retina in feline rod-cone degeneration. *Veterinary Ophthalmology* 4, 141–145.
- Narfström, K., Ekestén, B., Rosolen, S.G., Spiess, B.M., Percicot, C.L., Ofri, R., 2002. Guidelines for clinical electroretinography in the dog. *Documenta Ophthalmologica* 105, 83–92.
- Narfström, K., Nilsson, S.E., 1986. Progressive retinal atrophy in the Abyssinian cat. Electron microscopy. *Investigative Ophthalmology and Visual Science* 27, 1569–1576.
- Narfström, K., Nilsson, S.E., 1989. Morphological findings during retinal development and maturation in hereditary rod-cone degeneration in Abyssinian cats. *Experimental Eye Research* 49, 611–628.
- Narfström, K., Wilen, M., Andersson, B.E., 1988. Hereditary retinal degeneration in the Abyssinian cat: developmental studies using clinical electroretinography. *Documenta Ophthalmologica* 69, 111–118.
- Narfström, L.K., Nilsson, S.E., 1983. Progressive retinal atrophy in the Abyssinian cat: an update. *Veterinary Record* 112, 525–526.
- Pontius, J.U., Mullikin, J.C., Smith, D.R., Team, A.S., Lindblad-Toh, K., Gnerre, S., Clamp, M., Chang, J., Stephens, R., Neelam, B., Volfvsky, N., Schäffer, A.A., Agarwala, R., Narfström, K., Murphy, W., Giger, U., Roca, A.L., Antunes, A., Menotti-Raymond, M., Yuhki, N., Pecon-Slatery, J., Johnson, W.E., Bourque, G., Tesler, G., O'Brien, S.J., 2007. Initial sequence and comparative analysis of the cat genome. *Genome Research* 17, 1675–1689.
- Pontius, J.U., O'Brien, S.J., 2007. Genome Annotation Resource Fields – GARFIELD: A Genome Browser for *Felis catus*. *Journal of Heredity* 98, 386–389.
- Rah, H., Maggs, D.J., Blankenship, T.N., Narfström, K., Lyons, L.A., 2005. Early-onset, autosomal recessive, progressive retinal atrophy in Persian cats. *Investigative Ophthalmology and Visual Science* 46, 1742–1747.
- Sayer, J.A., Otto, E.A., O'Toole, J.F., Nurnberg, G., Kennedy, M.A., Becker, C., Hennies, H.C., Helou, J., Attanasio, M., Fausett, B.V., Utsch, B., Khanna, H., Liu, Y., Drummond, I., Kawakami, I., Kusakabe, T., Tsuda, M., Ma, L., Lee, H., Larson, R.G., Allen, S.J., Wilkinson, C.J., Nigg, E.A., Shou, C., Lillo, C., Williams, D.S., Hoppe, B., Kemper, M.J., Neuhaus, T., Parisi, M.A., Glass, I.A., Petry, M., Kispert, A., Gloy, J., Ganner, A., Walz, G., Zhu, X., Goldman, D., Nurnberg, P., Swaroop, A., Leroux, M.R., Hildebrandt, F., 2006. The centrosomal protein nephrocystin-6 is mutated in Joubert syndrome and activates transcription factor ATF4. *Nature Genetics* 38, 674–681.
- Schmidt-Küntzel, A., Eizirik, E., O'Brien, S.J., Menotti-Raymond, M., 2005. *Tyrosinase* and *tyrosinase related protein 1* alleles specify domestic cat coat color phenotypes of the *albino* and *brown* loci. *Journal of Heredity* 96, 289–301.
- Taberlet, P., Valentini, A., Rezaei, H.R., Naderi, S., Pompanon, F., Negrini, R., Ajmone-Marsan, P., 2008. Are cattle, sheep, and goats endangered species? *Molecular Ecology* 17, 275–284.
- Vaegan, Narfström, K., 2008. Electroretinographic diagnosis of feline hereditary rod cone degeneration is most efficient when amax to scotopic lmax is the only measure used. *Documenta Ophthalmologica* 117, 1–12.
- Vaegan, Narfström, K., 2005. A(max) is the best a-wave measure for classifying Abyssinian cat rod/cone dystrophy. *Documenta Ophthalmologica* 111, 33–38.
- Valente, E.M., Silhavy, J.L., Brancati, F., Barrano, G., Krishnaswami, S.R., Castori, M., Lancaster, M.A., Boltshauser, E., Boccone, L., Al-Gazali, L., Fazzi, E., Signorini, S., Louie, C.M., Bellacchio, E., Related Disorders Study Group, I.J., Bertini, E., Dallapiccola, B., Gleeson, J.G., 2006. Mutations in *CEP290*, which encodes a centrosomal protein, cause pleiotropic forms of Joubert syndrome. *Nature Genetics* 38, 623–625.
- West-Hyde, L., Buyukmihci, N., 1982. Photoreceptor degeneration in a family of cats. *Journal of the American Veterinary Medical Association* 181, 243–247.