



UNIVERSITY OF
CALGARY

University of Calgary

PRISM: University of Calgary's Digital Repository

Cumming School of Medicine

Cumming School of Medicine Research & Publications

2012-06-20

Will the real multiple sclerosis please stand up?

Stys, Peter K.; Zamponi, Gerald W.; Geurts, Jeroen J. G.;
Van-Minnen, Jan

Macmillan Publishers Limited

Stys, P., Zamponi, G., van Minnen, J. and Geurts, J. (2012). Will the real multiple sclerosis please stand up?. *Nature Reviews Neuroscience*, 13, pp.507-513. doi:10.1038/nrn3275

<http://hdl.handle.net/1880/106648>

unknown

<https://creativecommons.org/licenses/by/4.0>

Downloaded from PRISM: <https://prism.ucalgary.ca>

OPINION

Will the real multiple sclerosis please stand up?

Peter K. Stys, Gerald W. Zamponi, Jan van Minnen and Jeroen J. G. Geurts

Abstract | Multiple sclerosis (MS) is considered to be an autoimmune, inflammatory disease of the CNS. In most patients, the disease follows a relapsing–remitting course and is characterized by dynamic inflammatory demyelinating lesions in the CNS. Although on the surface MS may appear consistent with a primary autoimmune disease, questions have been raised as to whether inflammation and/or autoimmunity are really at the root of the disease, and it has been proposed that MS might in fact be a degenerative disorder. We argue that MS may be an ‘immunological convolution’ between an underlying primary degenerative disorder and the host’s aberrant immune response. To better understand this disease, we might need to consider non-inflammatory primary progressive MS as the ‘real’ MS, with inflammatory forms reflecting secondary, albeit very important, reactions.

Multiple sclerosis (MS) is one of the most common causes of neurological disability in young adults. Traditionally considered to be an autoimmune inflammatory disorder mediated by an aberrant T cell attack against CNS elements, particularly myelin, MS initially presents as a relapsing–remitting disease in most patients and exhibits a compelling autoimmune and inflammatory phenotype on laboratory and radiological tests. Patients commonly have oligoclonal immunoglobulin G in the cerebrospinal fluid (CSF) and transient gadolinium-enhancing lesions on magnetic resonance scans, which are indicative of inflammation and blood–brain barrier breakdown. In addition, pathological examinations of biopsied or post-mortem brains of patients with MS show characteristic perivascular inflammatory infiltrates, consisting mainly of T cells and macrophages, together with myelin breakdown and degeneration of axons^{1,2}. Although MS has traditionally been thought of as a disease of the white matter, recent evidence indicates that grey matter structures (that is, neurons and synapses) of the brain are also affected³.

Given its indisputable inflammatory character, this disease was — unsurprisingly

— proposed to have a primary autoimmune aetiology. Consequently, a huge body of research conducted over the past several decades has focused on uncovering the immunological cause (or causes) and molecular targets. These investigations have taught us a great deal about the immunobiology, genetics and epidemiology of MS. Strong genetic associations with immune regulation have been uncovered⁴, mechanisms of immune attack against CNS elements elucidated⁵ and pharmacological agents developed, all aimed at modulating the immune system⁶. This approach, based on the overwhelming evidence that the disease has an inflammatory phenotype, rests on the assumption that the pathophysiology begins with an immune dysregulation — that is, it is based on an ‘outside-in’ model of MS (FIG. 1), according to which a systemic abnormality of the immune system targets the CNS. However, clinical experience has raised some troubling inconsistencies that cast doubt on this assumption, and it has been proposed that MS might instead be a degenerative disorder^{7,8}.

In this Perspective, we first discuss clinical observations in MS and compare them to diseases that resemble MS but that have

known metabolic causes. We highlight potential inconsistencies with the primary autoimmune hypothesis of MS that, we argue, support an alternative, ‘inside-out’ model (FIG. 1). On the basis of this alternative model, we then argue that the ‘real’ MS is a primary progressive disease in which a putative underlying degenerative process^{8,9} proceeds similarly to other neurodegenerative disorders, remaining relatively unaltered by excess inflammation. We argue that focusing on the robust inflammation in relapsing–remitting inflammatory MS variants could possibly skew our approach to achieving an understanding of the underlying processes of MS. Finally, we speculate on some of the possible non-immune molecular targets that may be dysregulated in MS, the study of which may lead us closer to an understanding of its root cause.

Clinical observations and inconsistencies

On the surface, laboratory and clinical observations seem to be largely consistent with an outside-in model of MS. However, there are some important inconsistencies.

First, careful pathological examinations, particularly in the initial stages of the disease, have revealed that the earliest myelin abnormalities might begin at the inner myelin sheath that surrounds still-myelinated axons, consisting of a uniform widening of inner myelin lamellae, often in areas beyond the foci of inflammation¹⁰. Moreover, the outer myelin wraps are often still intact. Immunochemical studies on early MS lesions corroborate these observations, as they show preferential loss of myelin-associated glycoprotein, an adhesion molecule expressed on the inner periaxonal wraps of myelin¹¹; if an extrinsic immune cell- or antibody-mediated attack were primarily responsible for such early changes, one would not expect these changes to occur in the innermost myelin regions. Although the start of pathology at the inner sheath is consistent with a primary insult directed to this area, it does not prove it, as it could also reflect an insult to the oligodendrocyte soma. However, it is noteworthy that ultrastructural evidence of myelin damage was seen beyond areas of maximal inflammation, suggesting that demyelination may precede

inflammation in some cases¹⁰. Extending these earlier observations, more recent studies on autopsy material from patients in early, active stages of MS show little evidence of T cell or B cell infiltration in areas of brisk demyelination and oligodendrocyte loss; they only show macrophage infiltration and microglial activation, which is evidence of an innate immune response that is triggered to clear debris^{12,13}. Studies using material from early and very active MS lesions have been criticized because such early lesions may not be representative of the much more frequently occurring chronic inflammatory plaques in which immune infiltrates are always intermingled with demyelination and that show evidence of remyelination. We propose that by virtue of the highly immunogenic nature of myelin antigens^{14–16}, the shedding of myelin debris is quickly accompanied by a secondary immune cell infiltrate. If this proposal is correct, this means that only by examining such early and active areas of pathology do we have a chance of

capturing their development at a time when degeneration of (mainly) oligodendrocytes and myelin takes place, but before immune cells invade (which may occur in a matter of days or sooner)¹³. Indeed, active cortical MS plaques exhibit substantial ongoing neuritic injury with far less inflammatory infiltration compared with white matter plaques¹⁷. This is consistent with our contention that degeneration of white and grey matter elements proceeds on its own, and that the degree of inflammatory reaction is governed mainly by the amount of released immunogenic myelin-derived material.

Second, brains of patients with MS commonly exhibit diffusely abnormal white matter in which myelin and axonal density are reduced but inflammation is not apparent¹⁸. Moreover, normal-appearing white matter from these patients exhibits myelin and axonal degeneration as well, with little evidence of an adaptive immune response^{13,19}. A recent histopathological study that carefully assessed inflammation in the brains of patients with late-stage progressive MS found a close correlation between the level of inflammatory T cell and B cell infiltration and the amount of cellular (especially axonal) injury²⁰. The authors concluded that inflammation therefore probably drives the progressive degeneration. Although this is certainly a possibility, such associations are equally consistent with the converse: that continuing primary degeneration engenders a persistent inflammatory response, commensurate with the pace of ongoing cellular breakdown and with the vigour of the prevailing immune predilection, which wanes with age²¹. Such a scenario would also result in a close association between cellular degeneration and inflammatory infiltration, as was observed experimentally²⁰. We argue that such correlative studies, no matter how carefully conducted, are equally consistent with either thesis.

Third, clinical experience with currently available pharmacotherapeutics, which are designed to suppress the immune and inflammatory response, reveals further interesting inconsistencies. There is overwhelming evidence that immune modulators that are widely prescribed to patients with relapsing–remitting MS are highly effective at reducing, and indeed in some instances almost completely eliminating, both relapses and neuroinflammation. Despite the utility of these drugs in relapsing–remitting MS, they are largely ineffective in later, progressive phases of the disease and in patients with primary progressive MS, whose disease course begins in a monotonically progressive,

non-inflammatory manner^{22–25} (BOX 1). Similarly, autologous haematopoietic stem cell transplantation in patients with MS induces a profound alteration in the immune system and almost completely halts inflammatory activity in the CNS²⁶, yet demyelination, axonal degeneration and brain atrophy still progress^{27–30}. The fact that these treatments reduce both relapses and inflammation but fail to halt disease progression raises questions about the commonly assumed primary autoimmune pathogenesis of MS: if autoimmunity were at the root of this disease, would immunoablation, or indeed, a complete resetting of the immune system, not be as effective at mitigating the later, progressive course as it is at suppressing the earlier, relapsing–remitting, inflammatory phase of MS? Proponents of the outside-in hypothesis argue that brisk inflammation early on sets up the brain for later, secondary, relentless degeneration, which somehow becomes independent of the initial inflammatory assault. In support of this position, patients with high inflammatory burden who began treatment with alemtuzumab (a monoclonal antibody directed against CD52, which is expressed on lymphocytes) continued to accumulate disability more rapidly than those with less inflammation before treatment began²². Moreover, even profound immunosuppression (by alemtuzumab) may fail to eradicate pathogenic CNS-resident immune cells, allowing continued inflammation-driven degeneration^{30,31}. However, the observations from this study²² are equally consistent with a model in which a highly aggressive initial degenerative course causes a high level of autoantigen shedding, which in turn triggers a brisk secondary inflammatory reaction. Suppressing this inflammatory reaction would then unmask the ongoing, more aggressive degeneration in these patients. Most interesting are repeated observations that the natural history of MS progression is largely independent of inflammatory relapse activity, and is indistinguishable between relapse–onset and primary progressive MS^{32–34} (BOX 1). Such observations are inconsistent with the notion that inflammation is the primary driver of accumulating disability and degeneration in this disease.

Last, genetic susceptibility to MS has been extensively studied over the years. The largest genome-wide association study to date⁴ confirmed that the major histocompatibility complex exerts the greatest influence on risk of developing MS and, moreover, many other immunologically relevant genes, particularly those involved in T cell

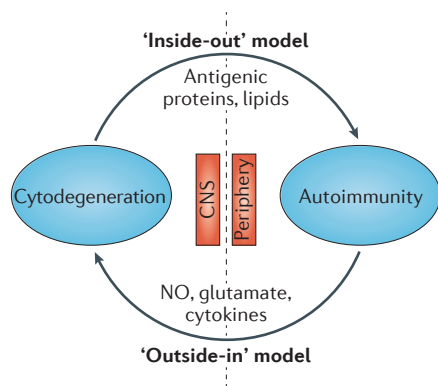


Figure 1 | Schematic contrasting the two competing hypothetical aetiologies of multiple sclerosis. Traditionally, multiple sclerosis (MS) has been considered to be an autoimmune disease in which dysregulated auto-reactive T cells in the periphery cross into the CNS and, together with macrophages and B cells, proceed to destroy various CNS elements. The resulting inflammatory reaction, which typically follows a relapsing–remitting clinical course in the initial stages, causes further demyelination and tissue injury. Such an ‘outside-in’ model is being challenged by a competing view^{7,8} that argues that the initial malfunction occurs within the CNS, similarly to other neurodegenerative disorders such as Alzheimer’s and Parkinson’s diseases. This alternative, ‘inside-out’ model argues that a primary cyto degeneration (possibly focused on the oligodendrocyte–myelin complex) is the initial event, and by releasing highly antigenic constituents, secondarily promotes an autoimmune and inflammatory response in the predisposed host, possibly further driving degeneration. NO, nitric oxide.

function, were shown to have significant roles. However, in line with the relative prevalence of relapsing–remitting MS versus primary progressive MS in the general population, almost 90% of the patients included in this study had relapsing–remitting disease. Given the strong inflammatory character of this variant of MS, it is no surprise that an overwhelmingly immune-centric genetic influence was uncovered. Importantly, a subgroup analysis of the primary progressive MS cohort detected only four robust associations with genes, all of which were unrelated to the immune system. The authors concluded that their results provide “compelling evidence that the critical disease mechanisms primarily involve immune dysregulation” (REF. 4), a conclusion with which we certainly agree. However, if the inside-out model — where the strong inflammatory character of relapsing–remitting MS reflects an immune reaction to some primary process — is correct, then such genome-association studies would reveal hard data about the mechanisms of such immune reactions, but not necessarily about mechanisms of the underlying primary cause. And most importantly, by the same reasoning, such studies in no way invalidate an inside-out explanation of the potential underlying cause of MS.

Thus, although proponents of an outside-in hypothesis might be correct, we suggest that an alternative, inside-out model is equally plausible and equally consistent with clinical experience. This model is explored in more detail below.

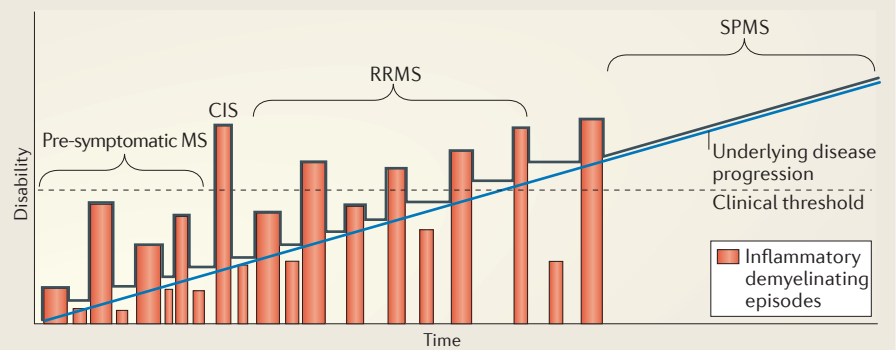
Redefining multiple sclerosis

The inside-out model of MS (FIG. 1) proposes that in MS, there is a primary ‘cytodegeneration’ that might initially be focused on the oligodendrocytes and myelin, presumably beginning years before any overt clinical symptoms occur (BOX 1). What sets MS apart from other monotonically progressive neurodegenerative disorders is the host’s predilection to react to the highly autoantigenic components (for example, citrullinated myelin basic protein (MBP)³⁵, myelin lipids³⁶ and externalized phosphatidylserine from ‘apoptotic myelin membranes’ (REF. 12)) that are released as a consequence of the cytodegeneration. Thus, this model proposes that MS results from a convolution between progressive cytodegeneration and a variably primed immune system.

Inter-individual variation in the extent of the immune priming could produce the curiously broad spectrum of MS presentations (FIG. 2). At one extreme, the rare,

Box 1 | The various forms of clinical multiple sclerosis

Although the cause of multiple sclerosis (MS) is not known, patients present with several common patterns of symptoms, and each pattern is associated with variable intensities of inflammatory response⁷⁹. The most common form, affecting ~85% of newly diagnosed patients, is relapsing–remitting MS (RRMS). It affects women two to three times more frequently than men and has a mean age of onset of around 30 years. RRMS is characterized by relapses of neurological dysfunction that last weeks to months and affect various locations of the brain, optic nerves and/or spinal cord. Multifocal areas of abnormality are found on magnetic resonance scanning, typically (but not exclusively) in the white matter. Some lesions exhibit enhancement after intravenous administration of gadolinium, indicating breakdown of the blood–brain barrier as a result of active inflammation. Over time, the majority of patients with RRMS enter into a phase of non-relapsing secondary progressive MS (SPMS) in which there is little inflammation and that, as the name implies, is characterized by slowly progressive neurological decline and CNS atrophy. In a minority of patients, the disease assumes a relatively non-inflammatory progressive course from the onset, and is termed primary progressive MS (PPMS). The mean age of onset of PPMS is about 10 years later than that of RRMS (~40 versus 30 years)⁸⁰, perhaps because the acute inflammatory episodes (see the figure, orange bars) in RRMS raise patients above the clinically detectable threshold years earlier. Curiously, although the initial courses of RRMS and PPMS are very different, the progressive phases of each proceed at remarkably similar rates^{34,81}. At the extreme end of the spectrum, the Marburg variant of MS is characterized by a very aggressive, highly inflammatory presentation that may mimic a brain tumour by virtue of the mass effect of the lesions and their contrast enhancement on brain scans. Other variations exist, such as clinically isolated syndrome (CIS), which often (but not always) progresses to MS, and the rarer progressive–relapsing MS, in which patients begin with a PPMS pattern, but suffer fluctuating neurological exacerbations⁸². Whether these patterns are variable manifestations of the same underlying disease or are fundamentally different diseases is unknown. Interestingly, evidence indicates that the progression of the underlying disease process (blue line in figure) is remarkably uniform, regardless of the presenting pattern.



aggressive Marburg variant of MS³⁷ may reflect a host whose immune system is strongly predisposed to react to the released antigens, resulting in a highly aggressive inflammatory presentation. Indeed, after the initially dramatic onset, and following strong immunosuppression, patients with the Marburg variant of MS generally progress in a manner that is similar to that in patients with more typical MS³⁸. On the other end of the spectrum, primary progressive MS might reflect primary cytodegeneration in a host whose immune system responds weakly. The weak immune response precludes a clinically relapsing–remitting course (which is driven by periodic inflammatory flare-ups; BOX 1), instead unmasking a slowly progressive phenotype that is similar to that of some ‘conventional’ neurodegenerative diseases such as Alzheimer’s disease and Parkinson’s disease (BOX 2). Indeed, a small minority of patients

with primary progressive MS exhibit a diffuse picture of white matter abnormalities with no focal inflammatory lesions whatsoever, suggesting a complete lack of immune response³⁹. According to our inside-out model, these two unusual types of MS would define the two extremes of the convolution between cytodegeneration and autoimmunity. The vast majority (~85%) of patients with MS fall somewhere in between these two extremes: the more common type of MS presents initially as an inflammatory relapsing–remitting disease and later — possibly because of a waning of the patients’ immune responsiveness through ‘immune senescence’ (REF. 21) — assumes a progressive course, with a rate that is independent of the age of onset, the initial inflammatory activity or whether the disease started as primary progressive or has transitioned from relapsing–remitting to secondary progression^{34,40} (BOX 1).

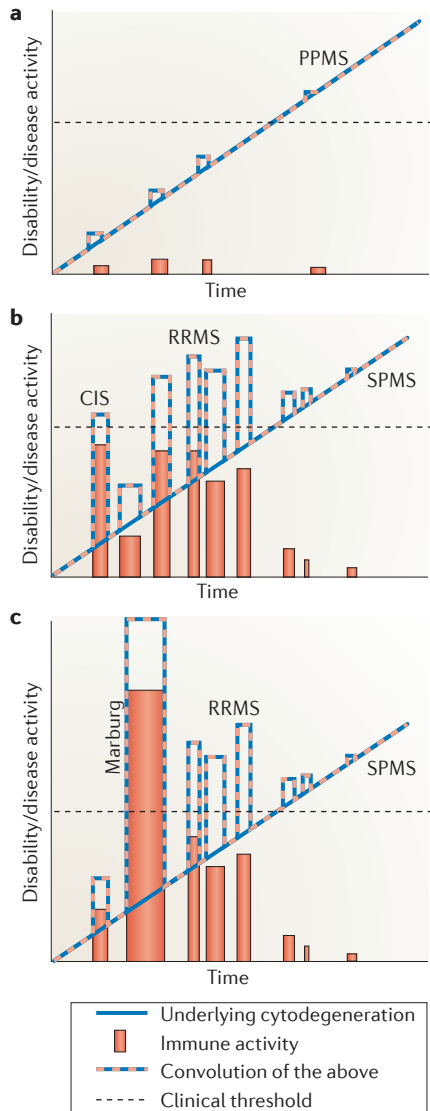


Figure 2 | Multiple sclerosis as an immunological convolution. The spectrum of clinical multiple sclerosis (MS) is variable, ranging from (a) a monotonically progressive course with little inflammation (primary progressive MS (PPMS)) and little, if any, periodic exacerbation; to (b) relapsing–remitting MS (RRMS) with prominent inflammatory manifestations and a robust response to anti-inflammatory drugs, possibly preceded by a clinically isolated syndrome (CIS) years before RRMS sets in; to (c) the occasionally very aggressive tumefactive Marburg variant. Our model suggests that the underlying cytodegenerative process (thick blue line) is similar in most patients, and that the wide clinical spectrum is governed by a convolution (dashed orange and blue lines) between this underlying degeneration and the host’s immune reaction to it (orange). Thus, MS requires these two intertwined ingredients, one uniformly progressive, the other intermittent and highly variable, which establish the type of disease in any one patient. We propose that the ‘real’ MS is the underlying cytodegeneration, which is most faithfully reflected by primary progressive disease. SPMS, secondary progressive MS

We propose that the type of MS with which a patient presents and the initial course of the disease are strictly governed by the strength of the convolution — that is, the intensity of the relationship — among the primary cytodegeneration, the release of antigenic debris and the secondary immune response. The immune response is an important ingredient in this model and sets MS apart from most CNS diseases, because it programs the ultimate clinical phenotype (mainly degenerative and monotonic versus highly inflammatory and fluctuating over time). After all, many neurological disorders are associated with white matter damage and release of antigenic debris, yet patients with these disorders do not develop MS, probably because they lack the additional immune predilection that so often accompanies what may be a primary degeneration of a uniquely antigenic cellular component in patients with MS. It is highly likely that immune-triggered inflammation in turn drives further damage and degeneration of CNS elements, creating a vicious cycle, as illustrated in FIG. 1. This is supported by evidence that anti-inflammatory drugs may delay the progression of disability in small subgroups of patients with progressive MS who exhibit persistent inflammation^{41,42}. However, the fundamental unanswered question is, which comes first: degeneration or inflammation?

Re-interpreting research findings. As most patients with MS initially fall into the relapsing–remitting inflammatory category, laboratory and clinical research efforts have understandably focused on this population. However, if the inside-out model of MS is correct, these research efforts may inadvertently be exploring the immune reaction to the initial events in the disease, rather than elucidating the fundamental cause of MS per se. Decades of investigation have taught us a great deal about the immunopathogenesis and genetics of inflammatory MS. Perhaps the best example is the finding of a 30% concordance for MS among monozygotic twins¹. The undisputable hereditary nature of MS — if we define MS mainly as inflammatory relapsing–remitting disease and therefore mainly capture such patients in studies — could be a reflection of the twins’ shared immune predilection to react to some poorly understood, and indeed poorly studied, underlying process. Unfortunately, there are insufficient data to draw firm conclusions about the hereditary influence among patients with primary progressive MS, but elucidating the degree of

concordance among such genetically related patients (for example, monozygotic twins in primary progressive MS) would be very interesting. Our central thesis is that the real MS is a primary progressive disease that has not been perturbed by a clinically and biologically important, but potentially distracting, inflammatory reaction.

Animal models may also skew our understanding of the basis of human MS. Such models are useful, but tend to elucidate mechanisms that are deliberately selected a priori for perturbation. Experimental autoimmune encephalomyelitis (EAE), a widely used model of MS⁴³, is a good example. In EAE, rodents are injected with myelin antigens together with immune boosters to elicit an inflammatory autoimmune reaction to CNS myelin. If we assume from the start that MS is a primary autoimmune inflammatory disease, then EAE is a very good model that recapitulates many of the inflammatory demyelinating manifestations of human relapsing–remitting MS. In light of our inside-out hypothesis, however, we suggest that EAE is instead a very good model of the inflammatory reaction that occurs in human relapsing–remitting MS, but may not reflect the underlying disease process⁴⁴.

Comparisons with other diseases that resemble MS.

The proposal that degeneration of white matter elements may result in an inflammatory CNS disease is not without precedent. For example, Warshawsky *et al.*⁴⁵ reported a patient with a syndrome that was highly suggestive of primary progressive MS. MRI features and visual evoked potentials were consistent with such a diagnosis, and the patient’s CSF contained oligoclonal immunoglobulin G, indicating an immune response within the CNS. This patient was found to harbour a new mutation of the gene encoding proteolipid protein 1 (PLP1), which is a major protein constituent of CNS myelin.

Another example is Harding’s syndrome, which is described as an association between Leber’s hereditary optic neuropathy (LHON), which results from mutations in the mitochondrial genome, and relapsing–remitting MS. Patients with this syndrome typically present with visual loss due to a progressive optic neuropathy (typical LHON) and fluctuating multifocal inflammatory demyelination of the brain and spinal cord that is often indistinguishable from relapsing–remitting MS⁴⁶. Harding’s syndrome is often explained as an unfortunate coexistence of MS and LHON. However, it exhibits two curious anomalies that lead us to propose

an alternative explanation. First, Harding's syndrome occurs 50 times more frequently than would be expected on the basis of the prevalence of LHON and MS⁴⁷. Second, isolated LHON overwhelmingly affects males, whereas Harding's syndrome is much more common in females — in fact, its gender ratio is very similar to that of relapsing–remitting MS^{47–49}. Together, these features lead us to propose that Harding's syndrome represents an inflammatory reaction to an underlying white matter cytodeneration that is grounded in a known mitochondrial mutation. In this view, a subset of patients with the mitochondrial mutation reacts to the effects of this mutation with an immune response because they are immunologically predisposed, thereby transforming the clinical syndrome from one typical of LHON (in individuals who are not immunologically primed) into Harding's syndrome, with an MS-like picture. The fact that most patients with Harding's syndrome are female — despite the strong male preponderance of isolated LHON — could be explained by the fact that young females are known to be more predisposed to autoimmune diseases in general⁵⁰. A specific Harding's syndrome case report is instructive: the study⁵¹ reported a female patient with a documented mitochondrial mutation, relapsing optic neuropathy and a fluctuating steroid-responsive MS-like syndrome. In addition, the patient developed Hashimoto's thyroiditis, a well-known autoimmune thyroid disorder. This case may be interpreted as one with a documented mitochondrial defect in a patient who clearly has an autoimmune predisposition (by virtue of her thyroiditis), which together culminated in a typical relapsing–remitting MS-like disorder.

These examples illustrate that, in predisposed individuals, the immune system can mount an inflammatory response to primary degeneration in the CNS, particularly when white matter is involved, with varying degrees of vigour that culminate in a clinical picture that is almost indistinguishable from various traditional forms of MS encountered clinically. In our view, such examples convincingly support the plausibility of an inside-out model of MS.

Potential mechanisms

If the inside-out model is the correct one, the key question that arises is: what are the potential underlying mechanisms that trigger progressive cytodeneration? The answer is of course unknown, but in this section we will speculate on plausible signalling pathways. A potentially informative

Box 2 | Inflammation versus degeneration

One might reasonably ask why other common neurodegenerative disorders, such as Alzheimer's disease and Parkinson's disease, do not also result in relapsing–remitting neuroinflammation. In fact, both diseases do exhibit inflammation in pathologically vulnerable regions^{83,84}. Indeed, in these research fields there is also an ongoing debate about whether inflammation is a reaction to, or cause of, ongoing degeneration. For example, post-mortem examination of human and primate brains after exposure to MPTP (1-methyl-4-phenyl-1,2,3,6-tetrahydropyridine), a neurotoxin that induces parkinsonian features by killing dopaminergic neurons, reveals a sustained inflammatory response that continues for years after exposure to the toxin^{85,86}. Clearly, in this example the initiating insult was a monophasic degenerative one (toxin-induced death of a specific neuronal population), which secondarily entrained a protracted inflammatory reaction and, interestingly, continued neurodegeneration that long outlasts the toxic insult. The reasonable question that was raised was whether such secondary inflammation could now feed back and promote further degeneration, completing an analogous 'inside-out' cycle as we propose for multiple sclerosis (MS) (FIG. 1). Because diseases such as Alzheimer's and Parkinson's have a much more prominent degenerative rather than inflammatory phenotype, the initial assumption was that a degenerative mechanism (or mechanisms) was primarily responsible, with inflammation perhaps a secondary, but possibly important, consequence of the degeneration. In MS, the situation is reversed: inflammation occurs early and is very prominent in many patients, so it was naturally assumed that autoimmunity might be causal; but, as we argue throughout this Perspective, such an assumption may be incorrect. If MS is primarily a degenerative disorder in line with an inside-out mechanism, why would this disease be unique in engendering such prominent and cyclic inflammation? The differences may be related to age: Alzheimer's disease and Parkinson's disease present decades later than MS, and immune responsiveness wanes with age through a process of 'immune senescence' (REFS 21,87). Indeed, the responsiveness of T cells, which are known to be centrally involved in the immunopathogenesis of MS⁸⁸, appears to be particularly altered with age⁸⁷. Moreover, it is conceivable that the putative cytodeneration involving the myelinating unit (oligodendroglia, their processes and myelin) in MS releases debris that is more antigenic^{35,36,66} than the debris that is shed from the mainly synaptic and neuronal degeneration in Alzheimer's disease and other traditional neurodegenerative disorders.

and widely used model of demyelination is the cuprizone model, which is used to reflect certain aspects of MS. In this model, rodents are fed the copper chelator cuprizone, which results in varying degrees of oligodendroglial damage and demyelination in the CNS, with little inflammatory reaction⁵². In humans, the neurological sequelae of copper deficiency also mainly manifest as a demyelinating myelopathy and leukoencephalopathy⁵³. Together, this suggests that a deficiency of copper ions in the CNS promotes demyelination and loss of myelinating oligodendroglia. Recent data indicate that copper ions are potent modulators of NMDA receptor (NMDAR) desensitization, leading to neuronal death^{54,55}. Like neurons, oligodendrocytes and the myelin sheath express NMDARs^{56–58} (reviewed in REF. 59). Thus, it is tempting to speculate that in MS, a dysregulation of copper homeostasis may result in a reduced ability of this metal to restrain NMDAR activity in myelin, oligodendrocytes and neurons. This could lead to chronic overactivation of these receptors, promoting white and grey matter degeneration^{60,61}. Alternatively, it is possible that NMDAR dysfunction may occur without alterations in copper homeostasis (for example, via altered cell signalling events in oligodendrocytes) to cause myelin damage in MS,

and that copper chelation with cuprizone in rodents simply experimentally increases NMDAR activity. An immunologically predisposed human host might react with various degrees of vigour to the released autoantigens, resulting in the broad spectrum of clinical MS presentations. It should be noted that there is currently no evidence of dysregulation of copper homeostasis in the brains of patients with MS, although such an abnormality may be subtle and highly compartmentalized at inter-neuronal and axo-myelinic synapses⁶².

Secondary inflammation. In an effort to answer the question of whether oligodendrocyte degeneration can trigger an autoimmune response, it has recently been reported⁶³ that inducing primary death of oligodendrocytes per se does not engender an autoimmune reaction, despite causing robust demyelination. This was even the case when they induced concomitant strong stimulation of the immune system⁶³. As the authors did not observe the robust immune response that is seen in human MS, they interpreted these findings as evidence against a neurodegenerative hypothesis for MS pathogenesis. However, there is precedent in human disease that a primary injury to oligodendroglia does not necessarily trigger an autoimmune

reaction, even with robust secondary degeneration of myelin: for example, in multiple system atrophy (a degenerative disorder), the main target of the disease process is the oligodendrocyte, with prominent secondary myelin degeneration⁶⁴. Other than a reactive microgliosis, there is no adaptive immune response. On the basis of these findings, one could suggest that either the immune system in patients with MS is uniquely primed in a way that could not be replicated in the animal study described above^{63,64}, or that primary oligodendroglial injury may not be the initiating event in MS.

With regard to this second possibility, in adult rodent oligodendroglia, NMDAR expression is mainly concentrated on processes and on myelin, particularly on the inner membranes of the myelin sheath⁵⁹. If overactivation of these receptors contributes to MS pathogenesis, it would follow that a specific biochemical alteration of myelin (as opposed to the oligodendrocyte soma) that results in the release of uniquely antigenic

components could be the key ingredient required to elicit an autoimmune reaction in a predisposed host; for example, such an alteration could be caused by NMDAR-mediated Ca²⁺ influx into the myelin or by pathological activation of Ca²⁺-dependent enzymes such as calpain, phospholipase C or peptidylarginine deiminase 2, with the latter resulting in citrullinated myelin proteins (see below)⁶⁵. Ultrastructural examination of tissue from patients with MS showing that the inner myelin wraps (where most myelinic NMDARs are located⁵⁷) may be the first location of abnormality in MS¹⁰ is consistent with this proposal. Moreover, citrullination of MBP renders this major myelin constituent highly encephalitogenic⁶⁶. Myelin from patients with MS contains a greater proportion of citrullinated MBP than myelin from healthy human brains³⁵ and, interestingly, this proportion is greater still in highly inflammatory Marburg MS⁶⁷. The enzyme responsible for citrullination of arginine residues on MBP, Ca²⁺-dependent peptidylarginine deiminase 2, is present in myelin⁶⁸. Combined with the expression of highly Ca²⁺-permeable NMDARs on myelin, this suggests that the sheath may be prone to the generation of uniquely antigenic material that might elicit an autoimmune reaction. Thus, the autoimmune response could initially be triggered by a primary myelinopathy rather than an oligodendroglial pathology. In this regard, transgenic animal models are very instructive. For example, mice overexpressing proteolipid protein in oligodendrocytes exhibit a progressive myelinopathy, but in contrast to primary oligodendrocyte degeneration and death, either in a mouse model⁶³ or in the context of human multiple system atrophy⁶⁴, the proteolipid protein-overexpressing mice mount a substantial spontaneous CD8⁺ T cell inflammatory response that in turn causes additional CNS damage⁶⁹. Taken together, these data suggest that immune responsiveness seems to be highly dependent on which element of the myelinating unit is degenerating (oligodendrocyte soma versus myelin) and, possibly in addition, on the biochemical make-up of the resulting debris. They further suggest that in MS, a primary myelinopathy may be the earliest event, which then becomes an immune-trigger and causes the frequent inflammatory reactions that are found in the white matter.

Axonal damage. Degeneration of demyelinated CNS axons is increasingly recognized as a common, if not ubiquitous, accompaniment to inflammatory demyelination.

Continuing loss of axons, both in areas with obvious evidence of inflammation and in regions exhibiting little, if any, inflammatory activity, underlies the progressive and irreversible clinical deficits associated with MS⁹. Axons may be damaged by the same underlying primary degenerative processes that affect the myelinating unit, or they might undergo secondary degeneration by virtue of demyelination (or both). How might axonal damage be triggered? Internodal axons express glutamate receptors⁷⁰, and it is possible that these could be chronically overactivated by a copper-dependent mechanism (see above) or by another, unknown mechanism, thereby leading to primary axonal pathology. At the moment this is purely hypothetical. Alternatively, axonal damage in MS might be a secondary phenomenon. For example, it could be 'bystander' damage from the release of glutamate, nitric oxide, cytokines and perforin from immune cells in the vicinity of inflammatory plaques⁷¹⁻⁷³. However, such a mechanism cannot explain the progressive axonal pathology in widespread areas of normal-appearing white matter that show little or no evidence of inflammation¹⁹.

Secondary axonal damage could also occur through non-inflammatory mechanisms that cause disruptions of the close physical and biochemical relationship between axons and their myelin sheaths. Myelin insulation reduces the energy demand during impulse propagation; demyelinated fibres are placed at an energetic disadvantage because of increased ionic leaks across the denuded axon membrane, resulting in an increased energy demand for ion pumping⁷⁴. In addition, energy production may be compromised owing to mitochondrial disruption⁷⁵ and Na⁺-K⁺-ATPase-mediated ion transport may be reduced⁷⁶ in many demyelinated axons in the MS brain, which could bias such an axon towards a state of 'virtual hypoxia' (REF. 77). The resulting mismatch between energy supply and demand could culminate in degeneration⁷⁴.

A third possible mechanism of secondary axonal degeneration in MS involves another potentially important glial function. In the peripheral nervous system, glia support axons by intercellular transfer of polyribosomes⁷⁸. This arrangement allows axons to synthesize proteins locally, obviating the need to transport material from a distant soma. Although still hypothetical at the moment, it is possible that oligodendrocytes support axons in a similar manner in the CNS, so that a stable relationship between myelin and axon is essential to ensure a persistent supply

Glossary

Demyelinating myelopathy

Pathology of the spinal cord mainly due to loss of myelin from afferent and efferent spinal axons, which results in slowing or complete block of impulse transmission. It is also associated with para- or quadriplegia, sensory disturbances, bowel and bladder dysfunction and gait abnormalities.

Encephalitogenic

Having a propensity to cause inflammation of the brain.

Gadolinium-enhancing lesions

A contrast agent that leaks into the parenchyma in areas of blood-brain barrier breakdown. These regions are seen as bright signal with specific magnetic resonance sequences and are thus 'enhanced' by gadolinium, indicating pathology.

Leber's hereditary optic neuropathy

(LHON). A disease caused by a mutation in mitochondrial DNA. It is characterized by bilateral, painless, gradual visual loss starting in young adult life that is caused by degeneration of retinal ganglion cells and optic nerves.

Leukoencephalopathy

A generic term referring to pathology mainly involving white matter tracts of the brain (from Greek *leukos*: white).

Relapse

New neurological signs and symptoms, new lesions on magnetic resonance scanning.

Relapsing-remitting MS

The most common presentation of MS. It is characterized by repeated relapses that may last from weeks to months, followed by complete or incomplete clinical improvement.

Tumefactive

Characterized by pronounced swelling, occupying additional volume within the brain, thereby pushing aside and frequently compromising adjacent normal structures.

of ribosomes for local protein translation within the ensheathed fibre. Disturbance of this relationship as a result of oligodendrocyte degeneration or frank demyelination would hinder this supply, leading to a state of 'ribosomal starvation' and an impairment of local axonal synthesis of replacement protein. The above mechanisms are speculative at the moment but may have an important role and are likely to be exacerbated by an additive injurious influence of various levels of ambient inflammation.

Conclusions and future directions

In closing, we wish to emphasize that autoimmunity and neuroinflammation are very important manifestations of MS that have a central role in both the fluctuating neurological deficits in relapsing–remitting MS and in the accumulating CNS injury in these patients. For this reason, anti-inflammatory therapies are and always will be relevant. However, although there is little disagreement about the pathology and immunobiology of MS, the key unanswered question is which process is the initial trigger: cytodeneration (inside-out) or a primary autoimmune attack (outside-in)? In this Perspective we have argued that current knowledge is, at a minimum, equally consistent with either model. Indeed, the failure of potent immunosuppression to affect later, progressive MS suggests that a primary cytodenerative mechanism could be a more plausible initiating event, and progressive non-inflammatory MS (that is, primary progressive MS) may thus be most reflective of the real underlying disease. The corollary is that EAE, the most commonly used animal model of MS, may be a good model of the autoimmune inflammatory reaction to the putative cytodeneration, rather than of the real disease. Instead, models of degeneration resulting in primary damage to oligodendrocytes, myelin and axons may be more relevant and informative. The cuprizone model is one such approach in which depletion of copper results in CNS demyelination. Given the recent demonstration of potent copper-dependent regulation of NMDARs⁵⁴ and of expression of functional NMDARs in myelin⁵⁷, one might speculate that some abnormality of copper-dependent regulation of myelinic NMDARs may underlie human MS. A variably primed immune response could explain the broad spectrum of human MS, ranging from strongly to weakly inflammatory, but always with a monotonically progressive underlying degeneration. The fact that inflammation is so often and so rapidly intertwined with a

putative cytodeneration implies that studying autopsy material or established MS lesions is unlikely to ever untangle the uncertainty of which mechanism initiates the disease.

Finally, these arguments have fundamentally important implications for therapeutic design. Using EAE to test and develop drugs to treat MS will naturally bias the outcome towards effective anti-inflammatory agents, without necessarily engineering in effectiveness against degenerative processes; this has been our experience to date with MS therapeutics. Instead, additional focus on the structure and function of NMDARs, their regulatory mechanisms and state-specific antagonists may better address the degenerative component of MS. By recognizing, understanding and targeting such degenerative mechanisms, future adjunctive therapeutics will hopefully target both key components of MS, an approach that will be essential for optimal control of all stages of this disease.

Peter K. Stys is at the Department of Clinical Neurosciences, Hotchkiss Brain Institute, University of Calgary, Calgary, Alberta T2N 4N1, Canada.

Gerald W. Zamponi is at the Department of Physiology and Pharmacology, Hotchkiss Brain Institute, University of Calgary, Calgary, Alberta T2N 4N1, Canada.

Jan van Minnen is at the Department of Cell Biology and Anatomy, Hotchkiss Brain Institute, University of Calgary, Calgary, Alberta T2N 4N1, Canada.

Jeroen J. G. Geurts is at the Department of Anatomy and Neurosciences, Section of Clinical Neuroscience, VU University Medical Center, van der Boechorststraat 7, 1081 BT Amsterdam, The Netherlands.

Correspondence to P.K.S.
e-mail: pstys@ucalgary.ca

doi:10.1038/nrn3275
Corrected online 4 July 2012

- Noseworthy, J. H., Lucchinetti, C., Rodriguez, M. & Weinshenker, B. G. Multiple sclerosis. *N. Engl. J. Med.* **343**, 938–952 (2000).
- Frohman, E. M., Racke, M. K. & Raine, C. S. Multiple sclerosis — the plaque and its pathogenesis. *N. Engl. J. Med.* **354**, 942–955 (2006).
- Geurts, J. J., Stys, P. K., Minagar, A., Amor, S. & Zivadinov, R. Gray matter pathology in (chronic) MS: modern views on an early observation. *J. Neurol. Sci.* **282**, 12–20 (2009).
- Sawcer, S. *et al.* Genetic risk and a primary role for cell-mediated immune mechanisms in multiple sclerosis. *Nature* **476**, 214–219 (2011).
- Herz, J., Zipp, F. & Siffrin, V. Neurodegeneration in autoimmune CNS inflammation. *Exp. Neurol.* **225**, 9–17 (2010).
- Menge, T. *et al.* Disease-modifying agents for multiple sclerosis: recent advances and future prospects. *Drugs* **68**, 2445–2468 (2008).
- Hauser, S. L. & Oksenberg, J. R. The neurobiology of multiple sclerosis: genes, inflammation, and neurodegeneration. *Neuron* **52**, 61–76 (2006).
- Trapp, B. D. & Nave, K. A. Multiple sclerosis: an immune or neurodegenerative disorder? *Annu. Rev. Neurosci.* **31**, 247–269 (2008).
- Dutta, R. & Trapp, B. D. Mechanisms of neuronal dysfunction and degeneration in multiple sclerosis. *Prog. Neurobiol.* **93**, 1–12 (2011).
- Rodriguez, M. & Scheithauer, B. Ultrastructure of multiple sclerosis. *Ultrastruct. Pathol.* **18**, 3–13 (1994).
- Aboul-Enein, F. *et al.* Preferential loss of myelin-associated glycoprotein reflects hypoxia-like white matter damage in stroke and inflammatory brain diseases. *J. Neuropathol. Exp. Neurol.* **62**, 25–33 (2003).
- Barnett, M. H. & Prineas, J. W. Relapsing and remitting multiple sclerosis: pathology of the newly forming lesion. *Ann. Neurol.* **55**, 458–468 (2004).
- Henderson, A. P., Barnett, M. H., Parratt, J. D. & Prineas, J. W. Multiple sclerosis: distribution of inflammatory cells in newly forming lesions. *Ann. Neurol.* **66**, 739–753 (2009).
- Bhat, R. & Steinman, L. Innate and adaptive autoimmunity directed to the central nervous system. *Neuron* **64**, 123–132 (2009).
- Bielekova, B. *et al.* Encephalitogenic potential of the myelin basic protein peptide (amino acids 83–99) in multiple sclerosis: results of a phase II clinical trial with an altered peptide ligand. *Nature Med.* **6**, 1167–1175 (2000).
- Podbielska, M. & Hogan, E. L. Molecular and immunogenic features of myelin lipids: incitants or modulators of multiple sclerosis? *Mult. Scler.* **15**, 1011–1029 (2009).
- Peterson, J. W., Bo, L., Mork, S., Chang, A. & Trapp, B. D. Transected neurites, apoptotic neurons, and reduced inflammation in cortical multiple sclerosis lesions. *Ann. Neurol.* **50**, 389–400 (2001).
- Seewann, A. *et al.* Diffusely abnormal white matter in chronic multiple sclerosis: imaging and histopathologic analysis. *Arch. Neurol.* **66**, 601–609 (2009).
- Trapp, B. D. *et al.* Axonal transection in the lesions of multiple sclerosis. *N. Engl. J. Med.* **338**, 278–285 (1998).
- Frischer, J. M. *et al.* The relation between inflammation and neurodegeneration in multiple sclerosis brains. *Brain* **132**, 1175–1189 (2009).
- Boraschi, D. *et al.* Ageing and immunity: addressing immune senescence to ensure healthy ageing. *Vaccine* **28**, 3627–3631 (2010).
- Coles, A. J. *et al.* Monoclonal antibody treatment exposes three mechanisms underlying the clinical course of multiple sclerosis. *Ann. Neurol.* **46**, 296–304 (1999).
- Molyneux, P. D. *et al.* The effect of interferon beta-1b treatment on MRI measures of cerebral atrophy in secondary progressive multiple sclerosis. *Brain* **123**, 2256–2263 (2000).
- Filippi, M. *et al.* The effect of cladribine on T₁ 'black hole' changes in progressive MS. *J. Neurol. Sci.* **176**, 42–44 (2000).
- Hawker, K. Progressive multiple sclerosis: characteristics and management. *Neurol. Clin.* **29**, 423–434 (2011).
- Mancardi, G. & Saccardi, R. Autologous haematopoietic stem-cell transplantation in multiple sclerosis. *Lancet Neurol.* **7**, 626–636 (2008).
- Inglese, M. *et al.* Brain tissue loss occurs after suppression of enhancement in patients with multiple sclerosis treated with autologous haematopoietic stem cell transplantation. *J. Neurol. Neurosurg. Psychiatry* **75**, 643–644 (2004).
- Bruck, W. Inflammatory demyelination is not central to the pathogenesis of multiple sclerosis. *J. Neurol.* **252** (Suppl. 5), 10–15 (2005).
- Metz, I. *et al.* Autologous haematopoietic stem cell transplantation fails to stop demyelination and neurodegeneration in multiple sclerosis. *Brain* **130**, 1254–1262 (2007).
- Lu, J. Q. *et al.* Neuroinflammation and demyelination in multiple sclerosis after allogeneic hematopoietic stem cell transplantation. *Arch. Neurol.* **67**, 716–722 (2010).
- Lassmann, H. Pathophysiology of inflammation and tissue injury in multiple sclerosis: what are the targets for therapy. *J. Neurol. Sci.* **306**, 167–169 (2011).
- Kremenetzky, M., Rice, G. P., Baskerville, J., Wingerchuk, D. M. & Ebers, G. C. The natural history of multiple sclerosis: a geographically based study 9: observations on the progressive phase of the disease. *Brain* **129**, 584–594 (2006).
- Confavreux, C. & Vukusic, S. Age at disability milestones in multiple sclerosis. *Brain* **129**, 595–605 (2006).
- Scalfari, A. *et al.* The natural history of multiple sclerosis: a geographically based study 10: relapses and long-term disability. *Brain* **133**, 1914–1929 (2010).
- Moscarello, M. A., Mastroradi, F. G. & Wood, D. D. The role of citrullinated proteins suggests a novel mechanism in the pathogenesis of multiple sclerosis. *Neurochem. Res.* **32**, 251–256 (2007).
- Kanter, J. L. *et al.* Lipid microarrays identify key mediators of autoimmune brain inflammation. *Nature*

- Med.* **12**, 138–143 (2006).
37. Capello, E. & Mancardi, G. L. Marburg type and Baló's concentric sclerosis: rare and acute variants of multiple sclerosis. *Neurol. Sci.* **25** (Suppl. 4), 361–363 (2004).
 38. Lucchinetti, C. F. *et al.* Clinical and radiographic spectrum of pathologically confirmed tumefactive multiple sclerosis. *Brain* **131**, 1759–1775 (2008).
 39. Zwermer, J. N., Bot, J. C., Jelles, B., Barkhof, F. & Polman, C. H. At the heart of primary progressive multiple sclerosis: three cases with diffuse MRI abnormalities only. *Mult. Scler.* **14**, 428–430 (2008).
 40. Confavreux, C., Vukusic, S., Moreau, T. & Adeleine, P. Relapses and progression of disability in multiple sclerosis. *N. Engl. J. Med.* **343**, 1430–1438 (2000).
 41. Kappos, L. *et al.* Interferon β -1b in secondary progressive MS: a combined analysis of the two trials. *Neurology* **63**, 1779–1787 (2004).
 42. Hawker, K. *et al.* Rituximab in patients with primary progressive multiple sclerosis: results of a randomized double-blind placebo-controlled multicenter trial. *Ann. Neurol.* **66**, 460–471 (2009).
 43. Pachner, A. R. Experimental models of multiple sclerosis. *Curr. Opin. Neurol.* **24**, 291–299 (2011).
 44. Sriram, S. & Steiner, I. Experimental allergic encephalomyelitis: a misleading model of multiple sclerosis. *Ann. Neurol.* **58**, 939–945 (2005).
 45. Warshawsky, I., Rudick, R. A., Staugaitis, S. M. & Natowicz, M. R. Primary progressive multiple sclerosis as a phenotype of a PLP1 gene mutation. *Ann. Neurol.* **58**, 470–473 (2005).
 46. Vanopdenbosch, L., Dubois, B., D'Hooghe, M. B., Meire, F. & Carton, H. Mitochondrial mutations of Leber's hereditary optic neuropathy: a risk factor for multiple sclerosis. *J. Neurol.* **247**, 535–543 (2000).
 47. Palace, J. Multiple sclerosis associated with Leber's Hereditary Optic Neuropathy. *J. Neurol. Sci.* **286**, 24–27 (2009).
 48. Man, P. Y. *et al.* The epidemiology of Leber hereditary optic neuropathy in the North East of England. *Am. J. Hum. Genet.* **72**, 333–339 (2003).
 49. Koch-Henriksen, N. & Sorensen, P. S. The changing demographic pattern of multiple sclerosis epidemiology. *Lancet Neurol.* **9**, 520–532 (2010).
 50. Cooper, G. S. & Stroehla, B. C. The epidemiology of autoimmune diseases. *Autoimmun. Rev.* **2**, 119–125 (2003).
 51. Kovacs, G. G. *et al.* Neuropathology of white matter disease in Leber's hereditary optic neuropathy. *Brain* **128**, 35–41 (2005).
 52. Kipp, M., Clarner, T., Dang, J., Copray, S. & Beyer, C. The cuprizone animal model: new insights into an old story. *Acta Neuropathol.* **118**, 723–736 (2009).
 53. Prodan, C. I., Holland, N. R., Wisdom, P. J., Burstein, S. A. & Bottomley, S. S. CNS demyelination associated with copper deficiency and hyperzincemia. *Neurology* **59**, 1453–1456 (2002).
 54. You, H. *et al.* A β damages neurons by altering copper-dependent prion protein regulation of NMDA receptors. *Proc. Natl Acad. Sci. USA* **109**, 1737–1742 (2012).
 55. Stys, P. K., You, H. & Zamponi, G. W. Copper-dependent regulation of NMDA receptors by cellular prion protein: implications for neurodegenerative disorders. *J. Physiol.* **590**, 1357–1368 (2012).
 56. Karadottir, R., Cavelier, P., Bergersen, L. H. & Attwell, D. NMDA receptors are expressed in oligodendrocytes and activated in ischaemia. *Nature* **438**, 1162–1166 (2005).
 57. Micu, I. *et al.* NMDA receptors mediate calcium accumulation in central nervous system myelin during chemical ischaemia. *Nature* **439**, 988–992 (2006).
 58. Salter, M. G. & Fern, R. NMDA receptors are expressed in developing oligodendrocyte processes and mediate injury. *Nature* **438**, 1167–1171 (2005).
 59. Tsutsui, S. & Stys, P. K. Metabolic injury to axons and myelin. *Exp. Neurol.* 1 May 2012 (doi: org/10.1016/j.expneurol.2012.04.016).
 60. De Stefano, N. *et al.* Assessing brain atrophy rates in a large population of untreated multiple sclerosis subtypes. *Neurology* **74**, 1868–1876 (2010).
 61. Fisher, E., Lee, J. C., Nakamura, K. & Rudick, R. A. Gray matter atrophy in multiple sclerosis: a longitudinal study. *Ann. Neurol.* **64**, 255–265 (2008).
 62. Stys, P. K. The axo-myelinic synapse. *Trends Neurosci.* **34**, 393–400 (2011).
 63. Locatelli, G. *et al.* Primary oligodendrocyte death does not elicit anti-CNS immunity. *Nature Neurosci.* **5**, 543–550 (2012).
 64. Wenning, G. K., Stefanova, N., Jellinger, K. A., Poewe, W. & Schlossmacher, M. G. Multiple system atrophy: a primary oligodendroglialopathy. *Ann. Neurol.* **64**, 239–246 (2008).
 65. Harauz, G. & Musse, A. A. A tale of two citrullines — structural and functional aspects of myelin basic protein deimination in health and disease. *Neurochem. Res.* **32**, 137–158 (2007).
 66. Cao, L., Sun, D. & Whitaker, J. N. Citrullinated myelin basic protein induces experimental autoimmune encephalomyelitis in Lewis rats through a diverse T cell repertoire. *J. Neuroimmunol.* **88**, 21–29 (1998).
 67. Wood, D. D., Bilbao, J. M., O'Connors, P. & Moscarello, M. A. Acute multiple sclerosis (Marburg type) is associated with developmentally immature myelin basic protein. *Ann. Neurol.* **40**, 18–24 (1996).
 68. Wood, D. D. *et al.* Myelin localization of peptidylarginine deiminases 2 and 4: comparison of PAD2 and PAD4 activities. *Lab. Invest.* **88**, 354–364 (2008).
 69. Ip, C. W. *et al.* Immune cells contribute to myelin degeneration and axonopathic changes in mice overexpressing proteolipid protein in oligodendrocytes. *J. Neurosci.* **26**, 8206–8216 (2006).
 70. Stirling, D. P. & Stys, P. K. Mechanisms of axonal injury: internodal nanocomplexes and calcium deregulation. *Trends Mol. Med.* **16**, 160–170 (2010).
 71. Howe, C. L., Adelson, J. D. & Rodriguez, M. Absence of perforin expression confers axonal protection despite demyelination. *Neurobiol. Dis.* **25**, 354–359 (2007).
 72. Siffrin, V., Vogt, J., Radbruch, H., Nitsch, R. & Zipp, F. Multiple sclerosis — candidate mechanisms underlying CNS atrophy. *Trends Neurosci.* **33**, 202–210 (2010).
 73. Matute, C. Glutamate and ATP signalling in white matter pathology. *J. Anat.* **219**, 53–64 (2011).
 74. Trapp, B. D. & Stys, P. K. Virtual hypoxia and chronic necrosis of demyelinated axons in multiple sclerosis. *Lancet Neurol.* **8**, 280–291 (2009).
 75. Mahad, D. J. *et al.* Mitochondrial changes within axons in multiple sclerosis. *Brain* **132**, 1161–1174 (2009).
 76. Young, E. A. *et al.* Imaging correlates of decreased axonal Na⁺/K⁺ ATPase in chronic multiple sclerosis lesions. *Ann. Neurol.* **63**, 428–435 (2008).
 77. Stys, P. K. Axonal degeneration in MS: is it time for neuroprotective strategies? *Ann. Neurol.* **55**, 601–603 (2004).
 78. Court, F. A., Hendriks, W. T., Macgillivray, H. D., Alvarez, J. & van Minnen, J. Schwann cell to axon transfer of ribosomes: toward a novel understanding of the role of glia in the nervous system. *J. Neurosci.* **28**, 11024–11029 (2008).
 79. Lublin, F. D. & Reingold, S. C. Defining the clinical course of multiple sclerosis: results of an international survey. National Multiple Sclerosis Society (USA) Advisory Committee on Clinical Trials of New Agents in Multiple Sclerosis. *Neurology* **46**, 907–911 (1996).
 80. Miller, D. H. & Leary, S. M. Primary-progressive multiple sclerosis. *Lancet Neurol.* **6**, 903–912 (2007).
 81. Confavreux, C. & Vukusic, S. Accumulation of irreversible disability in multiple sclerosis: from epidemiology to treatment. *Clin. Neurol. Neurosurg.* **108**, 327–332 (2006).
 82. Stüve, O. & Oksenberg, J. Multiple sclerosis overview [updated 11 May 2010]. In *GeneReviews* (eds Pagon R. A. *et al.*) (University of Washington, Seattle, 1993).
 83. Akiyama, H. *et al.* Inflammation and Alzheimer's disease. *Neurobiol. Aging* **21**, 383–421 (2000).
 84. Whitton, P. S. Inflammation as a causative factor in the aetiology of Parkinson's disease. *Br. J. Pharmacol.* **150**, 963–976 (2007).
 85. Langston, J. W. *et al.* Evidence of active nerve cell degeneration in the substantia nigra of humans years after 1-methyl-4-phenyl-1,2,3,6-tetrahydropyridine exposure. *Ann. Neurol.* **46**, 598–605 (1999).
 86. McGeer, P. L. & McGeer, E. G. Inflammation and neurodegeneration in Parkinson's disease. *Parkinsonism Relat. Disord.* **10** (Suppl. 1), 3–7 (2004).
 87. Pawelec, G., Larbi, A. & Derhovanessian, E. Senescence of the human immune system. *J. Comp. Pathol.* **142** (Suppl. 1), 39–44 (2010).
 88. Agrawal, S. M. & Yong, V. W. Immunopathogenesis of multiple sclerosis. *Int. Rev. Neurobiol.* **79**, 99–126 (2007).

Acknowledgements

The authors thank C. Polman for critical reading of the manuscript. Work in the authors' laboratories is supported by the MS Society of Canada, Canadian Institutes of Health Research, Alberta Innovates — Health Solutions, Canada Research Chairs and the Dutch MS Research Foundation.

Competing interests statement

The authors declare no competing financial interests.

FURTHER INFORMATION

Peter K. Stys's homepage:
<http://hbi.ucalgary.ca/members/stys>

ALL LINKS ARE ACTIVE IN THE ONLINE PDF

ERRATUM

Will the real multiple sclerosis please stand up?

Peter K. Stys, Gerald W. Zamponi, Jan van Minnen and Jeroen J. G. Geurts

Nature Reviews Neuroscience **13**, 507–514 (2012)

On page 508 of this article, “alemtuzumab (a monoclonal antibody directed against CD25 (also known as interleukin-2 receptor subunit- α), which is expressed on leukocytes)” should have read “alemtuzumab (a monoclonal antibody directed against CD52, which is expressed on lymphocytes)”. This has been corrected in the online version.