

# Wound healing activity of the leaf extracts and deoxyelephantopin isolated from *Elephantopus scaber* Linn.

S. D. J. Singh, V. Krishna<sup>1</sup>, K. L. Mankani, B. K. Manjunatha<sup>2</sup>, S. M. Vidya<sup>2</sup>, Y. N. Manohara

Department of  
Pharmacognosy, National  
College of Pharmacy,  
Shimoga, Karnataka,  
<sup>1</sup>Department of P.G. Studies  
and Research in  
Biotechnology, Kuvempu  
University, Shankaraghatta-  
577 451, Karnataka and  
<sup>2</sup>Department of Botany,  
S.R.N.M. College of Applied  
Sciences, Shimoga, Karnataka.

Received: 8.10.2004

Revised: 4.1.2005

Accepted: 13.2.2005

Correspondence to:

V. Krishna

E-mail:

krishnabiotech2003@yahoo.co.in

**Objective:** To evaluate the wound healing activity of the leaf extracts and deoxyelephantopin isolated from *Elephantopus scaber* Linn.

**Materials and Methods:** The effect of aqueous ethanol extracts and the isolated compound deoxyelephantopin from *E. scaber* Linn. (Asteraceae) was evaluated on excision, incision, and dead space wound models in rats. The wound-healing activity was assessed by the rate of wound contraction, period of epithelialization, skin-breaking strength, weight of the granulation tissue, and collagen content. Histological study of the granulation tissue was carried out to know the extent of collagen formation in the wound tissue.

**Results:** The ethanol extract and the isolated constituent deoxyelephantopin of *E. scaber* promoted wound-healing activity in all the three wound models. Significant ( $P < 0.01$ ) increase in the rate of wound contraction on day 16 (98.8%,  $P < 0.01$ ), skin-breaking strength (412 g,  $P < 0.01$ ), and weight of the granulation tissue on day 10 (74 mg/100 g,  $P < 0.01$ ) were observed with deoxyelephantopin-treated animals. In ethanol extract-treated animals, the rate of wound contraction on day 16, skin-breaking strength, and weight of the granulation tissue on day 10 ( $P < 0.01$ ) were 92.4%, 380 g, and 61.67 mg/100 g, respectively. Histological studies of the granulation tissue also evidenced the healing process by the presence of a lesser number of chronic inflammatory cells, lesser edema, and increased collagenation than the control.

**Conclusion:** The wound-healing activity was more significant in deoxyelephantopin-treated animals.

**KEY WORDS:** Elephant's foot, wound models.

## Introduction

*Elephantopus scaber* Linn. (Asteraceae) is a scabrescent aromatic herb distributed in the moist deciduous forests of the central Western Ghats. The plant is popularly known as Elephant's foot (English), Gojivha (Sanskrit), Eddumalikechettu (Telugu), and Nayi nalige (Kannada). In the Indian system of medicine, the medicinal attribution of this species has been known for a long time. As per the traditional claims, the roots were used as an antipyretic, cardiogenic, and diuretic.<sup>[1]</sup> Decoction of the roots and leaves is used as emollient and given in dysuria, diarrhea, dysentery, and in stomach pain.<sup>[2]</sup> The aqueous extract of leaves is applied externally to treat eczema and ulcers.<sup>[3]</sup> The whole plant is macerated and applied on the wound surface<sup>[4]</sup> to promote wound healing.

Phytochemically the plant has been reported to contain sesquiterpene lactones deoxyelephantopin, isodeoxyelephantopin, and scabertopin.<sup>[5]</sup> It also contains epifriedelinol,

lupeol, and stigmasterol.<sup>[6]</sup> The pharmacological properties of the leaf extracts have been evaluated for diuretic,<sup>[7]</sup> antiinflammatory,<sup>[8]</sup> and hepatoprotective properties.<sup>[9]</sup> Many sesquiterpene lactones isolated from the Asteraceae members possess antibacterial properties and were used for treating wounds and ulcers.<sup>[10]</sup> The constituent deoxyelephantopin possesses alpha-methylene gamma lactone moiety, which has an antiulcerogenic activity.<sup>[11]</sup> The wound-healing properties of this Asteraceae member has not been scientifically evaluated so far. Hence, the present work was undertaken to evaluate the effect of aqueous, ethanol extracts of *E. scaber* and the isolated compound deoxyelephantopin on excision, incision and dead space wound models in rats.

## Materials and Methods

### Extraction of active constituent

The aerial parts of *E. scaber* were collected from the Joldhal forest ranges of the Western Ghats, Karnataka. The taxonomic

identity was confirmed by comparing with the authenticated herbarium specimen (FDD No. 49) at Kuvempu University Herbaria,<sup>[12]</sup> Shankaraghatta, Karnataka.

The material was shade dried, powdered mechanically, and sieved by using a mesh (size no. 10/44). In the preparation of aqueous extract, 500 g of powdered material was pulverized and extracted with 1/10 w/v of distilled water. The decoction was filtered and the water content was removed under reduced pressure using a rotary flash evaporator, the yield was 5%.

For ethanol extract, powdered material was refluxed with 95% ethyl alcohol in a soxhlet apparatus (Perfit, Mumbai) for 24 h in different batches of 250 g each. The resulting extract was filtered, pooled, and the solvent removed under reduced pressure at 40±5 °C using a rotary flash evaporator.

Isolation of deoxyelephantopin was carried out according to the method of Paul Pui-Hay But *et al.*<sup>[5]</sup> The residue obtained from the ethanol extract was partitioned between water and chloroform (1:2). The chloroform layer was separated and concentrated on a water bath to obtain dark green syrup. The chloroform extract was then partitioned between hexane and 10% aqueous methanol (2:1). The lower, aqueous methanol extract was separated and repeatedly washed with hexane three to four times and was evaporated to dryness. The residue was chromatographed on a silica gel column and eluted successively using hexane and ethyl acetate in varying ratios of 1:1, 1:2 and 1:4. The eluted fractions were collected at intervals of 5 ml each and were monitored by thin layer chromatography and grouped into seven fractions. Fraction seven was recrystallized from chloroform–hexane to get a compound of fine needle crystals. The chemical identity of the compound was ascertained by analytical and spectroscopic methods.<sup>[5]</sup>

#### Drug formulations

Two types of drug formulations were prepared from each of the extracts and the isolated compound. For topical administration, 5 g each of the aqueous and ethanol extracts were separately incorporated with 100 g of 2% sodium alginate to get 5% w/w gel. Similarly, 100 mg of deoxyelephantopin was incorporated with 50 g of 2% sodium alginate (w/w) to get a 0.2% gel.

For oral administration, suspensions of 30 mg/ml of each of the aqueous and ethanol extracts and 4 mg/ml of the isolated compound deoxyelephantopin were incorporated with 1% w/v gum tragacanth. The drug formulations were prepared every fourth day. The drugs were administered orally by a feeding tube.

#### Animals

Swiss Wistar strain rats of either sex weighing 150–200 g were procured from the central animal house, National College of Pharmacy, Shimoga, Karnataka and were maintained at standard housing conditions. The animals were fed with a commercial diet (Hindustan Lever Ltd., Bangalore) and water *ad libitum* during the experiment. The Institutional Ethical Committee (Reg. No. 144/1999/CPCSEA/SMG) permitted the study.

The 'staircase' method<sup>[13]</sup> was adopted for the determination of acute toxicity. Healthy albino mice of either sex weighing 20–25 g of 90 days were used to determine the safer dose. Gum tragacanth (1% w/v) was used as a vehicle to

suspend the various extracts and the isolated constituent. The extracts and constituent were administered orally.

#### Evaluation of wound healing activity

For the assessment of the wound-healing activity, excision, incision, and dead space wound models were used.

Five groups, each containing six animals, were used for each of the excision and incision wound models. Fifty milligrams of the formulated drugs was applied topically for each animal once a day. The Group I animals were considered as control and were treated by topical applications of the vehicle, 2% w/w tragacanth. The Group II animals served as reference standard and were treated with 0.2% w/w nitrofurazone<sup>[14]</sup> ointment. The Groups III and IV animals were treated with aqueous and ethanol extracts, respectively. The Group V animals were treated by topical application of the isolated compound deoxyelephantopin.

For dead space model, the test groups were administered the aqueous/ethanol extract (300 mg/kg, b.w.) or the compound deoxyelephantopin (4 mg/kg, b.w.). Reference standard was not tested.

The animals were anesthetized as described by Morton and Malone<sup>[15]</sup> under light ether anesthesia. The skin of the impressed area was excised to full thickness to obtain a wound area of about 500 mm<sup>2</sup>. The drugs were topically applied once a day till complete epithelialization, starting from the day of the operation. The parameters studied were wound closure (wound closure was measured at regular intervals of time to see the percentage of wound closure) and epithelization time (the epithelization time indicates the formation of new epithelial tissue to cover the wound). The percentage of wound closure was recorded on days 4, 8, 12, and 16 postwounding and on alternate days till complete re-epithelialization.

In the incision model,<sup>[16]</sup> the rats were anesthetized by anesthetic ether and two longitudinal paravertebral incisions of 6 cm length were made through the skin and cutaneous muscle at a distance of about 1.5 cm from the midline on each side of the depilated back. After the incision, the parted skin was sutured 1 cm apart using a surgical thread (No. 000) and curved needle (No. 11). The wounds were left undressed. The drugs were topically applied to the wound once a day, till complete healing. The sutures were removed on eighth postwound day. The skin-breaking strength of the 10-day-old wounds was measured by the method of Lee.<sup>[17]</sup>

Dead space wounds were created under light ether anesthesia, by subcutaneous implantation of sterilized cylindrical grass piths (2.5 x 0.3 cm) in the region of the groin, on both sides. The granulation tissues formed around the grass pith were harvested on the tenth day postwounding and subjected to breaking strength and histological study.

For histological studies, granulation tissues were fixed in 10% neutral formalin solution for 24 h and dehydrated with a sequence of ethanol–xylene series of solutions.<sup>[18]</sup> The materials were infiltrated and embedded with paraffin (40–60 °C). Microtome sections were taken at 10 μ thickness. The sections were processed in alcohol–xylene series and stained with hemotoxylin–eosin dye. The histological changes were observed under a microscope.

The results of these experiments are expressed as mean±SEM of six animals in each group. The data were

**Table 1****Effect of topical application of different extracts of *E. scaber* on excision wound model**

| Treatment            | Percentage of closure of excision wound area<br>(original wound area 500 mm <sup>2</sup> ) |             |               |               | Epithelialization<br>in days |       |
|----------------------|--|-------------|---------------|---------------|------------------------------|-------|
|                      | Day 4  | Day 8       | Day 12        | Day 16        |                              |       |
| Control              | 20.8±0.34  | 57.23±0.67  | 67.4 ± 0.52   | 85.8 ± 0.69   | 20.0 ± 0.86                  |       |
| Nitrofurazone (0.2%) | 36.0±0.52**  | 78.8±0.39** | 92.0 ± 0.61** | 100.0**       | 15.0 ± 0.26**                |       |
| Aqueous extract      | 23.0±0.45  | 60.2±0.82*  | 75.7 ± 0.52** | 89.8 ± 0.60** | 17.8 ± 0.31*                 |       |
| Ethanol extract      | 30.4±0.59**  | 70.6±0.47** | 84.8 ± 0.42** | 92.4 ± 0.64** | 16.6 ± 0.33**                |       |
| Deoxyelephantopin    | 35.2±0.73**  | 76.5±0.54** | 90.6 ± 0.54** | 98.8 ± 0.35** | 14.0 ± 0.26**                |       |
| One-way              | F  | 167.8       | 258.0         | 330.4         | 131.7                        | 26.1  |
| ANOVA                | P  | <0.01       | <0.01         | <0.01         | <0.01                        | <0.01 |

Values are mean ± SE; n = 6 in each group. df = 4, 25; \*P < 0.05, \*\*P < 0.01 as compared to control.

statistically evaluated by one-way ANOVA followed by Tukey's pair-wise comparison test. The values of P < 0.01 were considered as statistically significant.

## Results

The Sesquiterpene lactone isolated from *E. scaber* showed the following spectral characteristics. The melting point of the compound is 199°C. It showed absorption at UV λ<sub>Max</sub> 207.0 nm. The IR (KBr) spectrum of the compound showed peaks at 1765.30, 1746.00, 1654.00, 1642.10, and 1163.30 cm<sup>-1</sup>. In mass spectral analysis, molecular ion peak was observed at m/z: 345 [M+H]<sup>+</sup>, indicating the molecular weight of the compound.

Based on the data, the molecular formula of the compound was found to be C<sub>19</sub>H<sub>20</sub>O<sub>6</sub> and identified as deoxyelephantopin [Figure 1] similar to the report of Paul Pui-Hay But *et al.*<sup>[5]</sup>

Toxicity studies revealed that the maximum tolerated dose for the aqueous and ethanol extracts of *E. scaber* was 3 g/kg, b.w. and for the isolated compound deoxyelephantopin it was 40 mg/kg, b.w. Therefore, 1/10 of these doses (300 mg/kg, b.w. of aqueous or ethanol extract and 4 mg/kg, b.w. of the compound) were selected for the topical evaluation of wound-healing efficacy.

In all the models studied, significant wound-healing activity was observed with deoxyelephantopin comparable to that of the reference standard nitrofurazone. In both these groups, percentage closure of excision wound area was 98.8±0.35 and 100, respectively. Complete epithelialization was noticed on the 14th day as shown in Table 1. In ethanol-treated animals, the percentage of wound closure was 92.4±0.64, while in aqueous extract it was reduced to 89.8±0.60 and the period of complete epithelialization was delayed by three days.

In the incision wound model the animals treated with the topical application of aqueous and ethanol extracts have shown more or less same skin-breaking strength (346.0±6.51 and 380.0±8.56). In deoxyelephantopin-treated animals skin-breaking strength was significantly increased to 412.0±11.37 and it was less in control animals (298.6±8.48) as depicted in the Table 2.

In dead space wound model also significant increase in weight of the granulation tissue (74.0±1.29), and breaking

**Table 2****Effect of topical application of different extracts of *E. scaber* on incision wound model**

| Group (n)                    | Breaking strength (g) |      |
|------------------------------|-----------------------|------|
| Control                      | 298.6 ± 8.48          |      |
| Nitrofurazone (0.2% w/w)     | 420.0 ± 6.35**        |      |
| Aqueous extract (5% w/w)     | 346.0 ± 6.51**        |      |
| Ethanol extract (5% w/w)     | 380.0 ± 8.56**        |      |
| Deoxyelephantopin (0.2% w/w) | 412.0 ± 11.37**       |      |
| One-way                      | F                     | 35.2 |
| ANOVA                        | P                     | <0.0 |

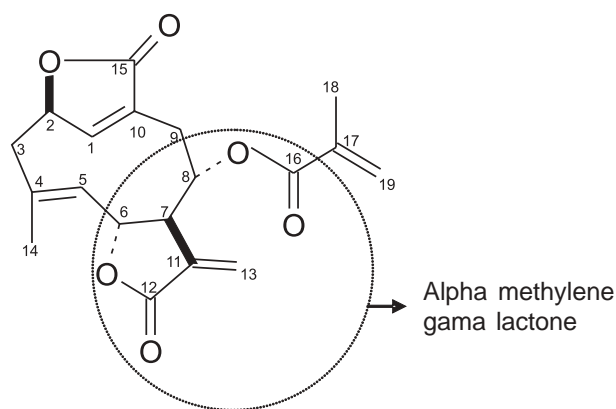
Values are mean±SEM; n = 6 in each group. df = 4, 25. \*P < 0.05, \*\*P < 0.01 as compared to control.

**Table 3****Effect of oral administration of different extracts of *E. scaber* on dead space wound model**

| Treatment         | Granulation tissue dry weight (mg/100 g) | Breaking strength (g) |
|-------------------|--|-----------------------|
| Control           | 42.33±2.28                               | 320.0±9.31            |
| Aqueous extract   | 56.00±2.37**                             | 364.0±7.57**          |
| Ethanol extract   | 61.67±1.89**                             | 398.0±6.00**          |
| Deoxyelephantopin | 74.00±1.29**                             | 437.0±4.46**          |
| One-way           | F  | 54.9                  |
| ANOVA             | P  | <0.01                 |

Values are mean±SEM; n = 6 in each group. df = 4, 25. \*P < 0.05, \*\*P < 0.01 as compared to control.

strength (437.0±4.46) was observed in the animals treated with deoxyelephantopin [Table 3]. The histological profiles of granulation tissue of control animals [Figure 2a] showed more macrophages and less collagenation. The sections of granulation tissue of ethanol extract and the deoxyelephantopin-treated animals showed the sign of tissue repair with increased

**Figure 1.** Structure of deoxyelephantopin

collagen formation [Figure 2b and 2c] and less macrophages. Whereas, in the aqueous extract-treated animals the healing activity was comparatively lesser with moderate collagenation and retention of the macrophages.

### Discussion

Wound healing is a process by which a damaged tissue is restored as closely as possible to its normal state and wound contraction is the process of shrinkage of area of the wound. It depends upon the reparative abilities of the tissue, type and extent of the damage and general state of the health of the tissue. The granulation tissue of the wound is primarily composed of fibroblast, collagen, edema, and small new blood vessels. The undifferentiated mesenchymal cells of the wound margin modulate themselves into fibroblast, which start migrating into the wound gap along with the fibrin strands. The collagen is the major component of extra cellular tissue, which gives support and strength and is composed of amino acid (Hydroxyproline).

In the present investigation the ethanol extract and the isolated constituent sesquiterpene lactone – deoxyelephantopin promotes significant wound-healing activity by increasing cellular proliferation, formation of granulation tissue, synthesis of collagen and by increase in the rate of wound contraction as compared to the control animals. The earlier investigators reported the antibacterial,<sup>[19]</sup> antifungal,<sup>[20]</sup> and antioxidant<sup>[21]</sup> properties of related sesquiterpene lactones isolated from Asteraceae members. It was also reported that, the compounds possessing alpha methylene lactone in their structure (Asteraceae) were used to treat wounds and ulcers.<sup>[10]</sup> The wound-healing property of deoxyelephantopin may be due to the presence of active moiety, alpha methylene gamma lactone.

Similar types of wound-healing activity were reported on *Merremia tridentate*,<sup>[22]</sup> *Diospyros cordifolia*,<sup>[23]</sup> and *Bryophyllum pinnatum*.<sup>[24]</sup> The results of this investigation provide pharmacological evidence on the folkloric use of *E. scaber* for wound healing.

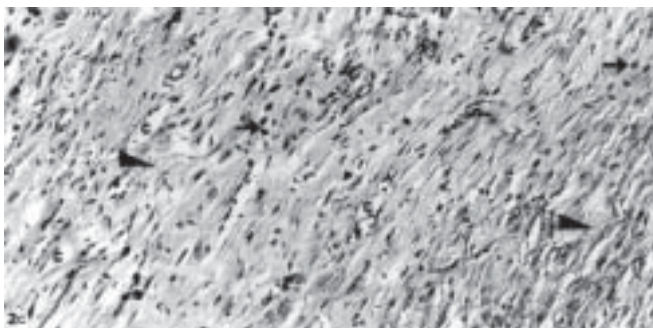
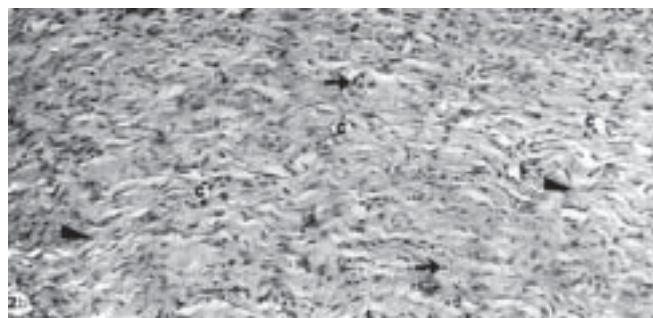
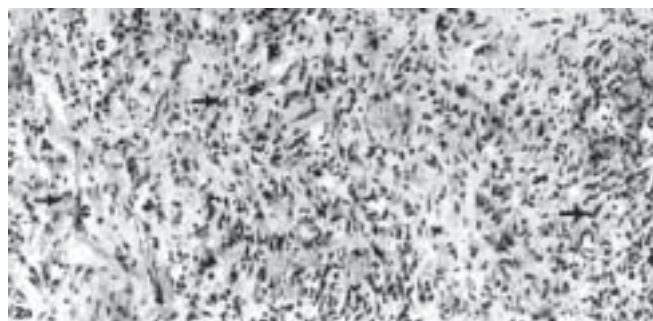
### Acknowledgments

The authors are very thankful to National Education Society, Shimoga and Prof. B.

**Figure 2. (a)** Section of granulation tissue of control animal showing macrophages (arrows), capillaries (c), and collagenation, which is not significant (H&E, 100x).

**(b)** Section of granulation tissue of ethanol extract-treated animals showing moderate collagenation (arrowheads) with less monocytes and fibroblasts (arrows), and capillaries (c) (H&E, 100x).

**(c)** Section of granulation tissue of deoxyelephantopin-treated animal showing significant collagenation (arrowheads), lesser fibroblasts (arrows), and capillaries (c) (H&E, 100x)



Abdul Rahiman, Department of Biotechnology, Kuvempu University for their encouragement and providing facilities to carryout this work.

### References

1. Nadakarni AK. Indian Materia Medica. Mumbai: Dhootapapeshwar Prakashan Ltd.; 1954.
2. Kirtikar KR, Basu BD. Indian Medicinal Plants. Delhi: Periodical Experts Book Agency; 1991.
3. Chopra RN, Nayar SL, Chopra IC. Glossary of Indian Medicinal Plants. Delhi: CSIR; 1956.
4. Vaidya BG. Nighantu Adarsha. Varanasi: Chackhamba Bharathi Academi; 1999.
5. Paul Pui-Hay But, Po-Ming Hon, Hui Cao, TW.Dominic Chan, Bo-Mu Wu, Thomas CW.Mak, Chun-Tao Che. Sesquiterpene lactones from *Elephantopus scaber*. Phytochem 1997;44:113.
6. De-Silva LB, Herath WHMW, Jennings RC, Mahendran M, Wannigamma GE.

- A new sesquiterpene lactone from *Elephantopus scaber*. *Phytochem* 1982;21:1173.
- Poli A, Nicolan M, Simoes CM, Nicolan RM, Zanin M. Preliminary pharmacological evaluation of crude whole plant extracts of *Elephantopus scaber*. Part I: *In vivo* studies. *J Ethnopharmacol* 1992;37:71-6.
  - Tsai CC, Lin CC. Anti inflammatory effects of Taiwan folk medicine 'Teng Khia U' on carrageenan and adjuvant induced paw edema in rats. *J Ethnopharmacol* 1999;64:85-9.
  - Lin CC, Tsai CC, Yen MH. The evaluation of Hepatoprotective effects of Taiwan folk medicine 'Teng Khia U'. *J Ethnopharmacol* 1995;45:113-23.
  - Jean Bruneton. *Pharmacognosy and Phytochemistry*. New York: Intercept Ltd; 1999.
  - Giordano OS, Guerreiro E, Pestchanker MJ, Guzman J, Pas D, Guardia T. The gastric cytoprotective effect of several sesquiterpene lactones. *J Nat Prod* 1990;53:803-9.
  - Manjunatha BK, Krishna V, Pullaiah T. *Flora of Davanagare District*. Karnataka. New Delhi: Regency Publications; 2003.
  - Ghosh MN. *Fundamentals of Experimental Pharmacology*. Kolkata: Scientific Book Agency; 1984.
  - Mukherjee PK. *Quality control Herbal Drugs*. New Delhi: Business Horizons; 2002.
  - Morton JJP, Malone MH. Evaluation of vulnery activity of open wound procedure in rats. *Arch Int Pharmacodyn Ther* 1972;196:117-26.
  - Ehrlich HP, Hunt TK. The effect of cortisone and anabolic steroids on the tensile strength of healing wounds. *Ann Surg* 1968;167:117.
  - Lee KH. Studies on the mechanism of action of salicylate retardation of wound healing by aspirin. *J Pharmaceut Sci* 1968;57:1042.
  - Kanai L Mukherjee. *Medical laboratory Technology*. New Delhi: Tata McGraw-Hill Ltd.; New Delhi 2000.
  - Fischer NH, Lu T, Cantrell CL, Castaneda Acoata J, Quijano L, Franzblau SG. Antimycobacterial evaluation of germacranolides. *Phytochemistry* 1998;49:559-64.
  - Barrero AF, Oltra JE, Alvarez M, Raslan DS, Saude DA, Akssira M. New sources and anti fungal activity of sesquiterpene lactones. *Fitoterapia* 2000;71:60-4.
  - Rekka EA, Angeliki P. Investigation of the effect of chamazulene on lipid peroxidation and free radical processes. *Res Comm Mol Pathol Pharmacol* 1966;92:361.
  - Hatapakki BC, Hukkeri V, Patil DN, Chavan MJ. Wound healing activity of aerial parts of *Merremia tridentata*. *Indian Drugs* 2004;41:532.
  - Mankani KL, Krishna V, Singh JSD, Manjunath BK, Vidya SM, Manohara YN. Evaluation of wound healing activity of the stem bark of *Diospyros cordifolia*. *Indian Drugs* 2004;41:628.
  - Khan M, Patil PA, Shobha JC. Influence of *Bryophyllum pinnatum* leaf extract on wound healing in albino rats. *J Natural Remedies* 2004;4:41.

## XXXVIII Annual Conference of the Indian Pharmacological Society



**December 28 - 30 2005**  
**IMAGE Auditorium, Chennai**

**Quiz IPS 38 for Pharmacology Postgraduates - Register as a team of three - No registration fee - Registration by e-mail or post.**

*For further information please contact:*

**Dr. C. B. Tharani**  
Institute of Pharmacology,  
Madras Medical College, Chennai.  
E-mail: [ips\\_38con@yahoo.co.in](mailto:ips_38con@yahoo.co.in)  
Website: [ips38chennai.com](http://ips38chennai.com)