

## Wound Healing Potential of *Phyllanthus niruri* Leaf Extract in Experimental Rats

<sup>1</sup>Khaled Abdul-Aziz Ahmed, <sup>2</sup>Mahmood Ameen Abdulla and <sup>3</sup>Fahmi Mustafa Mahmoud

<sup>1</sup>Department of Medical Sciences, Faculty of Dentistry, Ibb University, P.O. Box 70627, Ibb, Yemen

<sup>2</sup>Department of Molecular Medicine, Faculty of Medicine,  
University of Malaya, 50603 Kuala Lumpur, Malaysia

<sup>3</sup>Division of Basic Medical Sciences, Faculty of Medicine,  
Cyberjaya University College of Medical Sciences,  
Cyber 4, 63000 Cyberjaya, Selangor Darul Ehsan, Malaysia

**Abstract:** The study aims to study the wound healing activity of *Phyllanthus niruri* leaves extract in rats. Five groups of adult male *Sprague Dawley* rats were experimentally wounded in the posterior neck area. Group 1 animals were treated with sterile deionized water (negative control). Thin layer of blank placebo was applied topically to Group 2 rats. Groups 3 and 4 rats were dressed topically with thin layer of placebo containing 5% and 10% *P. niruri* extract, respectively. Intrasite gel was used as a positive control. Grossly, wounds treated with placebo containing 5%, 10% *P. niruri* extract or Intrasite gel significantly accelerated the rate of wound healing compared to wounds treated with sterile deionized water or dressed with blank placebo. Histological analysis of healed wounds confirmed the gross observations. Wounds dressed with placebo containing 5%, 10% *P. niruri* extracts or Intrasite gel showed markedly less scar width at the wound enclosure with large amounts of fibroblasts proliferation, more mature and densely packed collagen and angiogenesis compared to wounds dressed with sterile deionized water or blank placebo. These results strongly document the beneficial and significant effects of plant extract for the acceleration of wound healing enclosure in rats.

**Key words:** *Phyllanthus niruri* % Wound Healing % Intrasite Gel % Histology

### INTRODUCTION

*Phyllanthus niruri* (Euphorbiaceae) is a small herb distributed throughout the tropical and subtropical regions of both hemispheres. This plant is a popular in folk medicine, whole plant, fresh leaves and fruits are used to treat various ailments, particularly hepatitis and other viral infection [1, 2]. The plant is of medicinal importance for numerous ailments like dysentery, influenza, vaginitis, tumors, diabetes, diuretics, jaundice, kidney stone, dyspepsia, antihepatotoxic, antihepatitis-B, antihyperglycemic and also as antiviral and antibacterial [1].

*P. niruri* extract has been shown to inhibit DNA polymerase of hepatitis B virus and related hepatitis viruses [3]. Other medicinal properties such as hypolipidemic [4], gastroprotective effect [5], antioxidant and hepatoprotective potential [6], antitumor and anticarcinogenic activities [7], antinociceptive and

antispasmodic activities and inhibition of calcium oxalate formation in kidney [8, 9]. There were no reports regarding the wound healing effect of *P. niruri*, which encouraged us to evaluate the wound healing potential of this plant extract in rats.

### MATERIALS AND METHODS

**Placebo and Intrasite Gel:** An aqueous cream placebo was obtained from Department of Pharmacy, Faculty of Medicine, University of Malaya (Sunward Pharmaceutical SDN BHD. MAL 19920890X). Intrasite gel was purchased from University of Malaya Medical Centre Pharmacy. Intrasite gel is a colorless transparent aqueous gel which contains a modified carboxymethylcellulose (CMC) polymer together with propylene glycol as a mumentant and preservative. Intrasite gel is an amorphous hydrogel which gently re-hydrates necrotic tissue and facilitates autolytic debridement while loosening and absorbing

slough and exudates, clearing the way for effective wound healing. It is also designed for wounds that are granulating and epithelializing. It can also be used to provide the optimum moist wound management environment during the later stages of wound closure. It is non-adherent and does not harm viable tissue or the skin surrounding the wound. This makes the use of Intrasite gel ideal for every stage in the wound management process. (Intrasite gel is a trademark for Smith and Nephew Ltd).

**Lignocaine HCl (2%, 100 mg/5 ml):** Lignocaine is a local anesthesia and was purchased from the Experimental Animal House, Faculty of Medicine, University of Malaya (Delta Veterinary Laboratory PTY LTD, NSW 20011). 1 ml of Lignocaine was injected subcutaneously.

**Collection and Preparation of Plant Extract:** The fresh leaves were collected from different areas of Malaysia and identified by comparison with specimens available at the Herbarium of the Forest Research Institute, Kepong, Malaysia. Voucher specimens of the plant material are deposited at Department of Pharmacy, University of Malaya, Malaysia.

**Preparation of Plant Extracts:** Fresh leaves of this plant were cut, labeled, wash with distilled water and dried in oven at 50°C for 5-7 days until fully dried. The Leaves were ground to a fine texture form using a grinder and then 50 g of blended plant were weighted and placed into 1000 ml flask. The distilled water was added in ratio 1:20. After that, it was heated, stirred on hotplate for 3 hours and filtered using filter paper and filter funnel. These steps were followed by rotator evaporation to remove the water. Aqueous extract was then submitted to lyophilization by a freeze-dryer, to produce powdered forms of the extract. The freeze-dried products were mixed homogeneously with blank placebo in concentrations of 5% and 10% (w/w).

**Experimentally-induced Wounds:** *Sprague Dawley* adult male rats were obtained from the experimental animal house, Faculty of Medicine, University of Malaya. The procedures involving animals and their care conformed to the international guideline, Principles of Laboratory Animals Care. The experimental protocol for animal work was approved by the local ethics committee for animal experimentation in the Faculty of Medicine, University of Malaya, Ethic No. PM 28/-9/2007 MAA (R). The rats were divided randomly into 5 groups of 6 rats each. Each rat

that weighed between 200 - 230 g was housed separately (one rat per cage). The animals were maintained on standard pellet diet and tap water. The animals were firstly anaesthetized with diethyl ether. The skin of the posterior neck region was shaved with an electrical shaver, disinfected with 70% alcohol and injected with 1 ml of Lignocaine HCl (2%, 100 mg/5 ml). A uniform wound area of 2.00 cm in diameter was excised from the nape of the dorsal neck of all rats aseptically with the aid of round seal as previously described by Suguna *et al.* [10] with slight modifications as shown in Figure 1A. Incision of the muscle layer was avoided by keeping the tension of skin constant during the procedure.

**Topical Application of Vehicles:** Wounds of Group 1 rats were treated twice daily with sterile deionized water as negative control. Group 2 rats were dressed with a thin layer of blank placebo twice daily. Groups 3 and 4 animals were treated topically with a thin layer of placebo containing 5% and 10% plant extract twice daily; respectively. A thin layer of commercial Intrasite gel was topically applied twice daily to wounds of Group 5 rats as reference. The wounds were observed daily until complete wound healing occurs.

**Histological Evaluation of Healed Wounds:** Specimens of skin from healed wounds from each rat were fixed in 10% buffered formalin solution for histopathological studies. Sections of the healed skin were made at a thickness of 5µm, stained with hematoxylin and eosin (H & E) and assessed for histopathological changes.

**Statistical Analysis:** All results were expressed as mean ± SEM. The statistical significance of differences among groups in term of rate of wound healing were evaluated using one-way analysis of variance (ANOVA). A value of  $p < 0.05$  was considered significant. Statistical computations were calculated using SPSS 16 for Windows software (SPSS Inc, Chicago, IL).

## RESULTS

**Wound Healing Activity:** Wounds dressed with either aqueous extracts of *P. niruri* leaves or with Intrasite gel showed considerable signs of dermal healing and significantly ( $p < 0.05$ ) healed earlier than wounds dressed with sterile deionized water or blank placebo (Table 1; Figures 1B and C). There were no significant differences between wounds dressed with 5%, 10% *P. niruri* extract or Intrasite gel in terms of rate of wound healing enclosure

Table 1: Time required for wound healing by *P. niruri* in experimental animals

Animal groups	No of animals	Type of dressings	Healing time (days) (Mean $\pm$ S.E.M)
Group 1	6	Sterile deionized water (negative control)	20.33 $\pm$ 0.33 <sup>a</sup>
Group 2	6	Blank placebo	19.17 $\pm$ 0.31 <sup>a</sup>
Group 3	6	Placebo containing 5% <i>P. niruri</i>	13.00 $\pm$ 0.37 <sup>b</sup>
Group 4	6	Placebo containing 10% <i>P. niruri</i>	12.67 $\pm$ 0.33 <sup>b</sup>
Group 5	6	Intrasite gel (positive control)	12.33 $\pm$ 0.21 <sup>b</sup>

All values were expressed as mean  $\pm$  SEM. Mean values with different superscripts were significantly different ( $p < 0.05$ )

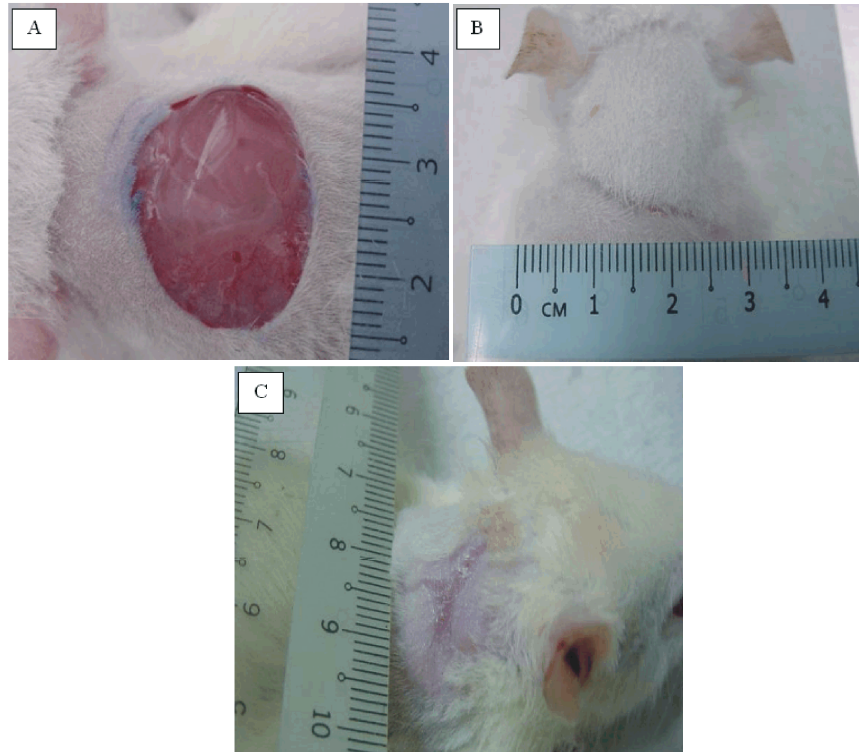


Fig. 1: Macroscopically appearance of wounds in different treatments and time intervals. (A) 2.0 cm diameter excision skin wound on day 0 before application of vehicle. (B) Wound healing dressed with placebo containing 10% *P. niruri* extract on day 12. (C) Wound healing dressed with blank placebo on day 19.

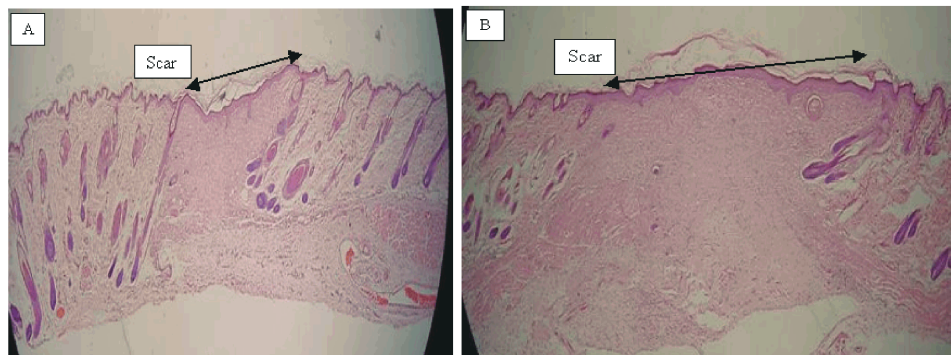


Fig. 2: Histological sections of healed wounds. (A) Wound dressed with placebo containing 10% *P. niruri* showing narrow scar at the wound closure. (B) Wound healing dressed with blank placebo showing wide scar at the wound closure (H & E stain, 20x magnification).

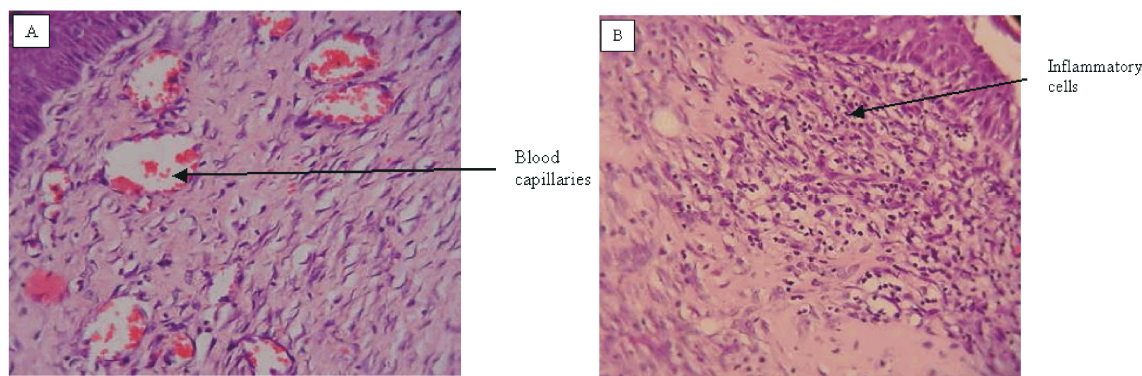


Fig. 3: Histological sections of healed wounds. (A) Wound dressed with placebo containing 10% *P. niruri* extract showing granulation tissue with more collagen, fibroblasts and blood capillaries and absence of inflammatory cells. (B) Section of healed wound dressed with blank placebo. Granulation tissue contains less collagen, fibroblasts and blood capillaries and more inflammatory cells as indicated by an arrow (H & E stain, 80x magnification).

(Table 1). Histologically, wounds dressed with aqueous extracts of *P. niruri* leaves or Intrasite gel contained markedly fewer inflammatory cells, less scarring at the wound enclosure, more proliferating blood capillaries (angiogenesis) and more collagen fibres compared to wounds dressed with sterile deionized water or blank placebo (Figures 2 and 3).

## DISCUSSION

Wound healing is a complex and dynamic process of restoring cellular structures and tissue layers in damaged tissue as closely as possible to its normal state. Wound contracture is a process that occurs throughout the healing process, commencing in the fibroblastic stage whereby the area of the wound undergoes shrinkage. It has 3 phases, inflammatory, proliferative and maturational and is dependent upon the type and extent of damage, the general state of the host's health and the ability of the tissue to repair. The inflammatory phase is characterized by hemostasis and inflammation, followed by epithelialization, angiogenesis and collagen deposition in the proliferative phase. In the maturational phase, the wound undergoes contracture resulting in a smaller amount of apparent scar tissue.

The present study shows that topical application of *P. niruri* extracts could significantly enhanced the rate of wound healing. *P. niruri* extract possess a broad spectrum of biological activities. It has been reported by Martin [11] *P. niruri* plays a significant role in the wound healing process and protect tissues from oxidative damage. Wound healing mechanisms may be contributed

to stimulate the production of antioxidants in wound site and provides a favorable environment for tissue healing [12] and wound healing effects may be due to up-regulation of human collagen I expression [13] and an increase in tensile strength of the wounds [14]. Enhanced healing activity was attributed to increased collagen formation and angiogenesis [12,15]. Angiogenesis in granulation tissues improves circulation to the wound site thus providing oxygen and essential nutrients for the healing process with enhanced epithelial cell proliferation [16]. *P. niruri* extracts showed inhibition of membrane lipid peroxidation, potent free radical scavenging and inhibition of reactive oxygen species and this could associate with its high medicinal value [6].

Phytochemical analysis of the *P. niruri* extract showed the presence of several bioactive molecules such as lignans, phyllanthin, hypophyllanthin, flavonoids, glycosides and tannins [7]. Any one of the observed phytochemical constituents present in *P. niruri* extract may be responsible for the wound healing activity. Phytochemical constituents like flavonoids [17] and triterpenoids [18] are known to promote the wound-healing process due to the astringent and antimicrobial properties, which appear to be responsible for wound contraction and increased rate of epithelialization. The wound healing property of *P. niruri* extracts observed in our study may be attributed to the phytoconstituents present in the plant such as tannins [19]. Habibipour *et al.* showed that treated healed wound group contained a large amount of fibroblasts proliferation, collagen synthesis and neovascularization, which resulted in an increased wound tensile strength and accelerated wound

healing [20]. The current study indicates that the dressing with *Phyllanthus niruri* extracts, as topical application of wounds, enhanced wound healing process significantly in experimental rats.

#### ACKNOWLEDGEMENT

This study was financially supported by the University of Malaya through the Science fund grant No. 12-02-03-2051.

#### REFERENCES

1. Chupra, R.N., S.L. Nayar and I.C. Chopra, 1986. Glossary of Indian medicinal plants, CSIR, New Delhi, Ranchi, India: Catholic press.
2. Wang, B.E., 2000. Treatment of chronic liver diseases with traditional Chinese medicine. *J. Gastroenterol. Hepatol.*, 15: E67-E70.
3. Blumberg, B.S., I. Millman, P.S. Venkateswaran and S.P. Thyagarajan, 1990. Hepatitis B virus and primary hepatocellular carcinoma: treatment of HBV carriers with *P. amarus*. *Vaccine*, 8: S86-S92.
4. Khanna, A.K., F. Rizivi and R. Chander, 2002. Lipid lowering activity of *P. niruri* in hyperlipemic rats. *J. Ethnopharmacol.*, 82(1): 19-22.
5. Abdulla, M.A., K.A. Ahmed, F.H. AL-Bayat and Y. Masood, 2010. Gastroprotective effect of *Phyllanthus niruri* leaf extract against ethanol-induced gastric mucosal injury in rats. *Afri. J. Pharmacy Pharmacol.*, 4(5): 226-230.
6. Harish, R. and T. Shivanandappa, 2006. Antioxidant activity and hepatoprotective potential of *P. niruri*. *Food Chem.*, 95: 180-185.
7. Rajeshkumar, N.V., K.L. Joy, K. Girija, R.S. Ramsewak, M.G. Nair and K. Ramadasan, 2002. Antitumor and anticarcinogenic activity of *P. amarus* extract. *J. Ethnopharmacol.*, 81: 17-22.
8. Santos, A.R., V.C. Filho, R.A. Yunes and J.B. Calixto, 1995. Analysis of the mechanisms underlying the antinociceptive effect of the extracts from plant genus *Phyllanthus*. *General Pharmacol.* 26(7): 1499-1506.
9. Freitas, A.M., N. Schor and M.A. Boim, 2002. The effect of *P. niruri* on urinary inhibitors of calcium oxalate crystallization and other factors associated with renal stone formation. *BJU Int.*, 89(9): 829-834.
10. Suguna, L., S. Singh, P. Sivakumar, P. Sampath and G. Chandrakasan, 2002. Influence of *Terminalia chebula* on dermal wound healing in rats. *Phytother. Res.*, 16: 227-231.
11. Martin, A., 1996. The use of antioxidants in wound healing. *Dermatol. Surg.*, 22: 156-160.
12. Shukla, A., A.M. Rasik and B.N. Dhawan, 1999. Asiaticoside-induced elevation of antioxidant levels in healing wounds. *Phytother. Res.*, 13(1): 50-54.
13. Bonte, F., M. Dumas, C. Chadgne and A. Meybeck, 1993. Influence of asiatic acid, madecassic acid and asiaticoside on human collagen I synthesis. *Planta Medica*, 60: 133-135.
14. Suguna, L., P. Sivakumar and G. Chandrakasan, 1996. Effects of *Centella asiatica* extract on dermal wound healing in rats. *Ind. J. Exp. Biol.*, 34: 1208-1211.
15. Trabucchi, E., F. Preis-Baruffaldi, C. Baratti and W. Montorsi, 1986. Topical treatment of experimental skin lesions in rats: macroscopic, microscopic and scanning electron-microscopic evaluation of the healing process. *Int. J. Tissue React.*, 8: 533-544.
16. Szabo, S., S. Kusstatscher, G. Sakoulas, Z. Sandor, A. Vincze and M. Jadus, 1995. Growth factors: New "endogeneous drug" for ulcer healing. *Scand. J. Gastroenterol.*, 210: 15-18.
17. Tsuchiya, H., M. Sato, T. Miyazaki, S. Fujiwara, S. Tanigaki, M. Ohyama, T. Tnaaka and M. Linuma, 1996. Comparative study on the antibacterial activity of Phytochemical flavanones against methicillin-resistant *Staphylococcus aureus*. *J. Ethnopharmacol.*, 50: 27-34.
18. Scortichini, M. and M. Pia Rossi, 1991. Preliminary *in vitro* evaluation of the antibacterial activity of terpenes and terpenoids towards *Erwinia amylovora* (Burrill). *J. Appl. Bacteriol.*, 71: 109-112.
19. Chaudhari, M. and S. Mengi, 2006. Evaluation of phytoconstituents of *Terminalia arjuna* for wound healing activity in rats. *Phytother. Res.*, 20: 799-805.
20. Habibipour, S., T.M. Oswald, F. Zhang, P. Joshi, X.C. Zhou, W. Dorsett-Martin and W.C. Lineaweaver, 2003. Effect of sodium diphenylhydantoin on skin wound healing in rats. *Plast Reconstr. Surg.*, 112: 1620-1627.