

Wound Repair and Regeneration

J.M. Reinke H. Sorg

Department of Plastic, Hand and Reconstructive Surgery, Hannover Medical School, Hannover, Germany

Key Words

Angiogenesis · Epithelialization · Granulation tissue · Inflammation · Scarring

Abstract

The skin is the biggest organ of the human being and has many functions. Therefore, the healing of a skin wound displays an extraordinary mechanism of cascading cellular functions which is unique in nature. As healing and regeneration processes take place in all parts of the human body, this review focuses on the healing processes of the skin and highlights the classical wound healing phases. While regeneration describes the specific substitution of the tissue, i.e. the superficial epidermis, mucosa or fetal skin, skin repair displays an unspecific form of healing in which the wound heals by fibrosis and scar formation. The first stage of acute wound healing is dedicated to hemostasis and the formation of a provisional wound matrix, which occurs immediately after injury and is completed after some hours. Furthermore, this phase initiates the inflammatory process. The inflammatory phase of the wound healing cascade gets activated during the coagulation phase and can roughly be divided into an early phase with neutrophil recruitment and a late phase with the appearance and transformation of monocytes. In the phase of proliferation the main focus of the healing process lies in the recovering of the wound surface, the forma-

tion of granulation tissue and the restoration of the vascular network. Therefore, next to the immigration of local fibroblasts along the fibrin network and the beginning of reepithelialization from the wound edges, neovascularization and angiogenesis get activated by capillary sprouting. The formation of granulation tissue stops through apoptosis of the cells, characterizing a mature wound as avascular as well as acellular. During the maturation of the wound the components of the extracellular matrix undergo certain changes. The physiological endpoint of mammalian wound repair displays the formation of a scar, which is directly linked to the extent of the inflammatory process throughout wound healing.

Copyright © 2012 S. Karger AG, Basel

Introduction

An intact outer sheath is one of the most important features from simple bacteria to complex multicellular organisms. Furthermore, the ability of organisms to repair or regenerate tissues in order to restore organ functions has been and still is a selective advantage and a survival factor in nature. As most of the organisms are subject to a continuous renewal process throughout life, the ability to heal is developed differently throughout diverse species from simple tissue repair to the regenera-

tion of complete organs as shown in axolotls (*Ambystoma mexicanum*). Wound healing, mostly meaning the healing of the skin, has been recognized as important to health since the beginning of mankind. Papyrus scrolls from old Egypt (3,200–300 BC) already describe wound care procedures with the use of compression for hemostasis. They also describe wound dressing techniques by Hippocrates, indicating the importance of pus drainage from the wound ('Ubi pus, ibi evacua'), and Galen, depicting the principles of wound healing by primary and secondary intention. Much of this knowledge, however, got lost over time and has been newly or rediscovered in the modern era by Brunschwig, von Gersdorff and Paracelsus. In the late 19th century the development of antiseptics by Lister and Semmelweis, the detection of pathogenic microorganisms by Koch, and most notably the discovery of penicillin by Fleming and of sulfonamides by Domagk [1] had an enormous impact on the understanding, therapy and outcome of wound healing. Nowadays, research highlights a deeper understanding of the complex interplay of cells and the distinct influence of the different cytokines and growth factors, and unfolds the molecular biology of skin wound healing. But after 5,000 years of wound therapy the goals have not changed. The patient still deserves a fast, uncomplicated and antiseptic wound closure, but also claims an aesthetic outcome with unimposing scar formation. As healing and regeneration processes take place in all parts of the human body, this review will focus on the healing processes of the skin and will highlight the classical wound healing phases.

Physiology of Adult Skin Wound Healing

Skin wound healing is a dynamic and highly regulated process of cellular, humoral and molecular mechanisms which begins directly after wounding and might last for years. Every tissue disruption of normal anatomic structure with consecutive loss of function can be described as a wound [2]. Integumental injuries are defined as open or outer wounds, whereas inner or closed wounds describe injuries or ruptures of inner organs and tissues with a still intact skin. The closure of a skin wound can be realized by regeneration or repair. While regeneration describes the specific substitution of the tissue, i.e. the superficial epidermis, mucosa or fetal skin, skin repair displays an unspecific form of healing in which the wound heals by fibrosis and scar formation. The latter, unfortunately, presents the main form in adult skin wound healing. The

process of skin wound healing is often described as a playing orchestra or as the acts of a drama [3, 4], whose interplay of cells, growth factors and cytokines ends up in a closure of the skin. However, even when this sensitive balance between cells and mediators might be disrupted, recent data suggest that the deficiency of a cell type or the absence of a mediator can be compensated by others that are involved in wound healing so that the repair can still occur [5]. The process of wound healing can artificially be divided into three to five phases which overlap in time and space [6]. The purpose of this review is to highlight in detail the actual distinct processes during skin wound healing.

The Vascular Response: Hemostasis and Coagulation

The first stage of physiological or acute wound healing is dedicated to hemostasis and the formation of a provisional wound matrix, which occurs immediately after injury and is completed after some hours (fig. 1). Furthermore, this phase initiates the inflammatory process. Sometimes this phase is also described as the 'lag-phase', in which the organism has to manage the recruitment of the many cells and factors for the healing process in the absence of the mechanical strength of the wound [1]. With a skin injury outreaching the epidermal layer, blood and lymphatic vessels are traumatized, flushing the wound to remove microorganisms and antigens [7]. The different clotting cascades are then initiated by clotting factors from the injured skin (extrinsic system), and thrombocytes get activated for aggregation by exposed collagen (intrinsic system). At the same time the injured vessels follow a 5- to 10-min vasoconstriction, triggered by the platelets, to reduce blood loss and fill the tissue gap with a blood clot comprised of cytokines and growth factors [8]. Furthermore, the blood clot contains fibrin molecules, fibronectin, vitronectin and thrombospondins, forming the provisional matrix as a scaffold structure for the migration of leukocytes, keratinocytes, fibroblasts and endothelial cells and as a reservoir of growth factors. The life-saving vasoconstriction with clot formation accounts for a local perfusion failure with a consecutive lack of oxygen, increased glycolysis and pH-changes [9]. The vasoconstriction is then followed by a vasodilation in which thrombocytes invade the provisional wound matrix [1]. In addition, platelets influence the infiltration of leukocytes by the release of chemotactic factors. Both platelets and leukocytes release cytokines and growth factors to activate the inflammatory process (IL-1 α , IL-

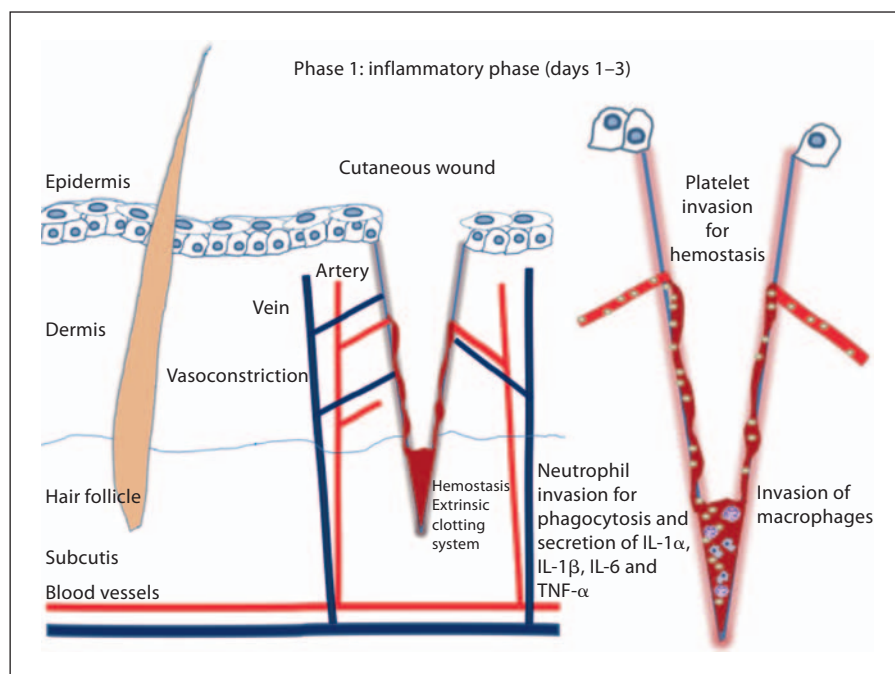


Fig. 1. Inflammatory phase after a cutaneous cut; hemostasis and invasion of inflammatory cells.

IL-1 β , IL-6 and TNF- α), stimulate the collagen synthesis (FGF-2, IGF-1, TGF- β), activate the transformation of fibroblasts to myofibroblasts (TGF- β), start the angiogenesis (FGF-2, VEGF-A, HIF-1 α , TGF- β) and already support the reepithelialization process (EGF, FGF-2, IGF-1, TGF- α) [10]. The vasodilation can also be recognized by a local redness (hyperemia) and by an edema of the wound.

The Cellular Response: Inflammation

The inflammatory phase of the wound healing cascade gets activated during the hemostasis and coagulation phase and can roughly be divided into an early phase with neutrophil recruitment and a late phase with the appearance and transformation of monocytes (fig. 1). Due to the response of the activated complement pathway, degranulated platelets and by-products of bacterial degradation, neutrophils are recruited to the site of the skin injury and are present for 2–5 days unless the wound gets infected. The work of the neutrophils is crucial within the first days after injury because their ability in phagocytosis and protease secretion kills local bacteria and helps to degrade necrotic tissue. Furthermore, they act as chemoattractants for other cells that are involved in the inflammatory phase [5].

Neutrophils release mediators such as TNF- α , IL-1 β and IL-6, which amplify the inflammatory response and stimulate VEGF and IL-8 for an adequate repair response. Furthermore, they start their debridement by releasing highly active antimicrobial substances (cationic peptides and eicosanoids) and proteinases (elastase, cathepsin G, proteinase 3 and a urokinase-type plasminogen activator) [5]. In vitro studies further showed that neutrophils could change the phenotype and cytokine profile expression of macrophages, which leads to an innate immune response during healing [11].

Approximately 3 days after injury macrophages enter the zone of injury and support the ongoing process by performing phagocytosis of pathogens and cell debris [12, 13] as well as by the secretion of growth factors, chemokines and cytokines. Apart from their actual support in wound healing, these molecules keep the healing process intact, as some of them are able to activate the next phase of wound healing (proliferative phase) [14]. The inflammatory response to injury is essential for supplying growth factor and cytokine signals that are responsible for cell and tissue movements, which are crucial for the subsequent repair mechanisms in adult mammals [5, 15]. There is evidence that the amount of inflammation determines the extent of scar formation. The lack of intrauterine inflammation is mentioned as evidence for the theory of scarless wound healing in fetuses [16, 17].

Macrophages have many functions including host defense, the promotion and resolution of inflammation, the removal of apoptotic cells and the support of cell proliferation and tissue restoration following injury [18]. Beside their immunological functions as antigen-presenting cells and phagocytes during wound repair, macrophages supposedly play an integral role in a successful healing response through the synthesis of numerous potent growth factors such as TGF- β , TGF- α , basic FGF, PDGF and VEGF, which promote cell proliferation and the synthesis of extracellular matrix (ECM) molecules by resident skin cells [19].

Proliferation and Repair

Reepithelialization/Resurfacing

In the phase of proliferation (approx. 3–10 days after wounding) the main focus of the healing process lies in covering the wound surface, the formation of granulation tissue and restoring the vascular network. Therefore, next to the immigration of local fibroblasts along the fibrin network and the beginning of reepithelialization from the wound edges, neovascularization and angiogenesis get activated by capillary sprouting [1, 7, 20–22]. Under the control of regulating cytokines like IFN- γ and TGF- β , the synthesis of collagen, fibronectin and other basic substances needed for wound healing by fibroblasts represents the basis for the new matrix of connective tissue, serving for the closure of tissue gaps and the restoration of the mechanical strength of the wound. Subsequently, the synthesis of collagen increases throughout the wound, while the proliferation of fibroblasts declines successively, adjusting a balance between synthesis and degradation of the ECM [23].

The reepithelialization process is ensured by local keratinocytes at the wound edges and by epithelial stem cells from hair follicles or sweat glands [8, 24–26]. This process is activated by signaling pathways of epithelial and nonepithelial cells at the wound edges, which release a myriad of different cytokines and growth factors, e.g. EGF, KGF, IGF-1, and NGF [10]. Furthermore, the abolition of the contact inhibition and physical tension at desmosomes and hemidesmosomes produces lipid mediators and activates membrane-associated kinases (SRC kinases) resulting in an increased permeability of the membranes for ions, e.g. calcium. This displays an initiating signal to the cells at the wound edges with a retraction and reorganization of their intracellular tonofilaments in the direction of migration. By the enzymatic loosening of

the intercellular desmosomes via collagenase and elastase, activated keratinocytes migrate along the preformed fibrin blood clot in the higher layers of the granulation tissue. This process is called the ‘shuffling’ of keratinocytes [27] and describes the ability of these cells to migrate competitively along a chemotactic gradient established by mediators such as IL-1, and over a fibronectin-rich matrix into the center of the wound [28, 29]. Lamellipodial crawling performs the migration itself and is directed into the defect site via the polymerization of cytoskeletal actin fibers in the excrescence and the formation of a new focal adhesion at the ECM which is mediated by integrins. These cytoskeletal mechanisms are regulated by RhoGTPases (Rho, Rac, Cdc42) [30, 31]. Small GTPases are the shifters of the intracellular organization of fibers and are essential for an orchestrated epithelialization process as well as the termination of migration. This process proceeds until the migrating cells touch each other. Then, the GTPases will probably be turned off leading to a reorganization of the cytoskeleton [27]. The fusion of the opposing epithelia is realized by a degradation of the actin fibers in filopodia, which are replaced by intercellular adherence contacts to finally close the wound like a zipper [27].

Neovascularization/Angiogenesis

The restoration of the vascular system of the skin is a complex cascade of cellular, humoral and molecular events in the wound bed to reconnect to the nutritive perfusion. Initiators are growth factors, e.g. VEGF, PDGF, bFGF and the serine protease thrombin. The first step in new vessel formation is the binding of growth factors to their receptors on the endothelial cells of existing vessels, thereby activating intracellular signaling cascades. The activated endothelial cells secrete proteolytic enzymes which dissolve the basal lamina. Thus, the endothelial cells are now able to proliferate and migrate into the wound, a process also known as ‘sprouting’. The endothelial cells orientate themselves at superficial adhesion molecules, e.g. integrins ($\alpha v \beta 3$, $\alpha v \beta 5$, $\alpha 5 \beta 1$). Furthermore, they release matrix metalloproteinases at the front of proliferation, lysing the surrounding tissue for the ongoing endothelial proliferation. The newly built sprouts form small tubular canals which interconnect to others forming a vessel loop. Thereafter, the new vessels differentiate into arteries and venules and mature by a further stabilization of their vessel wall via the recruitment of pericytes and smooth muscle cells. Finally, the initial blood flow completes the angiogenic process. Within full dermal thickness wounds the neovascularization process follows

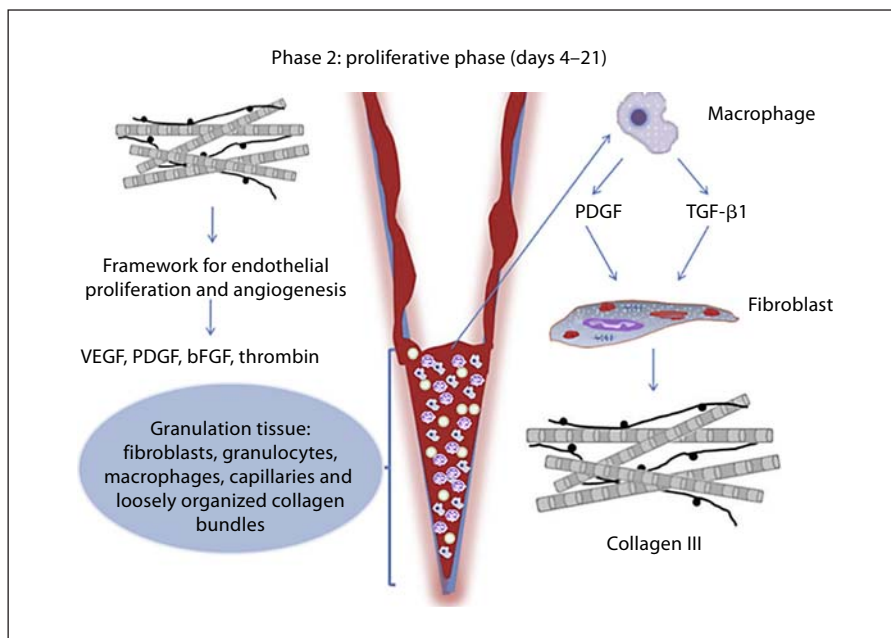


Fig. 2. Proliferative phase; organization of the thrombus, secretion of growth factors, synthesis of collagen III and the beginning of angiogenesis.

a distinct pattern in time and shape. At the beginning the vessels form an inner ring of circularly arranged vessels at the wound margin followed by outer radially arranged vessels supplying the inner ones. Because the design of the vessels is similar to the sun, this has also been called 'sola cutis se reficientis' [32]. As the wound closure proceeds, the inner vascular ring shrinks, resulting in the complete disappearance of the vessel ring. The radially arranged vessels, however, interconnect with each other in time, forming a new dermal vascular network [32].

Granulation Tissue Formation

The last step in the proliferation phase is the development of the acute granulation tissue (fig. 2). At the same time the remodeling phase is already initiated. As a transitional tissue it replaces the fibrin-/fibronectin-based provisional wound matrix and might produce a scar by maturation [1, 3, 4, 7, 8, 14, 33]. Furthermore, it is characterized by a high density of fibroblasts, granulocytes, macrophages, capillaries and loosely organized collagen bundles (fig. 2). Due to this high amount of cellular compounds it is called granulation tissue. Also, as the angiogenesis is not completely finished yet, this tissue is highly vascular. As a result it appears with a classic redness and might be traumatized easily. However, the dominating cell in this phase is the fibroblast, which fulfils different functions such as the production of collagen and ECM substances (i.e. fibronectin, glycosaminoglycans, proteo-

glycans and hyaluronic acid). The formation of the ECM represents another important step as it provides a scaffold for cell adhesion and critically regulates and organizes the growth, movement and differentiation of the cells within it [34, 35]. The fibroblast is, therefore, the precursor of the provisional wound matrix on and in which the respective cell migration and organization takes place [27]. At the end of this phase the number of maturing fibroblasts is reduced by myofibroblast differentiation and terminated by consecutive apoptosis [36].

Remodeling

Remodeling is the last phase of wound healing and occurs from day 21 to up to 1 year after injury. The formation of granulation tissue stops through apoptosis of the cells. A mature wound is, therefore, characterized as avascular as well as acellular [37]. During the maturation of the wound the components of the ECM undergo certain changes. Collagen III, which was produced in the proliferative phase, is now replaced by the stronger collagen I (fig. 3). This type of collagen is oriented in small parallel bundles and is, therefore, different from the basket-weave collagen in healthy dermis [38]. Later on the myofibroblasts cause wound contractions by their multiple attachment to collagen and help to decrease the surface of the developing scar [12, 13, 38]. Furthermore, the

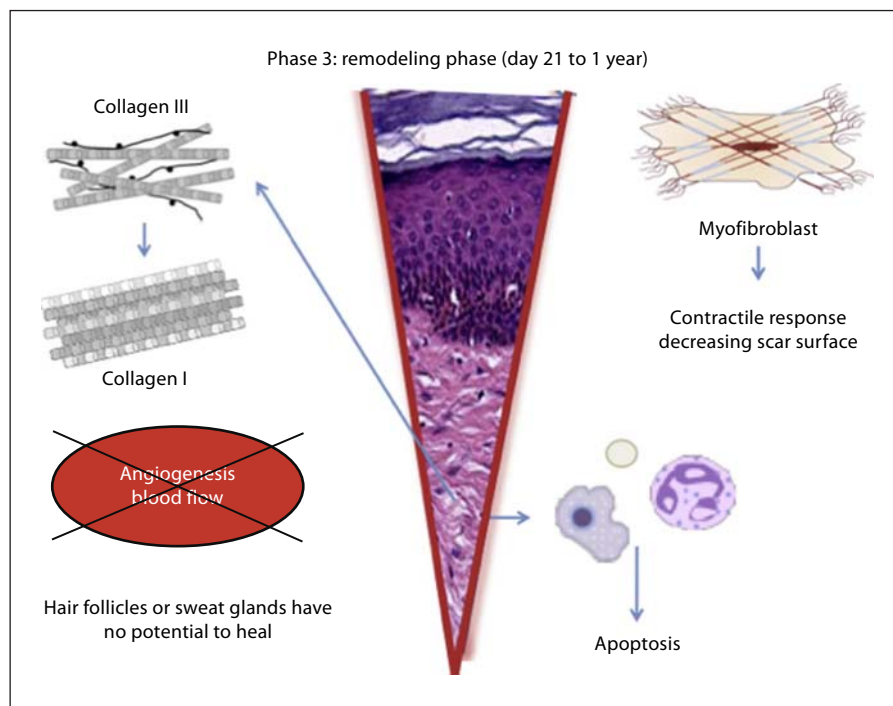


Fig. 3. Remodeling phase; regenerative processes fade and are followed by reorganization of the connective tissue and contractile response.

angiogenic processes diminish, the wound blood flow declines, and the acute wound metabolic activity slows down and finally stops.

Contrary to fetal wound healing, there are certain skin components that will never fully recover after wound closure. Subepidermal appendages such as hair follicles or sweat glands have no potential to heal or grow back after serious injury. The epidermis of the resultant scar differs from uninjured skin after wound healing due to the lack of rete pegs that are normally anchored into the underlying connective tissue matrix and are responsible for the tight connection of the epidermis to the dermis [1].

Fetal Wound Healing

In contrast to the adult human tissue reaction to injury the early gestation fetus has the ability to heal without scarring. This unique healing process was first discovered in 1979 [39] and was confirmed in many animal and human trials [40, 41]. Scarless wound healing was observed in the fetuses of rats, mice, pigs, monkeys and humans [42] and is age-dependent in the different species [43, 44]. In humans, scarless wound healing stops at approximately 24 weeks of gestation, whereas in mice it stops at day 18.5 (gestation period of mice: 20 days) [42,

45, 46]. The exact day is determined by the wound size; bigger injuries might leave a scar earlier than small scratches [44]. Fetal skin structure and histology change rapidly during pregnancy. Within the first 20 days the fetus is only covered in a primitive epidermis, which develops into a two-layered periderm and a basal cell layer within 4–8 weeks. At week 9 the stratification of the fetal epidermis begins and keratinization begins at week 14. By the time the fetus reaches week 16 the fetal epidermis already has many of the components of the adult epidermis: a basal layer, an intermediate layer, hair follicles, sweat glands and follicular keratinization. After 24 weeks of gestation rapid growth and maturation start to dominate the process and by the time of birth the neonatal skin is indistinguishable from adult skin [47, 48]. In response to tissue injury, the fetal dermis has the ability to regenerate a nondisrupted collagen matrix that is identical to the original tissue [49, 50]. Interestingly, even dermal appendages such as sebaceous glands and hair follicles heal normally after fetal injury [51]. There is evidence that the reasons for scarless wound healing in fetal tissue is due to the differences in the ECM, inflammatory response, cellular mediators, differential gene expression and stem cell function [52–55]. The inflammatory response in an embryonic wound consists of a lower number of less-differentiated cells (neutrophils, monocytes and macrophages),

which in combination with a very different profile of growth factors contributes to the much better wound healing in fetal tissue. Furthermore, the length of presentation of an inflammatory cell is reduced compared to adult wounds [56]. Molecular changes involve low levels of TGF- β 1, TGF- β 2 and PDGF and high levels of TGF- β 3 [41]. Due to the rapidly developing and growing skin volume, the fetal tissue consists of high levels of morphogenetic factors which are involved in skin growth, remodeling and morphogenesis. These two principals – reduced inflammatory response and altered skin morphogenesis – lead to a qualitatively, quantitatively and temporally different growth factor profile compared to adult wound healing [41, 49, 56, 57].

Scarring

Scar formation is the physiological endpoint of mammalian wound repair. There are different situations which provide evidence that inflammation during the process of wound healing is directly linked to the extent of scar formation [5]. First, there is the fact that fetal wound healing, which shows a lack of the typical inflammatory response, is scarless up to a certain age [16, 17]. In addition, scar formation seems to be extended when inflammation in fetal wounds is induced [49]. A second example indicating the role of inflammation on the formation of scars is the influence of reproductive hormones on this process. Studies showed that low estrogen levels in mice resulted in an impaired rate of healing including excessive inflammation and scarring [5, 58, 59].

Most nonhealing wounds fail to progress through the normal phases of wound repair, but remain in a chronic inflammatory state [60] which leads to abnormal wound repair, e.g. to hypertrophic or keloid scars. Keloids contain thick collagen fibers, whereas hypertrophic scars contain thin fibers which are organized into nodules [61, 62]. Changes in collagen maturation are fundamental changes in excessive scar formation. The granulation tissue continues to grow due to the excessive secretion of growth factors and the lack of molecules required for apoptosis or ECM remodeling. Hypertrophic scars contain excessive microvessels, which are mostly occluded due to the overproliferation and functional regression of endothelial cells induced by myofibroblast hyperactivity and excessive collagen production [63].

Focal upregulation of p53 expression, which seems to play an important role in the inhibition of apoptosis, has been reported in situations of excessive scarring. Further-

more, mechanical irritation in the early proliferative phase leads to hypertrophic scars by inhibiting apoptosis [64].

Changes in the ECM and the epithelium seem to be involved in excessive scarring also [65–67]. A neurogenic inflammation hypothesis has been suggested [68]: mechanical stress stimulates mechanosensitive nociceptors in skin sensory fibers that release neuropeptides involved in vessel modifications and fibroblast activation. Excessive scarring is a fibrotic disorder resulting from the disruption of the normal wound healing process [69].

Conclusion and Outlook

The regulation of cellular functions during skin repair following injury is complex and critically dependent on the interaction of cells with the ECM, which can be impaired at every step and time point of the wound healing process. Many cellular or cytokine actions can be adopted by others without severe interference with the healing process. However, some singular actions might be crucial or the sum of many healing insufficiencies might lead to chronic or nonhealing wounds. Research in this specialized field is still ongoing and many questions are still unanswered. However, a better understanding of this complex interplay provides the basis for designing new and effective wound healing therapies. Knowledge gained from studying the genetic and molecular pathways and from cytokine interactions and influences, as well as the enormous development of functional new wound dressings for the conservative wound therapy, might further help to decrease the incidence of nonhealing wounds and support the healing process under poor conditions. Furthermore, the auspicious options in stem cell therapy as well as in tissue engineering offer new therapy possibilities in skin wound healing.

References

- 1 Robson MC, Steed DL, Franz MG: Wound healing: biologic features and approaches to maximize healing trajectories. *Curr Probl Surg* 2001;38:72–140.
- 2 Lazarus GS, Cooper DM, Knighton DR, Percoraro RE, Rodeheaver G, Robson MC: Definitions and guidelines for assessment of wounds and evaluation of healing. *Wound Repair Regen* 1994;2:165–170.
- 3 Krafts KP: Tissue repair: the hidden drama. *Organogenesis* 2010;6:225–233.
- 4 Enoch S, John Leaper D: Basic science of wound healing. *Surgery (Oxford)* 2005;23:37–42.

- 5 Eming SA, Krieg T, Davidson JM: Inflammation in wound repair: molecular and cellular mechanisms. *J Invest Dermatol* 2007; 127:514–525.
- 6 Epstein HF: Cutaneous wound healing. *N Engl J Med* 1999;341:738–746.
- 7 Strodbeck F: Physiology of wound healing. *Newborn Infant Nurs Rev* 2001;1:43–52.
- 8 Martin P: Wound healing – aiming for perfect skin regeneration. *Science* 1997;276:75–81.
- 9 Woo YC, Park SS, Subieta AR, Brennan TJ: Changes in tissue pH and temperature after incision indicate acidosis may contribute to postoperative pain. *Anesthesiology* 2004; 101:468–475.
- 10 Werner S, Grose R: Regulation of wound healing by growth factors and cytokines. *Physiol Rev* 2003;83:835–870.
- 11 Daley JM, Reichner JS, Mahoney EJ, Manfield L, Henry WL, Mastrofrancesco B, et al: Modulation of macrophage phenotype by soluble product(s) released from neutrophils. *J Immunol* 2005;174:2265–2272.
- 12 Tziotzios C, Profyris C, Sterling J: Cutaneous scarring: pathophysiology, molecular mechanisms, and scar reduction therapeutics. *J Am Acad Dermatol* 2012;66:13–24.
- 13 Profyris C, Tziotzios C, Do Vale I: Cutaneous scarring: pathophysiology, molecular mechanisms, and scar reduction therapeutics. *J Am Acad Dermatol* 2012;66:1–10.
- 14 Gurtner GC, Werner S, Barrandon Y, Longaker MT: Wound repair and regeneration. *Nature* 2008;453:314–321.
- 15 Leibovich SJ, Ross R: The role of the macrophage in wound repair. A study with hydrocortisone and antimacrophage serum. *Am J Pathol* 1975;78:71–100.
- 16 Bullard KM, Longaker MT, Lorenz HP: Fetal wound healing: current biology. *World J Surg* 2003;27:54–61.
- 17 Redd MJ, Cooper L, Wood W, Stramer B, Martin P: Wound healing and inflammation: embryos reveal the way to perfect repair. *Philos Trans R Soc Lond B Biol Sci* 2004; 359:777–784.
- 18 Koh TJ, DiPietro LA: Inflammation and wound healing: the role of the macrophage. *Expert Rev Mol Med* 2011;13:e23.
- 19 DiPietro LA, Polverini PJ: Role of the macrophage in the positive and negative regulation of wound neovascularization. *Behring Inst Mitt* 1993;92:238–247.
- 20 Bauer SM: Angiogenesis, vasculogenesis, and induction of healing in chronic wounds. *Vasc Endovasc Surg* 2005;39:293–306.
- 21 Arnold F, West DC: Angiogenesis in wound healing. *Pharmacol Ther* 1991;52:407–422.
- 22 Endrich B, Menger MD: Regeneration of the microcirculation during wound healing? *Unfallchirurg* 2000;103:1006–1008.
- 23 Madden JW, Peacock EE: Studies on the biology of collagen during wound healing. 3. Dynamic metabolism of scar collagen and remodeling of dermal wounds. *Ann Surg* 1971; 174:511–520.
- 24 Lau K, Paus R, Tiede S, Day P, Bayat A: Exploring the role of stem cells in cutaneous wound healing. *Exp Dermatol* 2009;18:921–933.
- 25 Miller SJ, Burke EM, Rader MD, Coulombe PA, Lavker RM: Re-epithelialization of porcine skin by the sweat apparatus. *J Invest Dermatol* 1998;110:13–19.
- 26 Roh C, Lyle S: Cutaneous stem cells and wound healing. *Pediatr Res* 2006;59:100R–103R.
- 27 Jacinto A, Martinez-Arias A, Martin P: Mechanisms of epithelial fusion and repair. *Nat Cell Biol* 2001;3:E117–E123.
- 28 Clark RA, Lanigan JM, DellaPelle P, Manseau E, Dvorak HF, Colvin RB: Fibronectin and fibrin provide a provisional matrix for epidermal cell migration during wound reepithelialization. *J Invest Dermatol* 1982; 79:264–269.
- 29 Clark RA: Fibronectin in the skin. *J Invest Dermatol* 1981;6:475–479.
- 30 Nobes CD, Hall A: Rho GTPases control polarity, protrusion, and adhesion during cell movement. *J Cell Biol* 1999;144:1235–1244.
- 31 Nobes CD, Hall A: Rho, rac, and cdc42 GTPases regulate the assembly of multimolecular focal complexes associated with actin stress fibers, lamellipodia, and filopodia. *Cell* 1995;81:53–62.
- 32 Sorg H, Krueger C, Vollmar B: Intravital insights in skin wound healing using the mouse dorsal skin fold chamber. *J Anat* 2007; 211:810–818.
- 33 Nauta A, Gurtner G, Longaker M: Wound healing and regenerative strategies. *Oral Dis* 2011 18;17:541–549.
- 34 Eckes B, Nischt R, Krieg T: Cell-matrix interactions in dermal repair and scarring. *Fibrogenesis Tissue Repair* 2010;3:4.
- 35 Barker TH: The role of ECM proteins and protein fragments in guiding cell behavior in regenerative medicine. *Biomaterials* 2011;32: 4211–4214.
- 36 Hinz B: Formation and function of the myofibroblast during tissue repair. *J Invest Dermatol* 2007;127:526–537.
- 37 Greenhalgh DG: The role of apoptosis in wound healing. *Int J Biochem Cell Biol* 1998; 30:1019–1030.
- 38 Gurtner GC, Evans GRD: Advances in head and neck reconstruction. *Plast Reconstr Surg* 2000;106:672–682.
- 39 Rowlatt U: Intrauterine wound healing in a 20 week human fetus. *Virchows Arch A Pathol Anat Histol* 1979;381:353–361.
- 40 Whitby DJ, Ferguson MW: The extracellular matrix of lip wounds in fetal, neonatal and adult mice. *Development* 1991;112:651–668.
- 41 Ferguson MW, O’Kane S: Scar-free healing: from embryonic mechanisms to adult therapeutic intervention. *Philos Trans R Soc B Biol Sci* 2004;359:839–850.
- 42 Colwell AS, Krummel TM, Longaker MT, Lorenz HP: An in vivo mouse excisional wound model of scarless healing. *Plast Reconstr Surg* 2006;117:2292–2296.
- 43 Somasundaram K, Prathap K: Intra-uterine healing of skin wounds in rabbit fetuses. *J Pathol* 1970;100:81–86.
- 44 Cass DL, Bullard KM, Sylvester KG, Yang EY, Longaker MT, Adzick NS: Wound size and gestational age modulate scar formation in fetal wound repair. *J Pediatr Surg* 1997;32: 411–415.
- 45 Lorenz HP, Whitby DJ, Longaker MT, Adzick NS: Fetal wound healing. The ontogeny of scar formation in the non-human primate. *Ann Surg* 1993;217:391–396.
- 46 Lorenz HP, Lin RY, Longaker MT, Whitby DJ, Adzick NS: The fetal fibroblast: the effector cell of scarless fetal skin repair. *Plast Reconstr Surg* 1995;96:1251–1261.
- 47 Coolen N, Schouten K, Middelkoop E, Ulrich MM: Comparison between human fetal and adult skin. *Arch Dermatol Res* 2010;302: 47–55.
- 48 Lane A: Human fetal skin development. *Pediatr Dermatol* 1986;3:487–491.
- 49 Whitby DJ, Ferguson MW: Immunohistochemical localization of growth factors in fetal wound healing. *Dev Biol* 1991;147:207–215.
- 50 Beanes SR, Hu F-Y, Soo C, Dang CMH, Urata M, Ting K, et al: Confocal microscopic analysis of scarless repair in the fetal rat: defining the transition. *Plast Reconstr Surg* 2002;109:160–170.
- 51 Rendl M, Lewis L, Fuchs E: Molecular dissection of mesenchymal-epithelial interactions in the hair follicle. *PLoS Biol* 2005; 3:e331.
- 52 Soo C, Hu FY, Zhang X, Wang Y, Beanes SR, Lorenz HP, et al: Differential expression of fibromodulin, a transforming growth factor-beta modulator, in fetal skin development and scarless repair. *Am J Pathol* 2000; 157:423–433.
- 53 Beanes SR, Dang C, Soo C, Wang Y, Urata M, Ting K, et al: Down-regulation of decorin, a transforming growth factor-beta modulator, is associated with scarless fetal wound healing. *J Ped Surg* 2001;36:1666–1671.
- 54 Wagers AJ, Christensen JL, Weissman IL: Cell fate determination from stem cells. *Gene Ther* 2002;9:606–612.
- 55 Shizuru JA, Negrin RS, Weissman IL: Hematopoietic stem and progenitor cells: clinical and preclinical regeneration of the hematolymphoid system. *Annu Rev Med* 2005;56: 509–538.
- 56 Cowin AJ, Brosnan MP, Holmes TM, Ferguson MW: Endogenous inflammatory response to dermal wound healing in the fetal and adult mouse. *Dev Dyn* 1998;212:385–393.
- 57 O’Kane S, Ferguson MW: Transforming growth factor beta s and wound healing. *Int J Biochem Cell Biol* 1997;29:63–78.

- 58 Ashcroft G, Mills S, Lei K, Gibbons L, Jeong MJ, Taniguchi M, et al: Estrogen modulates cutaneous wound healing by downregulating macrophage migration inhibitory factor. *J Clin Invest* 2003;111:1309–1318.
- 59 Ashcroft GS, Yang X, Glick AB, Weinstein M, Letterio JL, Mizel DE, et al: Mice lacking Smad3 show accelerated wound healing and an impaired local inflammatory response. *Nat Cell Biol* 1999;1:260–266.
- 60 Loots MA, Lamme EN, Zeegelaar J, Mekkes JR, Bos JD, Middelkoop E: Differences in cellular infiltrate and extracellular matrix of chronic diabetic and venous ulcers versus acute wounds. *J Invest Dermatol* 1998;111:850–857.
- 61 Ehrlich HP, Desmoulière A, Diegelmann RF, Cohen IK, Compton CC, Garner WL, et al: Morphological and immunochemical differences between keloid and hypertrophic scar. *Am J Pathol* 1994;145:105–113.
- 62 Verhaegen PD, van Zuijlen PP, Pennings NM, van Marle J, Niessen FB, van der Horst CM, Middelkoop E: Differences in collagen architecture between keloid, hypertrophic scar, normotrophic scar, and normal skin: an objective histopathological analysis. *Wound Repair Regen* 2009;17:649–656.
- 63 Xi-Qiao W, Ying-Kai L, Chun Q, Shu-Liang L: Hyperactivity of fibroblasts and functional regression of endothelial cells contribute to microvessel occlusion in hypertrophic scarring. *Microvasc Res* 2009;77:204–211.
- 64 Aarabi S, Bhatt KA, Shi Y, Paterno J, Chang EI, Loh SA, et al: Mechanical load initiates hypertrophic scar formation through decreased cellular apoptosis. *FASEB J* 2007;21:3250–3261.
- 65 Darby IA, Bisucci T, Pittet B, Garbin S, Gabbiani G, Desmoulière A: Skin flap-induced regression of granulation tissue correlates with reduced growth factor and increased metalloproteinase expression. *J Pathol* 2002;197:117–127.
- 66 Bellemare J, Roberge C, Bergeron D, Lopez-Valle CA, Roy M, Moulin VJ: Epidermis promotes dermal fibrosis: role in the pathogenesis of hypertrophic scars. *J Pathol* 2005;206:1–8.
- 67 Dabiri G, Tumbarello DA, Turner CE, Van de Water L: Hic-5 promotes the hypertrophic scar myofibroblast phenotype by regulating the TGF-beta1 autocrine loop. *J Invest Dermatol* 2008;128:2518–2525.
- 68 Akaishi S, Ogawa R, Hyakusoku H: Keloid and hypertrophic scar: neurogenic inflammation hypotheses. *Med Hypotheses* 2008;71:32–38.
- 69 Sarrazy V, Billet F, Micallef L, Coulomb B, Desmoulière A: Mechanisms of pathological scarring: role of myofibroblasts and current developments. *Wound Repair Regen* 2011;19:s10–s15.