

# Wrist Arthroscopy under Portal Site Local Anesthesia (PSLA) without Tourniquet

Michael T. Y. Ong, MBChB., MRCS<sup>1</sup> P. C. Ho, MBBS, FRCS, FHKCOS, FHKAM<sup>1</sup>

Clara W. Y. Wong, MBChB, MRCS, FRCS, FHKCOS, FHKAM<sup>1</sup>

Sally H. S. Cheng, BMedSc, MBChB, MRCS, FHKCOS, FHKAM<sup>1</sup>

Wing- Lim Tse, MBChB, FRCS, FHKCOS, FHKAM<sup>1</sup>

<sup>1</sup>Department of Orthopaedic and Traumatology, Prince of Wales Hospital, Chinese University of Hong Kong, Shatin SAR, Hong Kong

**Address for correspondence and reprint requests** Michael TY Ong, M.B.Ch.B., M.R.C.S., Department of Orthopaedics and Traumatology, The Chinese University of Hong Kong, Clinical Science Building, Prince of Wales Hospital, Shatin, Hong Kong (e-mail: michaeltyong@hotmail.com).

J Wrist Surg 2012;1:149–152.

## Abstract

**Purpose:** wrist arthroscopy is typically performed under general or regional anesthesia with the aid of a tourniquet to maintain a bloodless field. We have been using portal site local anesthesia (PSLA) for wrist arthroscopy without a tourniquet since 1998. The aim of the study was to assess the efficacy, safety, and complications of PSLA and whether this can be recommended for routine wrist arthroscopy.

**Method:** We conducted a retrospective study, identifying 111 consecutive cases of wrist arthroscopies performed from January 2007 to December 2009. All cases were performed under PSLA. The effectiveness of PSLA was assessed by analyzing whether the procedure required adjuvant forms of anesthesia. The subjective effectiveness was assessed via phone questionnaires.

**Results:** Sixty-eight male and 43 female patients were identified. The average age was 43.2 (range 16–77). The indications included chronic wrist pain of unknown origin (30), posttraumatic arthritis (27), rheumatoid arthritis (5), ganglion (30), triangular fibrocartilage complex (TFCC) injury (14), infectious (1), and carpal instability (4). The average duration of the procedures was 73 minutes (range 20–255 minutes). Therapeutic procedures were performed in all 111 cases in addition to a routine diagnostic assessment. These included arthroscopic debridement (82) synovectomy (6), gangliectomy (30), TFCC repair (3), TFCC debridement (11), radial styloidectomy (2), wafer procedure (4), thermal shrinkage (2), distal scaphoidectomy (1), and synovial biopsy (4). All procedures could be completed uneventfully. Most patients tolerated the procedure well throughout the operation, and the satisfaction level was high. No complication was encountered.

**Discussions:** We concluded that PSLA technique is a feasible mode of anesthesia in selected patients. **Level of evidence:** Level IV

## Keywords

- ▶ wrist
- ▶ arthroscopy
- ▶ portal site
- ▶ local anesthesia

Wrist arthroscopy is typically performed under general or regional anesthesia with the aid of a tourniquet to maintain a bloodless field. Since the late 1970s, local anesthesia using intraarticular infiltration has been advocated for both diagnostic and therapeutic procedures in knee and ankle arthroscopy, with good results.<sup>1,2</sup> Nevertheless, the large volume of

anesthetic solution required for an effective procedure carries a potential risk.<sup>3</sup> Rolf et al described the technique of injecting anesthetic solution into the portal sites alone and reported satisfactory results.<sup>4</sup> We have been performing wrist arthroscopy under portal site local anesthesia (PSLA) without a tourniquet since 1998. The aim of the present study was to

assess the efficacy, safety, and complications of PSLA and whether this can be recommended for routine wrist arthroscopy.

## Materials and Methods

From January 2007 to December 2009, we performed wrist arthroscopy in 111 consecutive patients. All of the procedures were done under PSLA. There were 68 male and 43 female patients. The average age of the patients was 43.2 (range 16–77). The indications for surgery are summarized in **Table 1**.

Informed consent was obtained in all cases. Alternative options of anesthetic modes were also explained to the patients.

The patients reserved the right of aborting the procedure or requesting a shift to another method of anesthesia such as a regional intravenous block. After the procedure, the patients were discharged home after a short period of observation in the ward. Analgesic was prescribed on an “as-required” basis. A phone interview was performed postoperatively.

The phone interview questionnaire consists of two parts. The first part consisted of the patient demographics, including occupation, education level, hand dominance, and previous surgery.

The second part of the questionnaire consisted of patients comments regarding the procedure. This included the pain level experienced during surgery, using a visual analog scale (VAS) ranging from 0 to 10. Both pain scores at the worst moment and the average level were recorded, as well as the requirement for postoperative analgesia, and whether the patient would opt for the same anesthetic method for a second similar operation.

## Surgical Technique

No sedation was given to the patient preoperatively. We routinely used 1% lidocaine with 1:200,000 epinephrine, which was injected through a 25G needle into the various standard portal sites down to the level of the capsule with or without intraarticular infiltration. The patient’s response was observed throughout the procedure to monitor for any excessive discomfort.

**Table 1** Indications for surgery

Indication of Surgery	Number of Patients
Chronic wrist pain of uncertain origin	30
Posttraumatic arthritis	27
Rheumatoid arthritis	5
Ganglion	30
TFCC (triangular fibrocartilage complex) injury	14
Infective	1
Carpal instability	4

In case of significant patient discomfort a sterile pneumatic tourniquet was placed on the proximal forearm just below the elbow and forearm intravenous regional anesthesia (FIRA) was performed, typically with instantaneous onset. Most patients could predictably tolerate another 45–60 minutes of surgery before experiencing tourniquet discomfort. If necessary, the operative time could be further extended, by inflating another sterile tourniquet just distal to the original one and deflating the more proximal tourniquet. Alternatively, the procedure was aborted at the patient’s request.

## Results

All 111 cases of the series had some type of arthroscopic procedure including arthroscopic debridement (82) synovectomy (6), ganglionectomy (30), TFCC repair (3), TFCC debridement (11), radial styloidectomy (2), wafer procedure (4), thermal shrinkage (2), distal scaphoidectomy (1), and synovial biopsy (4) (**Figure 1**). The average duration of surgery was 73 minutes (range, 20 to 255 minutes). A median of 4 portals was employed (range, 2 to 6). Both the radiocarpal and midcarpal joints portals were used in 46 patients, while in 8 cases the distal radioulnar joint (DRUJ) was also inspected.

Six patients converted to FIRA after the diagnostic part of the arthroscopy. The decision was based on the operative findings and the surgeon’s judgment that the procedure would require a prolonged operative time (3) or an open procedure (3) which included TFCC repairs, arthroplasty, and ulnar shortening. None of the conversions was due to the patient’s inability to tolerate PSLA.

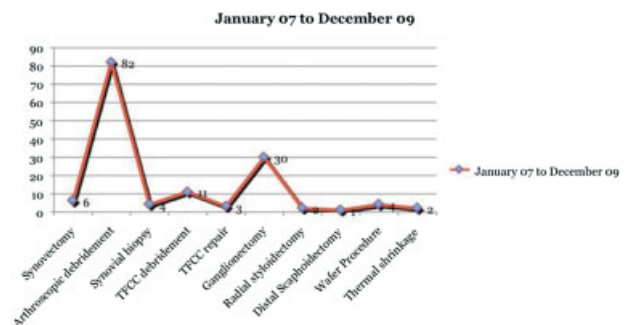
Of the 111 cases, only the six cases that were converted to FIRA required the use of a tourniquet.

There were no immediate or short-term surgical complications in this series.

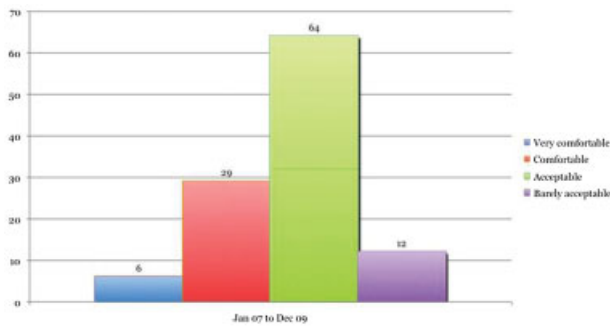
## Phone Interview

The affected wrist was the left in 67 cases and the right in 44 cases. Ninety-one patients were right-hand dominant, 71 patients were manual workers, 22 were nonmanual workers, and 8 were homemakers, 63 patients had undergone some type of previous surgery, 26 with local anesthesia, 31 with general anesthesia, and 6 with both.

The average VAS at the worst moment during the operation was 5.24 and the average during the surgery was 3.63,



**Fig. 1** Number and types of procedures performed.



**Fig. 2** Distribution of patients' reported levels of comfort.

Fifty-one reported sharp pain, 33 reported dull pain, 11 reported pain of a mixed nature, whereas 16 patients described no pain or discomfort at all.

When they were asked which part of the surgery was most uncomfortable, 64 reported the intraarticular instrumentation, 6 reported the finger traction system, 18 reported the injection of local anesthetic solution, 7 reported the introduction of the arthroscope into the joint, and 16 reported no discomfort at all. The overall rating was: very comfortable (6), comfortable (29), acceptable (64), and barely acceptable (12). Fifty-eight reported a better understanding of the condition after watching the procedure intraoperatively. Eighty-eight patients stated they would choose this method of anesthesia again, while 23 patients said they would opt for other methods (► **Fig. 2**).

## Discussion

Wrist arthroscopy is a relatively new procedure when compared with knee or ankle arthroscopy. Although Chen first described its clinical application in 1979,<sup>5</sup> it did not enjoy widespread use in the U.S. until after a 1986 wrist arthroscopy workshop organized by Whipple and Poehling et al.<sup>6</sup> With subsequent advances in technique and instrumentation, arthroscopic procedures such as ganglionectomy,<sup>7</sup> TFCC repair, and synovectomy became routine. However, it is still a general belief that wrist arthroscopy should be performed under general anesthesia with the aid of a tourniquet to maintain a bloodless field for clear visualization during the arthroscopic procedure. The inherent technical difficulty of performing arthroscopy within such a small joint and the intrinsic complexity of the wrist joint as a whole have led to skepticism about the feasibility of performing arthroscopy under local anesthesia, despite the fact that most such procedures nowadays are done in an outpatient setting. Inspired by the work of Rolf et al on using local anesthetic skin infiltration for knee and ankle arthroscopy (personal communication), the senior author (PCH) began using PSLA for wrist arthroscopy since 1998 at our institute. The first case was that of a male patient with a TFCC tear who had a history of prior drug addiction, and we had difficulty in establishing adequate venous access for an effective Bier block. We therefore switched to the PSLA technique. The patient showed a surprisingly high level of comfort during the operation even

when we performed a partial excision of a central flap tear of the TFCC. Subsequent experience on further patients confirmed the feasibility of this technique.

Our experience with PSLA has been remarkably successful, taking into account the wide variety of diagnoses and surgical procedures performed in this series with an overall success rate of 95%. One definite advantage of the present technique was the small amount of local anesthetic solution utilized, which was on average 5.7 mL of 1% lidocaine. The epinephrine mixture was very effective in achieving local hemostasis at the joint capsule and synovial level, avoiding the need for routine tourniquet use with the attendant pain due to muscle ischemia. The addition of epinephrine to the lidocaine solution also diminished the risk of local anesthetic toxicity. Adequate visibility and hemostasis could be maintained by continuous saline irrigation under gravity. Tourniquet use was reserved for the critical part of the procedure when more rigorous hemostasis was required, such as during synovectomy or a TFCC repair. We found that any maneuver that created excessive stretching of the volar capsular ligaments could induce sharp pain such as decompression of a volar wrist ganglion, which was managed by local infiltration of the volar radiocarpal ligaments through the dorsal portals. We also found that sedation was not necessary to achieve good results, in contrast to most of the published series on knee surgery which made it possible to include the patient in the decision making during the surgical procedure. It also allowed us to check the active tendon motion and peripheral nerve function intermittently during the therapeutic procedures. For example, during thermal shrinkage of the ulnar extrinsic ligament structures for palmar midcarpal instability, the surgeon could monitor the function of the ulnar nerve and the extensor tendon of the little finger, which have been known to be prone to iatrogenic injury from excessive thermal energy.

Multiple previous reports have also advocated allowing a delay of 20 to 90 minutes from the injection of anesthesia to the onset of surgery to achieve a sufficient anesthetic effect. However, our experience showed that the use of short and fast-acting lidocaine could allow almost immediate surgery.

We do realize that a certain level of patient discomfort is inherent in this procedure. Of the 111 patients, 64 found the pain to be acceptable, whereas 12 found the pain to be barely acceptable. We acknowledge that our patient population was very compliant with the surgeon's wishes, since they were not given the choice of anesthetic type preoperatively—every patient who underwent arthroscopy was enrolled, even though there was no clear medical condition that mandated PSLA. We recommend that there should be a preoperative discussion with the patient as to risks and benefits of this procedure as well as the level of discomfort that could be expected.

Limitations of this study include the fact that it is a retrospective review, which is prone to bias, especially since the patients had to recollect a procedure they had undergone several years earlier. Also, the purpose of this review was to report the successful experience we have with PSLA; hence, direct comparison with other methods of anesthesia was not performed.

## References

- 1 Yoshiya S, Kurosaka M, Hirohata K, Andrich JT. Knee arthroscopy using local anesthetic. *Arthroscopy* 1988;4(2):86–89
- 2 Jacobson E, Forssblad M, Rosenberg J, Westman L, Weidenhielm L. Can local anesthesia be recommended for routine use in elective knee arthroscopy? A comparison between local, spinal, and general anesthesia. *Arthroscopy* 2000;16(2):183–190
- 3 Jacobs TF, Vansintjan PS, Roels N, et al. The effect of lidocaine on the viability of cultivated mature human cartilage cells: an in vitro study. *Knee Surg Sports Traumatol Arthrosc* 2011;19(7):1206–1213
- 4 Rolf CG. Knee arthroscopy under local anaesthesia. *Hong Kong J Orthop Surg* 1998;2(2):158–163
- 5 Chen YC. Arthroscopy of the wrist and finger joints. *Orthop Clin North Am* 1979;10(3):723–733
- 6 Roth JH, Poehling GG, Whipple TL. Arthroscopic surgery of the wrist. *Instr Course Lect* 1988;37:183–194
- 7 Ho PC, Law BK, Hung LK. Arthroscopic volar wrist ganglionectomy [in French]. *Chir Main* 2006;25(Suppl 1):S221–S230