

# Zika virus-associated neurological disorders: a review

Abelardo Q. C. Araujo,<sup>1,2</sup> Marcus Tullius T. Silva<sup>1</sup> and Alexandra P. Q. C. Araujo<sup>3</sup>

---

Zika virus, an arbovirus transmitted by mosquitoes of the *Aedes* species, is now rapidly disseminating throughout the Americas and the ongoing Brazilian outbreak is the largest Zika virus epidemic so far described. In addition to being associated with a non-specific acute febrile illness, a number of neurological manifestations, mainly microcephaly and Guillain-Barré syndrome, have been associated with infection. These with other rarer neurological conditions suggest that Zika virus, similar to other flaviviruses, is neuropathogenic. The surge of Zika virus-related microcephaly cases in Brazil has received much attention and the role of the virus in this and in other neurological manifestations is growing. Zika virus has been shown to be transmitted perinatally and the virus can be detected in amniotic fluid, placenta and foetus brain tissue. A significant increase in Guillain-Barré syndrome incidence has also been reported during this, as well as in previous outbreaks. More recently, meningoencephalitis and myelitis have also been reported following Zika virus infection. In summary, while preliminary studies have suggested a clear relationship between Zika virus infection and certain neurological conditions, only longitudinal studies in this epidemic, as well as experimental studies either in animal models or *in vitro*, will help to better understand the role of the virus and the pathogenesis of these disorders.

- 1 Laboratory for Clinical Research in Neuroinfections (Lapclin-Neuro), The Evandro Chagas National Institute Of Infectious Diseases (INI), FIOCRUZ, Avenida Brasil 4365, CEP 21040-360, Rio de Janeiro - RJ, Brazil
- 2 The Deolindo Couto Institute of Neurology (INDC), The Federal University of Rio de Janeiro (UFRJ), Avenida Venceslau Bras 95, CEP 21941-901, Rio de Janeiro - RJ, Brazil
- 3 Neuropaediatrics Unit, the Martagão Gesteira Institute of Child Health and Paediatrics (IPPMG), The Federal University of Rio de Janeiro (UFRJ), Rua Bruno Lobo 50, CEP 21941-912, Rio de Janeiro - RJ, Brazil

Correspondence to: Prof. Abelardo Q. C. Araujo, MD, MSc, PhD,  
Laboratory for Clinical Research in Neuroinfections (Lapclin-Neuro),  
The Evandro Chagas National Institute Of Infectious Diseases (INI),  
FIOCRUZ, Brazilian Ministry of Health,  
Avenida Brasil 4365, CEP 21040-360,  
Rio de Janeiro - RJ, Brazil  
E-mail: abelardo@ufrj.br

**Keywords:** Zika virus; arbovirus; microcephaly; Guillain-Barré syndrome; neurological complications

**Abbreviations:** CDC = Centre for Disease Control and Prevention; CHIKV = Chikungunya virus; DENV = Dengue virus; GBS = Guillain-Barré syndrome; JEV = Japanese encephalitis virus; WHO = World Health Organization; WNV = West Nile virus; ZIKV = Zika virus

## Introduction

Zika virus (ZIKV) was first isolated in the Zika forest of Uganda from a sentinel Rhesus monkey with an acute

febrile illness in 1947 (Dick *et al.*, 1952). Human infection was first subsequently detected in Nigeria (Macnamara, 1954); however, in the period up to 2007, only sporadic and mild cases of associated clinical disease were reported

from Africa and Southeast Asia. In 2007 a major outbreak occurred in the Yap Islands in Micronesia with almost three-quarters of inhabitants being infected (Duffy *et al.*, 2009). Subsequent epidemics occurred in Southeast Asia and throughout the Pacific Ocean Islands (Ioos *et al.*, 2014). The apparently benign nature of ZIKV infection was challenged in an outbreak in French Polynesia, which began in October 2013, where a significant number of individuals developed Guillain-Barré syndrome (GBS) and other autoimmune complications in association with concurrent circulation of Dengue virus (DENV) (Ioos *et al.*, 2014).

Following spread throughout the Pacific, the virus was subsequently detected in mid-2015 in Brazil, which has now become home of the largest outbreak of ZIKV with ~30 000 clinical cases reported to date (Faria *et al.*, 2016) and by the third week of 2016, 22 of the 26 Brazilian states had confirmed ZIKV infection. The total number of infected individuals is unknown and expected to reach more than one million cases. Phylogenetic analyses suggest a single introduction of ZIKV into the Americas, estimated to have occurred between May and December 2013, more than 12 months prior to the first detection of ZIKV in Brazil. The estimated date of origin coincides with an increase in air travel passengers to Brazil from ZIKV endemic areas in the Pacific Islands (Faria *et al.*, 2016).

The first neurological complications possibly associated with the Brazilian ZIKV outbreak were reported in July 2015, when health authorities notified the Brazilian Ministry of Health (MoH) of an increase in the number of cases of GBS in the state of Bahia in North-Eastern Brazil (Bahia, 2015). Subsequently the World Health Organization (WHO) was informed of an increase in cases of GBS in other South American countries (WHO, 2016b, d). In October 2015, there were reports of an increase in the number of children born with microcephaly in the Brazilian North-Eastern state of Pernambuco with subsequent notification to the WHO (Brasil, 2015). As of December 2015, Brazilian Health authorities reported the occurrence of 2975 suspected cases of microcephaly (99.7/100 000 live births) possibly related to maternal ZIKV infection (Brasil, 2016b) and most of these cases were concentrated in North-Eastern states, where ZIKV was—at the time—more prevalent (WHO, 2016d).

As of February 2016, 25 countries and territories from the Americas, Africa and Asia have reported ZIKV infection and the virus is now rapidly disseminating throughout the Americas, and in particular in Venezuela, Cabo Verde, Colombia, El Salvador, Martinique and Panama (2016a).

In January 2016, the Centre for Disease Control and Prevention (CDC) activated its Emergency Operations Centre to respond to the outbreaks of ZIKV in the Americas and the increased reports of birth defects and GBS. On 1 February 2016, the WHO declared a public health emergency of international concern because of the clusters of microcephaly and other neurological disorders in areas affected by ZIKV (WHO, 2016c). On 8 February

2016, CDC elevated its Emergency Operations Centre to a Level 1, the highest level (CDC, 2016a) and this led European and North-American health authorities to advise pregnant women in any trimester to postpone travel to any area where ZIKV was occurring and the use of condoms to prevent sexual transmission of the virus (CDC, 2016b).

References for this Update were identified by searches of PubMed between 1952 and 21 May 2016 using MeSH search terms. ZIKV information was also gathered from online official bulletins and newsletters of the Brazilian MoH, WHO, Pan-American Health Organization (PAHO) and CDC.

## Zika virus

ZIKV is a member of the genus *Flavivirus* of the *Flaviviridae* family, which is classified as an arthropod-borne (arbovirus) and includes Dengue (DENV), West Nile (WNV), Yellow Fever (YFV), and Japanese Encephalitis (JEV) viruses, among others. Another arbovirus, the Chikungunya virus (CHIKV), although a member of a different family (*Togaviridae*), causes similar clinical symptoms to DENV and ZIKV.

ZIKV, DENV and CHIKV are transmitted primarily through the bite of infected *Aedes* species mosquitoes. There is also evidence that ZIKV may be transmitted from mother to child (transplacental infection) (Besnard *et al.*, 2014). Other routes of transmission, such as through blood transfusion and sexual contact also occur, but are much more rare (Musso *et al.*, 2014, 2015).

The classical ZIKV syndrome is similar to, but usually milder than DENV fever. It is characterized by fever, rash, arthralgia, and conjunctival hyperaemia (Duffy *et al.*, 2009). ZIKV syndrome has always been considered a benign and self-limited exanthematic disease with symptoms disappearing after 3–7 days, except for arthralgia, which can persist for up to 1 month. Arboviruses are also known to be neurotropic. Table 1 summarizes and compares the main clinical and neurological syndromes associated with main arboviruses of interest to the present update.

The serological diagnosis of ZIKV can be challenging because of cross-reactivity with other flaviviruses. During the first week following symptoms, ZIKV can be diagnosed by detection of viral RNA using reverse transcriptase-polymerase chain reaction (RT-PCR) in blood but viral RNA and viable viruses can also be detected in urine, saliva, semen and vaginal secretion for up to 30 days (Ribeiro *et al.*, 2016). Therefore, these specimens represent an alternative for late diagnosis. Virus-specific IgM and neutralizing antibodies typically develop toward the end of the first week of illness. Plaque-reduction neutralization testing (PRNT) can be performed to measure virus-specific neutralizing antibodies and discriminate between cross-reacting antibodies in primary flavivirus infections (CDC, 2016b).

**Table 1 Clinical and neurological findings of the most common arboviruses**

Virus/symptoms	Zika virus	Dengue virus	Chikungunya virus	West Nile virus
Fever	+	++++	++++	++
Rash	++++	++	++	++
Myalgia	++	+++	++	++
Arthralgia	++	+	++++	+
Peri-articular oedema	++	+	+++	-
Conjunctival hyperaemia	+++	+	+	++
Headache	++	+++	++	
Neurological syndromes	Microcephaly, GBS, meningoencephalitis, myelitis	Encephalopathy, seizures, GBS, mononeuropathy, myelitis	Meningoencephalitis, acute flaccid paralysis, GBS, sensorineural hearing loss	Meningitis, encephalitis, acute flaccid paralysis, brachial plexopathy, demyelinating neuropathy, motor axonopathy, axonal polyneuropathy, motor radiculopathy, myasthenia gravis, cranial nerve palsies

The PRNT method may be more specific than IgM ELISA, particularly in areas with co-circulation of flaviviruses. In addition to a positive RT-PCR, a positive IgM or an increase in the titre of neutralizing antibodies is indicative of ZIKV infection. Finally, it has been suggested that pregnant women may have a positive RT-PCR, which persists longer than other infected individuals, a finding that must be confirmed in larger studies (Driggers *et al.*, 2016).

## Congenital ZIKV syndrome

Microcephaly is a frequent clinical sign common in many rare genetic diseases and can also be observed following certain congenital infections. In November 2015 a new notification system was introduced in Brazil, which was specific for children with small head circumference measured at birth, following the report that the number of microcephaly cases was apparently higher than expected in the Northeast region of the country (Brasil, 2015). The emergence of both ZIKV infection in Brazil and the increase in numbers of congenital microcephaly cases, together with evidence of perinatal transmission (Besnard *et al.*, 2014) raised the hypothesis of a link between infection and this condition. Based on this possible association, the WHO made specific recommendations (WHO, 2016c) and the Brazilian MoH implemented new microcephaly case report definitions (Brasil, 2015). The Brazilian MoH proposed that a suspected case may be confirmed after exclusion of other causes of microcephaly, infectious or otherwise, and laboratory evidence of ZIKV infection. The definition for notification purposes was changed for newborns by the end of 2015 to a head circumference at birth  $\leq 32$  cm. In March 2016, WHO criteria were adopted, 31.7 cm for boys and 31.5 cm for girls and it is possible that this change could potentially decrease the number of reported cases (Brasil, 2016b).

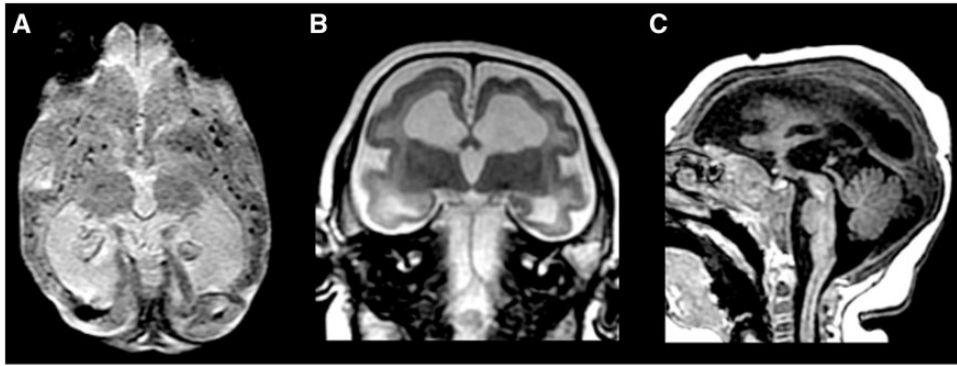
According to the Brazilian national notification system the accumulated number of microcephaly cases in Brazil, regardless of the aetiology, from 8 November 2015 to 23

April 2016 was 7228 cases (Brasil, 2016a). Of these, 194 were confirmed as ZIKV-associated microcephaly based on positive tests for ZIKV, either by RT-PCR or serology. One thousand and four additional cases had confirmation based on brain imaging (calcification, ventricular dilatation, posterior fossa abnormalities). Additionally, in retrospect, health authorities in French Polynesia also reported an increase of CNS malformations following their local ZIKV outbreak (E.C.D.C., 2015).

Perinatal transmission of ZIKV had already been described in late gestation, in two mothers with rash and fever and with a favourable outcome in their newborns (Besnard *et al.*, 2014), and it is already known that the virus can be detected in amniotic fluid (Calvet *et al.*, 2016; Oliveira Melo *et al.*, 2016). Importantly, a longitudinal cohort of pregnant women with reported rash has shown a high positivity for ZIKV RNA by RT-PCR (82%), and for DENV-specific IgG antibodies (88%). Abnormal ultrasonography was observed in one-third of these women (Brasil *et al.*, 2016c).

Presumed congenital ZIKV infection (de Fatima Vasco Aragao *et al.*, 2016) reported in a case series of 23 children was associated with craniofacial disproportion, redundant occipital scalp skin and brain imaging abnormalities. Decreased brain volume, ventriculomegaly, malformation of cortical development, calcifications in the junction between the cortical and subcortical white matter and enlarged cisterna magna were present in those children on MRI or CT scan. A previous report of possible associated ZIKV microcephaly also noted similar imaging features, and in addition noted the presence of arthrogryposis in 11% of those children (Schuler-Faccini, 2016). **Figure 1** shows the MRI features described above.

Ocular abnormalities have also been reported as part of the congenital ZIKV syndrome. Focal pigment mottling and chorioretinal atrophy, optic nerve abnormalities (hypoplasia with double-ring sign, pallor, and/or increased cup-to-disk ratio), lens subluxation and coloboma were the main findings (de Paula Freitas *et al.*, 2016; Ventura *et al.*, 2016). These retinal lesions differ from other



**Figure 1 Brain MRI from a 3-month-old infant born with microcephaly.** Mother had ZIKV infection at 12 weeks gestation and ultrasound carried out at the end of gestation showed reduced head circumference. The child was born prematurely (34 weeks), APGAR score = 9/9, head circumference = 27 cm. The infant is being followed by one of the authors (A.P.Q.C.A.). (A) Calcifications; (B) cortical development malformation; (C) posterior fossa malformation and redundant skin.

congenital infections in their predisposition for involvement of the macular area.

Autopsy reports include that of a foetus of a pregnancy interrupted at Week 29, whose mother had a rash on Week 13 (Mlakar *et al.*, 2016), and that of four newborns with microcephaly (Martines *et al.*, 2016). Virus-like particles were found in damaged cytoplasmic vesicles on electron microscopy in foetus formalin-fixed cerebral tissue, which were RT-PCR positive for ZIKV RNA and positive on RT-PCR and immunohistochemistry performed on paraffin-embedded placenta and brain samples, respectively.

Perinatal transmission of arboviruses is well known to occur and has been described not only for ZIKV (Besnard *et al.*, 2014), but also for WNV (O'Leary *et al.*, 2006) and CHIKV (Ramful *et al.*, 2007). For DENV, only antibody placental transfer has been shown to occur (Argolo *et al.*, 2013). However, DENV RNA has been detected by RT-PCR in breast milk (Barthel *et al.*, 2013).

In newborn and young mice, intracerebral inoculation has demonstrated that ZIKV replication occurs both in neurons and astroglial cells. There is a predilection for localization of infection in Ammon's horn, but with only moderate perivascular cuffing. Some authors have suggested the possibility of a direct viral role in neuronal destruction, as well as indirect elimination through immunological mechanisms (Bell *et al.*, 1971). The involvement of the nervous system by other flaviviruses is well known from animal models. Intrauterine infection of pregnant mice with St. Louis encephalitis (SLE) virus has been associated with foetal death, encephalocoele, hydrocephalus, and behavioural and memory changes in surviving mice (Andersen and Hanson, 1975). JEV can be transmitted via the placenta from inoculated pregnant mice to the foetus, resulting in a significant risk of abortion. Noteworthy, JEV transmission was observed even at 6 months after inoculation and in spite of the presence of specific antibodies. Two intriguing questions arising from these findings are how and where the virus persists, and what are the mechanisms involved in reactivation (Mathur

*et al.*, 1982). More recently, WNV was shown to be able to infect the mouse foetus according to differentiation status of syncytiotrophoblasts, specifically the number of foetuses infected with WNV was greater if pregnant mice were infected early, before placenta maturation. Thus, differentiated syncytiotrophoblasts of the maturing placenta could act as a barrier to foetal infection by WNV (Julander *et al.*, 2006).

Recently, experimental studies have shed more light on the neuropathogenesis of the congenital ZIKV syndrome. In experimental models, ZIKV targets human brain cells, reducing their viability and growth. These results suggest that ZIKV abrogates neurogenesis during human brain development (Garcez *et al.*, 2016). Cultured progenitor cells infected by ZIKV demonstrated the presence of viral particles and cells showed apoptotic nuclei on electron microscopy. These cells are productively infected, which results in increasing numbers of infected cells over time (Qian *et al.*, 2016). There is also a downregulation of genes involved in cell-cycle pathways, dysregulation of cell proliferation, and upregulation of genes involved in apoptotic pathways, resulting in cell death (Tang *et al.*, 2016). Additionally, *in vivo* infected embryonic mouse brains (Li *et al.*, 2016) and pregnant mice (Cugola *et al.*, 2016; Miner and Diamond, 2016; Wu *et al.*, 2016) not only confirmed the aforementioned observations, but also replicated the outcomes seen in humans with placental insufficiency (Miner *et al.*, 2016), and brain and ocular abnormalities (Cugola *et al.*, 2016; Li *et al.*, 2016).

## Guillain-Barré syndrome and ZIKV

GBS is an autoimmune neurological complex embracing several diseases that share some similarities but which differ in relation to their underlying pathogenesis and clinical manifestations (Hughes and Cornblath, 2005). In two-thirds of cases, GBS is triggered by a prior infection, most

frequently respiratory or gastrointestinal (Wakerley and Yuki, 2013).

GBS has been associated with prior infections by DENV (Solomon *et al.*, 2000), CHIKV (Wielanek *et al.*, 2007) and, most recently, by ZIKV (Cao-Lormeau *et al.*, 2016). DENV infection preceding GBS has been described in case reports and in a series of patients presenting with various neurological manifestations, including acute motor axonal neuropathy (Sharma *et al.*, 2011; Carod-Artal *et al.*, 2013). The demonstration of IgM antibodies against DENV in the CSF and reports of virus isolation from brain tissue and CSF suggest direct virus invasion of the nervous system and highlights the potential neurotropism of DENV (Chimelli *et al.*, 1990; Solomon *et al.*, 2000). An increase in GBS incidence was also observed during an outbreak of CHIKV in French Polynesia (Oehler *et al.*, 2015).

From October 2013 to April 2014, more than 32 000 suspected cases of ZIKV infection were reported in French Polynesia, and in March 2014 the first GBS case associated with ZIKV was published (Oehler *et al.*, 2014; Santé, 2014). Subsequently, 42 cases of GBS and 25 cases of other neurological complications (encephalitis, meningo-encephalitis, facial paralysis, and myelitis) were reported to local health authorities (WHO, 2016e). Recently, the first case-control study describing clinical and electrophysiological characteristics of these patients has been published (Cao-Lormeau *et al.*, 2016). GBS cases were matched with patients who presented with a non-febrile illness (control group 1) and with patients with acute ZIKV but without neurological symptoms (control group 2). Ninety-eight per cent of patients with GBS tested positive for ZIKV infection (IgG and IgM) and 100% had neutralizing antibodies against ZIKV, compared to 56% of patients from control group 1. Previous infection by DENV was found in 95% of GBS patients, but this did not differ from controls. The estimated incidence of GBS in this outbreak was 0.24 per 1000 ZIKV infected individuals. The main characteristics of GBS noted by the authors were rapid progression to nadir (median of 6 days between the onset of the neurological symptoms to the nadir), and the short plateau phase (median of 4 days), both shorter than what has been described in other series of GBS. Generalized muscle weakness (74% of patients), facial palsy (64%), and inability to walk (44%) were the most common clinical presentations. Respiratory assistance was required by 29% of patients and 93% had an increased protein level in the CSF analysis. All patients received intravenous immunoglobulin treatment, and 3 months after discharge 57% were able to walk without assistance. Thirty-seven of 42 GBS patients had an electrophysiological examination performed in the first week of the neurological complaints. Prolonged distal latencies and reduction of the distal compound muscle action potential (CMAP) amplitude in motor nerve conduction studies were found, suggesting a severe conduction abnormality in distal nerve segments. Substantial conduction slowing or block in intermediate motor nerve segments was not observed. The amplitude and conduction velocity

of sensitive nerves were essentially normal. A second electrophysiological study performed 4 months later showed an improvement of the distal conduction abnormalities with reduction of the prolonged distal latencies and near normalization of CMAP amplitudes. Together, these findings are suggestive of acute motor axonal neuropathy. A positive reaction against different glycolipids was detected in 23, and most had reactivity directed towards glycolipid GA1 (17 patients). However, in <50% of these individuals this reactivity was unequivocal, different from what is observed in classical *Campylobacter*-associated acute motor axonal neuropathy. Thus, there might be other auto-antibodies in ZIKV-associated GBS that have yet to be identified. The authors did not find any competition between GA1 and ZIKV proteins, which suggests the absence of antigenic mimicry between ZIKV antigens and GA1 and questions the role of anti-GA1 antibodies in ZIKV-associated GBS pathogenesis. The authors speculated that the Polynesian disease was not mediated by anti-glycolipid antibodies, but rather induced by other autoantibodies or by unknown neurotoxic factors associated with ZIKV infection. This should now be explored in other studies. Other differences from classical acute motor axonal neuropathy patients are: (i) in ZIKV infection 79% of individuals had facial palsy, which is more common in acute inflammatory demyelinating polyradiculopathy; and (ii) severity was different from classical cases as no fatalities were observed and full recovery occurred after 3 months in 57% (Cao-Lormeau *et al.*, 2016). Finally, it is well known that antibodies against gangliosides play a role in the pathogenesis of GBS (Willison and Yuki, 2002). Recently, it was demonstrated that there is a high peptide overlap between the ZIKV polyprotein and human proteins related to myelin, demyelination, and axonal neuropathy. This finding further supports cross-reactivity as a potential pathogenic mechanism associating ZIKV infection with GBS (Lucchese and Kanduc, 2016).

Between January and November 2015, the WHO reported 1708 cases of GBS in Brazil, which represents a 19% average increase from the previous year (WHO, 2016a, d). However, this must be interpreted with caution because GBS has never been a mandatory reportable disease in Brazil. In addition the large majority of these cases were not tested for ZIKV infection. Moreover the diagnostic and/or exclusion criteria used to classify these cases as GBS is unclear. Following these reports from Brazil, WHO reported a similar increase in cases of GBS in Colombia, El Salvador, Suriname and Venezuela (WHO, 2016b, d).

The reasons for the increase in the incidence of GBS observed in Brazil, El Salvador, and Suriname are unknown, particularly because potentially other agents and specifically DENV, CHIKV and ZIKV might be involved have all been co-circulating in these countries. In addition, as already noted, the criteria used for classifying these cases as GBS are unknown, and similarly the ZIKV infection status is unclear. Aetiological investigations are still ongoing.

## Other neurological manifestations and ZIKV

Acute myelitis was recently described 7 days after ZIKV infection in a teenage girl from Guadeloupe. Spinal MRI disclosed enlargement and hypersignalling in the thoracic and cervical spinal cord. ZIKV RNA was detected in serum, urine, and CSF on the second day of the neurological complaints, and 9 days after the onset of the clinical symptoms by RT-PCR. She was treated with methylprednisolone 1 g daily for 5 days, with clinical and radiological improvement. The presence of ZIKV in the CSF reinforces the hypothesis that ZIKV virus is neurotropic (Mecharles *et al.*, 2016).

Meningoencephalitis during the course of ZIKV infection was also recently described in an 81-year-old male. He presented both febrile and comatose 10 days after returning from New Caledonia. A brain MRI suggested meningoencephalitis. CSF analysis showed 41 leucocytes (98% polymorphonuclear cells), a protein level of 76 mg/dl, and a CSF/blood glucose ratio of 0.75. ZIKV was diagnosed by RT-PCR and viral culture from the CSF. All these findings supported the diagnosis of a ZIKV-associated meningoencephalitis (Carteaux *et al.*, 2016).

## Discussion

From October 2015, when the first cases of presumably ZIKV-associated microcephaly cases in Brazil were noted, up to the present time, a number of investigations have been carried out to better understand this phenomenon. *In vitro* cultured progenitor neuronal cells infected with ZIKV demonstrate viral particles suggesting active virus replication and cells showed apoptotic nuclei (Garcez *et al.*, 2016). From observational studies it is known that the virus disseminates in pregnant females to the amniotic fluid and foetal tissues (Besnard *et al.*, 2014; Calvet *et al.*, 2016; Oliveira Melo *et al.*, 2016). In terminated gestations, foetus brain histopathology studies demonstrate apoptosis predominately in intermediately differentiated post-migratory neurons in the neocortex, as well as white matter axonal rarefaction and macrophage infiltration. On electron microscopy viral-like particles are found in the same tissues (Driggers *et al.*, 2016; Martines *et al.*, 2016; Mlakar *et al.*, 2016). Pre-natal ultrasound and Doppler studies also have shown either placental insufficiency or foetal brain abnormalities (Brasil *et al.*, 2016c). Newborns may present both with microcephaly and ocular findings (de Paula Freitas *et al.*, 2016; Schuler-Faccini *et al.*, 2016; Ventura *et al.*, 2016) and imaging of the brain in those children show junctional brain calcification on CT scans and malformations of cortical development on MRI studies (de Fatima Vasco Aragao *et al.*, 2016). Finally and remarkably, pregnant women, different from non-pregnant subjects,

show the persistence of ZIKV by RT-PCR in blood for weeks after the acute infection (Driggers *et al.*, 2016).

The possible association of ZIKV infection and microcephaly has been suggested since October 2015 because mothers of those babies, in retrospect, referred to a rash at some time-point in their pregnancies. The presence of calcification on the brain images of most of those microcephaly cases was another factor to support this association. Cutaneous rash has a large differential diagnosis, as is also true for microcephaly and calcification. The precise causes for both conditions have yet to be thoroughly explored in Brazil. In Brazil, urine PCR for cytomegalovirus is not carried out routinely. This is also true for genetic testing, such as array comparative genomic hybridization analysis. These are required to exclude other specific causes of microcephaly and as such caution is required before definitively associating ZIKV and certain cases of microcephaly. The presence of the virus in different tissues and body fluids increases the possible relation of infection and the clinical findings but does not establish a definitive causal association. However, the association with infection has strong support and specific phenotypes have been characterized for both foetuses and newborns. Nevertheless further epidemiologic and pathogenetic studies are required.

Factors involved in permitting the virus to spread so impressively in the foetus are still unknown, as are the reasons for its prolonged persistence in pregnant women. The frequency of morbidity in vertical infection is yet to be determined, as well as the timing of acute infection during pregnancy, which might be associated with different foetal outcomes. Longitudinal studies should provide clarification on this. Additionally, further experimental congenital infection with ZIKV in animal models and in cultured human brain cells will help in our understanding of the pathogenesis of this virus in developmental nervous system disorders.

The only report with reliable information on the diagnostic criteria used to identify suspect GBS cases associated with ZIKV infection has been the one from French Polynesia. As there are neither pathognomonic clinical characteristics nor biomarkers available, the distinction between GBS and other similar diseases (acute myelitis, Lyme disease, tick paralysis, myasthenia gravis, botulism, acute polymyositis) may be challenging, particularly in places with poor diagnostic resources. Future research in this field should adopt standardized clinical criteria for GBS such as proposed by the Brighton Collaboration GBS Working Group (Fokke *et al.*, 2014).

Neurological diseases other than GBS have been observed in some ZIKV outbreaks (WHO, 2016d). It is worth remembering that other circulating viruses, such as WNV, may cause neurological syndromes, including GBS, in some of these countries (Vieira *et al.*, 2015a, b). Thus it is important to exclude other infectious agents such as WNV, DENV, and CHIKV as factors or cofactors for the development of neurological complications. This is essential particularly in regions where these viruses coexist. In Brazil,

for example, most suspected cases of ZIKV, DENV, and CHIKV have not been confirmed by laboratory testing.

## Conclusions

Until recently ZIKV was considered an infectious agent of relatively minor importance. However, there are now serious concerns following its rapid dissemination that it may be associated with serious neurological complications. The public health and economic implications of this outbreak cannot be minimized. The emergency of an epidemic of microcephaly is of great concern for countries with relatively high birth rates and the medical, economical and psychological burdens experienced by families are worsened by ailing health systems, which cannot adequately deal with the current outbreaks. In addition, ethical and social implications have to be taken into consideration, particularly in countries in which abortion is restricted to very specific circumstances or even totally prohibited. The consequences of a GBS outbreak are also of concern as this may overwhelm the health systems, which may not be able to respond quickly and efficiently to an increased population of patients needing continued hospitalization support and specific and expensive treatments.

No vaccine is available against ZIKV, and this and the development of new therapeutic approaches should be one of the priorities for future research. All potential drugs must be safe for use in pregnancy. In the interim, priority interventions must include effective new methods for vector control and simultaneously, the development of better and rapid diagnostic tools. Finally, more experience will be needed to understand how to best address newborn babies with severe and disabling congenital malformations (Barreto *et al.*, 2016; Calvet *et al.*, 2016).

## Funding

No funding was received towards this work.

## Acknowledgement

We are grateful to Professor William W. Hall, MD, PhD (CRID, University College Dublin, Ireland) for his useful suggestions. We thank Dr. Lara Brandão, MD (Clinica Radiologica Felipe Mattoso, Rio de Janeiro, Brazil), for the MRI report of the microcephaly case.

## References

Andersen AA, Hanson RP. Intrauterine infection of mice with St. Louis encephalitis virus: immunological, physiological, neurological, and behavioral effects on progeny. *Infect Immun* 1975; 12: 1173–83.

Argolo AF, Feres VC, Silveira LA, Oliveira AC, Pereira LA, Junior JB, et al. Prevalence and incidence of dengue virus and antibody

placental transfer during late pregnancy in central Brazil. *BMC Infect Dis* 2013; 13: 254.

Bahia SdS. Panorama na Bahia. Dengue, Chikungunya e Zika. 6 de Julho de 2015. 2015. <[http://www.saude.ba.gov.br/novoportal/index.php?option=com\\_content&view=article&id=9497:panorama-na-bahia&catid=98:dengue-zika-chikungunya-e-sgb](http://www.saude.ba.gov.br/novoportal/index.php?option=com_content&view=article&id=9497:panorama-na-bahia&catid=98:dengue-zika-chikungunya-e-sgb)> (19 February 2016, date last accessed).

Barreto ML, Barral-Netto M, Stabeli R, Almeida-Filho N, Vasconcelos PF, Teixeira M, et al. Zika virus and microcephaly in Brazil: a scientific agenda. *Lancet* 2016; 387: 919–21.

Barthel A, Gourinat AC, Cazorla C, Joubert C, Dupont-Rouzeyrol M, Descloux E. Breast milk as a possible route of vertical transmission of dengue virus? *Clin Infect Dis* 2013; 57: 415–17.

Bell TM, Field EJ, Narang HK. Zika virus infection of the central nervous system of mice. *Arch Gesamte Virusforsch* 1971; 35: 183–93.

Besnard M, Lastere S, Teissier A, Cao-Lormeau V, Musso D. Evidence of perinatal transmission of Zika virus, French Polynesia, December 2013 and February 2014. *Euro Surveill* 2014; 19. pii: 20751.

Brasil MdSd. Situação epidemiológica de ocorrência de microcefalias no Brasil, 2015. *Boletim Epidemiológico* 2015; 46: 1–3.

Brasil MdSd. Informe Epidemiológico n. Semana Epidemiológica (SE) 16/2016 (17/04 a 23/04/2016). Monitoramento de casos de microcefalia no Brasil. 2016a. [http://combataedes.saude.gov.br/imagens/sala-de-situacao/informe\\_microcefalia\\_epidemiologico23.pdf](http://combataedes.saude.gov.br/imagens/sala-de-situacao/informe_microcefalia_epidemiologico23.pdf) (21 May 2016, date last accessed).

Brasil MdSd. Monitoramento dos casos de microcefalia no Brasil até a semana Epidemiológica 51/2015. *Boletim Epidemiológico* 2016b; 47: 1–4.

Brasil P, Pereira JP Jr, Raja Gabaglia C, Damasceno L, Wakimoto M, Ribeiro Nogueira RM, et al. Zika virus infection in pregnant women in Rio de Janeiro - Preliminary Report. *N Engl J Med* 2016c. 10.1056/NEJMoa1602412

Calvet G, Aguiar RS, Melo AS, Sampaio SA, de Filippis I, Fabri A, et al. Detection and sequencing of Zika virus from amniotic fluid of fetuses with microcephaly in Brazil: a case study. *Lancet Infect Dis* 2016; 16: 653–60.

Cao-Lormeau VM, Blake A, Mons S, Lastere S, Roche C, Vanhomwegen J, et al. Guillain-Barre Syndrome outbreak associated with Zika virus infection in French Polynesia: a case-control study. *Lancet* 2016; 387: 1531–39.

Carod-Artal FJ, Wichmann O, Farrar J, Gascon J. Neurological complications of dengue virus infection. *Lancet Neurol* 2013; 12: 906–19.

Carteaux G, Maquart M, Bedet A, Contou D, Brugières P, Fourati S, et al. Zika virus associated with meningoencephalitis. *N Eng J Med* 2016. 374: 1595–6.

CDC. Areas with Zika. 2016a. <<http://www.cdc.gov/zika/geo/index.html>> (13 February 2016, date last accessed).

CDC. Emergency Preparedness and Response. Zika virus. 2016b. <<http://www.cdc.gov/zika/index.html>> (20 February 2016, date last accessed).

Chimelli L, Hahn MD, Netto MB, Ramos RG, Dias M, Gray F. Dengue: neuropathological findings in 5 fatal cases from Brazil. *Clin Neuropathol* 1990; 9: 157–62.

Cugola FR, Fernandes IR, Russo FB, Freitas BC, Dias JLM, Guimarães KP, et al. The Brazilian Zika virus strain causes birth defects in experimental models. *Nature* 2016; 534: 267–71.

de Fatima Vasco Aragao M, van der Linden V, Brainer-Lima AM, Coeli RR, Rocha MA, Sobral da Silva P, et al. Clinical features and neuroimaging (CT and MRI) findings in presumed Zika virus related congenital infection and microcephaly: retrospective case series study. *BMJ* 2016; 353: i1901.

de Paula Freitas B, de Oliveira Dias JR, Prazeres J, Sacramento GA, Ko AI, Maia M, et al. Ocular findings in infants with microcephaly associated with presumed Zika virus congenital infection in Salvador, Brazil. *JAMA Ophthalmol* 2016;134(5):529–535. 10.1001/jamaophthalmol.2016.0267

- Dick GW, Kitchen SF, Haddow AJ. Zika virus. I. Isolations and serological specificity. *Trans R Soc Trop Med Hyg* 1952; 46: 509–20.
- Driggers RW, Ho CY, Korhonen EM, Kuivaneen S, Jääskeläinen AJ, Smura T, et al. Zika virus infection with prolonged maternal viremia and fetal brain abnormalities. *N Eng J Med* 2016; 374: 2142–51.
- Duffy MR, Chen TH, Hancock WT, Powers AM, Kool JL, Lanciotti RS, et al. Zika virus outbreak on Yap Island, Federated States of Micronesia. *N Eng J Med* 2009; 360: 2536–43.
- E.C.D.C. Rapid risk assessment. Zika virus epidemic in the Americas: potential association with microcephaly and Guillain-Barré 2015. <http://ecdc.europa.eu/en/publications/Publications/zika-virus-americas-association-with-microcephaly-rapid-risk-assessment.pdf> (22 February 2016, date last accessed).
- Faria NR, Azevedo RdSdS, Kraemer MUG, Souza R, Cunha MS, Hill SC, et al. Zika virus in the Americas: early epidemiological and genetic findings. *Science* 2016; 352: 345–9.
- Fokke C, van den Berg B, Drenthen J, Walgaard C, van Doorn PA, Jacobs BC. Diagnosis of Guillain-Barre syndrome and validation of Brighton criteria. *Brain* 2014; 137 (Pt 1): 33–43.
- Garcez PP, Loiola EC, Madeiro da Costa R, Higa LM, Trindade P, Delvecchio R, et al. Zika virus impairs growth in human neurospheres and brain organoids. *Science* 2016; 352: 816–18.
- Hughes RA, Cornblath DR. Guillain-Barre syndrome. *Lancet* 2005; 366: 1653–66.
- Ios S, Mallet HP, Leparac Goffart I, Gauthier V, Cardoso T, Herida M. Current Zika virus epidemiology and recent epidemics. *Med Mal Infect* 2014; 44: 302–7.
- Julander JG, Winger QA, Rickords LF, Shi PY, Tilgner M, Binduga-Gajewska I, et al. West Nile virus infection of the placenta. *Virology* 2006; 347: 175–82.
- Li C, Xu D, Ye Q, Hong S, Jiang Y, Liu X, et al. Zika virus disrupts neural progenitor development and leads to microcephaly in mice. *Cell Stem Cell* 2016; 19: 1–7.
- Lucchese G, Kanduc D. Zika virus and autoimmunity: from microcephaly to Guillain-Barre syndrome, and beyond. *Autoimmun Rev* 2016. Advance Access published on March 25, 2016, doi: 10.1016/j.autrev.2016.03.020
- Macnamara FN. Zika virus: a report on three cases of human infection during an epidemic of jaundice in Nigeria. *Trans R Soc Trop Med Hyg* 1954; 48: 139–45.
- Martines RB, Bhatnagar J, Keating MK, Silva-Flannery L, Muehlenbachs A, Gary J, et al. Notes from the field: evidence of Zika virus infection in brain and placental tissues from two congenitally infected newborns and two fetal losses - Brazil, 2015. *MMWR Morb Mortal Wkly Rep* 2016; 65: 159–60.
- Mathur A, Arora KL, Chaturvedi UC. Transplacental Japanese encephalitis virus (JEV) infection in mice during consecutive pregnancies. *J Gen Virol* 1982; 59 (Pt 1): 213–17.
- Mecharles S, Herrmann C, Poullain P, Tran TH, Deschamps N, Mathon G, et al. Acute myelitis due to Zika virus infection. *Lancet* 2016; 387: 1481.
- Miner JJ, Cao B, Govero J, Smith AM, Fernandez E, Cabrera OH, et al. Zika virus infection during pregnancy in mice causes placental damage and fetal demise. *Cell* 2016; 165: 1081–91.
- Miner JJ, Diamond MS. Understanding how Zika virus enters and infects neural target cells. *Cell Stem Cell* 2016; 18: 559–60.
- Mlakar J, Korva M, Tul N, Popovic M, Poljsak-Prijatelj M, Mraz J, et al. Zika virus associated with microcephaly. *N Eng J Med* 2016; 374: 951–8.
- Musso D, Nhan T, Robin E, Roche C, Bierlaire D, Zisou K, et al. Potential for Zika virus transmission through blood transfusion demonstrated during an outbreak in French Polynesia, November 2013 to February 2014. *Euro Surveill* 2014; 19: pii=20761.
- Musso D, Roche C, Robin E, Nhan T, Teissier A, Cao-Lormeau VM. Potential sexual transmission of Zika virus. *Emerg Infect Dis* 2015; 21: 359–61.
- O'Leary DR, Kuhn S, Kniss KL, Hinckley AF, Rasmussen SA, Pape WJ, et al. Birth outcomes following West Nile Virus infection of pregnant women in the United States: 2003–2004. *Pediatrics* 2006; 117: e537–45.
- Oehler E, Fournier E, Leparac-Goffart I, Larre P, Cubizolle S, Sookharee C, et al. Increase in cases of Guillain-Barre syndrome during a Chikungunya outbreak, French Polynesia, 2014 to 2015. *Euro Surveill* 2015; 20: pii: 30079.
- Oehler E, Watrin L, Larre P, Leparac-Goffart I, Lastere S, Valour F, et al. Zika virus infection complicated by Guillain-Barre syndrome—case report, French Polynesia, December 2013. *Euro Surveill* 2014; 19: pii: 20720.
- Oliveira Melo AS, Malinger G, Ximenes R, Szejnfeld PO, Alves Sampaio S, Bispo de Filippis AM. Zika virus intrauterine infection causes fetal brain abnormality and microcephaly: tip of the iceberg? *Ultrasound Obstet Gynecol* 2016; 47: 6–7.
- Qian X, Nguyen HN, Song MM, Hadiono C, Ogden SC, Hammack C, et al. Brain-region-specific organoids using mini-bioreactors for modeling ZIKV exposure. *Cell* 2016; 165: 1238–54.
- Ramful D, Carbonnier M, Pasquet M, Bouhmani B, Ghazouani J, Noormahomed T, et al. Mother-to-child transmission of Chikungunya virus infection. *Pediatr Infect Dis J* 2007; 26: 811–15.
- Ribeiro LS, Marques RE, Jesus AM, Almeida RP, Teixeira MM. Zika crisis in Brazil: challenges in research and development. *Curr Opin Virol* 2016; 18: 76–81.
- Santé Ddl. Surveillance de la dengue et du zika en Polynésie Française 2014. <<http://www.hygiene-publique.gov.pf/spip.php?article120>> (22 February 2016, date last accessed).
- Schuler-Faccini L, Ribeiro EM, Feitosa IM, Horovitz DD, Cavalcanti DP, Pessoa A, et al. Possible association between Zika virus infection and microcephaly - Brazil, 2015. *Morb Mortal Wkly Rep* 2016; 65: 59–62.
- Sharma CM, Kumawat BL, Ralot T, Tripathi G, Dixit S. Guillain-Barre syndrome occurring during dengue fever. *J Indian Med Assoc* 2011; 109: 675, 682.
- Solomon T, Dung NM, Vaughn DW, Kneen R, Thao LT, Raengsakulrach B, et al. Neurological manifestations of dengue infection. *Lancet* 2000; 355: 1053–9.
- Tang H, Hammack C, Ogden SC, Wen Z, Qian X, Li Y, et al. Zika virus infects human cortical neural progenitors and attenuates their growth. *Cell Stem Cell* 2016; 18: 587–90. pii: S1934-5909(16)00106-5. 10.1016/j.stem.2016.02.016.
- Ventura CV, Maia M, Ventura BV, Linden VV, Araujo EB, Ramos RC, et al. Ophthalmological findings in infants with microcephaly and presumable intra-uterus Zika virus infection. *Arq Bras Oftalmol* 2016; 79: 1–3.
- Vieira MA, Aguiar Ade A, Borba Ade S, Guimaraes HC, Eulalio KD, de Albuquerque-Neto LL, et al. West Nile fever in Brazil: sporadic case, silent endemic disease or epidemic in its initial stages? *Rev Inst Med Trop Sao Paulo* 2015a; 57: 276.
- Vieira MA, Romano AP, Borba AS, Silva EV, Chiang JO, Eulalio KD, et al. West Nile virus encephalitis: the first human case recorded in Brazil. *Am J Trop Med Hyg* 2015b; 93: 377–9.
- WHO Emergencies preparedness, response. Guillain-Barré syndrome – Brazil. 2016a. <<http://www.who.int/csr/don/8-february-2016-gbs-brazil/en/>> (19 February 2016, date last accessed).
- WHO Emergencies preparedness, response. Guillain-Barré syndrome – Colombia and Venezuela. 2016b. <<http://www.who.int/csr/don/12-february-2016-gbs-colombia-venezuela/en/>> (19 February 2016, date last accessed).
- WHO WHO statement on the first meeting of the International Health Regulations (2005) (IHR 2005) emergency committee on Zika virus and observed increase in neurological disorders and neonatal malformations. 2016c. <<http://www.who.int/mediacentre/news/statements/2016/1st-emergency-committee-zika/en/>> (13 February 2016, date last accessed).
- WHO Zika situation report. Neurological syndrome and congenital abnormalities. 2016d. <<http://www.who.int/mediacentre/news/statements/2016/emergency-committee-zika-microcephaly/en/>> (13 February 2016, date last accessed)



- WHO Zika situation report. Zika and potential complications 2016. 2016e. <<http://www.who.int/emergencies/zika-virus/situation-report/12-february-2016/en/>> (23 February 2016, date last accessed)
- Wakerley BR, Yuki N. Infectious and noninfectious triggers in Guillain-Barre syndrome. *Expert Rev Clin Immunol* 2013; 9: 627–39.
- Wielanek AC, Monredon JD, Amrani ME, Roger JC, Serveaux JP. Guillain-Barre syndrome complicating a Chikungunya virus infection. *Neurology* 2007; 69: 2105–7.
- Willison HJ, Yuki N. Peripheral neuropathies and anti-glycolipid antibodies. *Brain* 2002; 125 (Pt 12): 2591–625.
- Wu KY, Zuo GL, Li XF, Ye Q, Deng YQ, Huang XY, et al. Vertical transmission of Zika virus targeting the radial glial cells affects cortex development of offspring mice. *Cell Res* 2016; 26: 645–54. 10.1038/cr.2016.58.